



PATIENT PRESENTING CLINICAL SIGNS

Buttercup Krumholz History: Buttercup presented for urinary Incontinence noted this about 5 months.

SPECIES RADIOGRAPHIC STUDY OF THE ABDOMEN

Canine The left femur reveals residuals of a healed mal-union fracture.

Liver presents as expected and is well defined. The spleen appears enlarged with rounded margins but again is well-defined.

BREED

Hound Mix Stomach and intestine are unremarkable, predominantly empty with some fluid/gas filling of stomach and small intestine. Large intestine shows some radiopaque ingesta and is normal.

SEX

Spayed Female Both kidneys are well visualized and considered to be normal. Distention of the renal pelvis and/or the ureters is not recognized. There is bilateral and regular excretion of contrast noted.

No signs of abdominal or retroperitoneal effusion.

AGE

3 Years Urinary bladder is moderately filled, no evidence of radiopaque cystic calculi.

The early and late contrast study reveals contrast medium passing the level of the sphincter and prominent filling of the urethra.

INTERPRETED BY

Sebastian Jawinski,
German Board
Certified Vet Specialist
in Diagnostic Imaging

RADIOGRAPHIC DIAGNOSIS

- Abnormal contrast filling of the urethra
- Residuals of a healed mal-union fracture left femur

HOSPITAL NAME

Animal Surgical
Center

INTERPRETATION OF THE FINDINGS & FURTHER RECOMMENDATIONS

Early contrast study images reveal contrast medium passing the level of the sphincter and prominent filling of the urethra which reflects the reported incontinence.

REFERRING VET

Smithtown Village AH

The bladder itself has a rounded shape I therefore assume that the bladder tone is intact. Neurologic disorders however still are a differential diagnosis, especially after trauma, but I would rule out urine retention.

INVOICE

13095

Ectopic ureters usually cause permanent incontinence starting with the age of a puppy. They commonly go along with a unilateral distended ureter and/or renal pelvis which are not recognized in this study. An ectopic ureter terminating in the urethra still is a potential differential.

DATE

9/14/21

There are other causes like storage dysfunction of the urinary bladder, urethral disorders and anatomic variants possible.



PATIENT I would recommend a complementary abdominal ultrasound and/or endoscopic vaginoscopy/cystoscopy.

Buttercup Krumholz

SPECIES

Canine

BREED

Hound Mix

SEX

Spayed Female

AGE

3 Years

INTERPRETED BY

Sebastian Jawinski,
German Board
Certified Vet Specialist
in Diagnostic Imaging

HOSPITAL NAME

Animal Surgical
Center

REFERRING VET

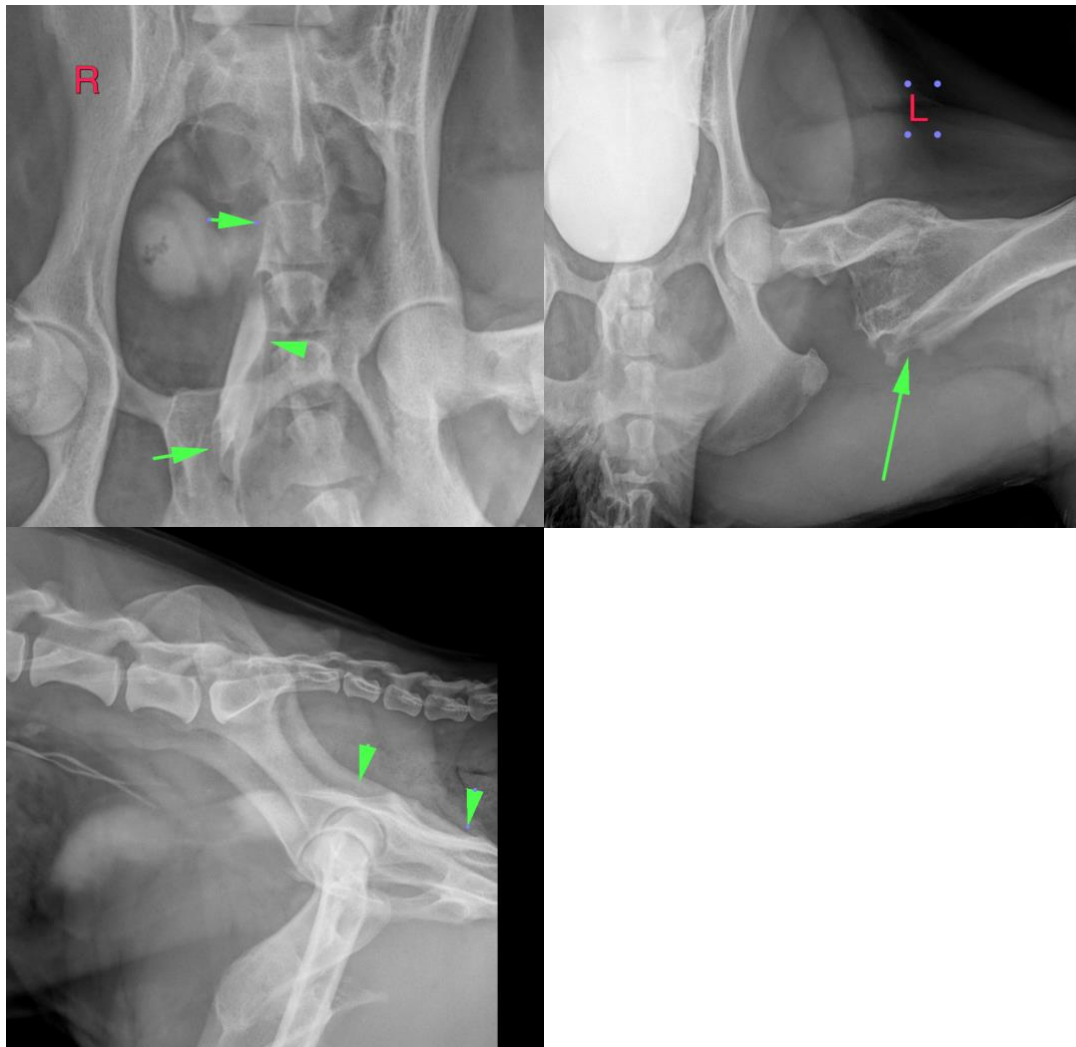
Smithtown Village AH

INVOICE

13095

DATE

9/14/21



The information and recommendations provided are based on the images presented by the referring veterinarian. No evaluation can be communicated regarding pathology that was not visible in the image/video clips provided.

Thank you for this referral. If the clinical or image interpretation does not parallel your findings or if I can be of any further assistance please contact me.

Sebastian Jawinski, German Board Certified Vet Specialist in Diagnostic Imaging
info@sonopath.com



PATIENT

Buttercup Krumholz

SPECIES

Canine

BREED

Hound Mix

SEX

Spayed Female

AGE

3 Years

INTERPRETED BY

Sebastian Jawinski,
German Board
Certified Vet Specialist
in Diagnostic Imaging

HOSPITAL NAME

Animal Surgical
Center

REFERRING VET

Smithtown Village AH

INVOICE

13095

DATE

9/14/21