



PATIENT

Tom Turner Jure

PRESENTING CLINICAL SIGNS

Late last week became lethargic and started vomiting Concern re: diabetes due to hyperglycemia 1 dose of insulin given, none needed after that Came home on Sunday Monday lethargic Tuesday very lethargic, limbs weak Had episode of seizure -Coudn't get up, unable to use RF leg, eyes dilated, no hypersalivation, no urination, defecation -lasted 20 minutes -breathing very heavily Diagnosed with HCM Jan 2021, most recent recheck July 2021 Hypertrophic cardiomyopathy (HCM) (less likely, age-related LV wall thickening) no secondary left atrial dilation previous left and current right ventricular outflow tract obstruction (both can be sources of murmur) Pancreatitis 2020

SPECIES

Feline

BREED

DLH

SEX

MN

Abnormal PE/Chem/CBC/UA Results: CBC: HCT 45.9, WBC 20.31 (N=2.87 17.02), LYM 10.98 (N=0.92 6.88), BASO 0.27 (N=0.01 0.26) Chem: GLU 19.81 (N=3.95 8.84), GGT 5 (N=0-4), CI 104 (N=112-129) FPLi: WNL UA: USG > 1.050, pH 7, trace protein, glucose 1000 mg/dL, WBC 2 /HPF, RBC 38 /HPF, otherwise quiet sediment Murmur ausculted: grade II/VI Cranial nerves: bilateral mydriasis, otherwise WNL Proprioception: normal Gait: truncal ataxia, will take a few steps and fall to the right

AGE

11 Years

MAGNETIC RESONANCE IMAGING OF THE HEAD / NECK

Pre/post contrast studies provided for review.

INTERPRETED BY

Sebastian Jawinski,
German Board
Certified Vet
Specialist in
Diagnostic Imaging

MAGNETIC RESONANCE IMAGING FINDINGS

Head:

2nd ventricles are symmetrical, there is no evidence of a mass effect. 3rd and 4th ventricles are inconspicuous. The subarachnoid space appears regular with deep gyri of the cerebrum and cerebellum and shows strong and even enhancement after contrast. All fluid sensitive sequences show no evidence of an edema. White and grey matter are seen with clear definition with age-related subtle narrowing of the latter. Pituitary gland is small and inconspicuous. Brain stem and the cerebellar-pontine angle are unremarkable. Signs of a dilated central canal are missing. There is no cerebellar herniation recognized.

HOSPITAL NAME

Animal Health
Partners

The displayed parts of the tympanic bullae and external ear canals are inconspicuous.

REFERRING VET

Dr. Marchal

Musculature of the head is bilaterally symmetrical and unremarkable.

INVOICE

47265

Cervical spine:

Images of the cervical spine are inconspicuous. There is no evidence of a compressive lesion/medullary edema/pathologic enhancement noted.

DATE

9-1-21



PATIENT

Tom Turner Jure

MAGNETIC RESONANCE IMAGING DIAGNOSIS

- Contrast enhancing meninges
- Deep cerebral and cerebellar gyri
- Normal findings of the cervical spine

SPECIES

Feline

INTERPRETATION OF THE FINDINGS & FURTHER RECOMMENDATIONS

The meningeal enhancement indicates an inflammatory process affecting the meninges throughout and could represent meningitis as a reactive-inflammatory issue. This enhancement is a questionable and non-specific MRI finding which could be triggered by an age-related/degenerative (diabetes) deepening of the gyri/mild brain atrophy, which I would favor. Sampling of the CSF could be performed next.

BREED

DLH

SEX

MN

AGE

11 Years

INTERPRETED BY

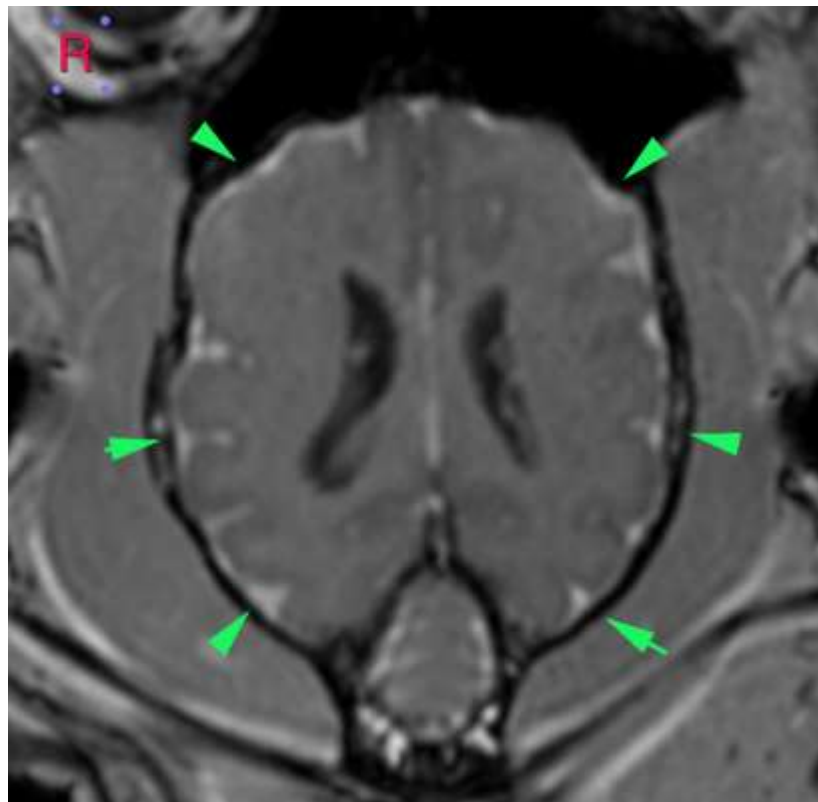
Sebastian Jawinski,
German Board
Certified Vet
Specialist in
Diagnostic Imaging

HOSPITAL NAME

Animal Health
Partners

REFERRING VET

Dr. Marchal

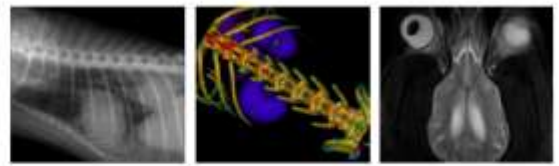


INVOICE

47265

DATE

9-1-21



PATIENT

Tom Turner Jure

The information and recommendations provided are based on the images presented by the referring veterinarian. No evaluation can be communicated regarding pathology that was not visible in the image/video clips provided.

SPECIES

Feline

Thank you for this referral. If the clinical or image interpretation does not parallel your findings or if I can be of any further assistance, please contact me.

Sebastian Jawinski, German Board Certified Vet Specialist in Diagnostic Imaging
Sebastian.Jawinski@sonopath.com

BREED

DLH

SEX

MN

AGE

11 Years

INTERPRETED BY

Sebastian Jawinski,
German Board
Certified Vet
Specialist in
Diagnostic Imaging

HOSPITAL NAME

Animal Health
Partners

REFERRING VET

Dr. Marchal

INVOICE

47265

DATE

9-1-21