



**PATIENT PRESENTING CLINICAL SIGNS**

Tank Brehmer History: owner reports mild cough for 1 year, today grade 1 murmur  
Abnormal PE/Chem/CBC/UA Results: Normal

**SPECIES RADIOGRAPHIC STUDY OF THE THORAX**

Canine The surrounding bony structures are within normal limits. The extra-thoracic soft tissues are homogenous without abnormalities.

**BREED** The cardiac silhouette is normal without evidence of chamber enlargement. The vertebral heart score equals 9.4.

Chihuahua

The pulmonary vessels are normal in size and taper appropriately in the periphery.

**SEX**

Neutered Male

The lung density appears normal throughout. There is no evidence of nodular or focal lesions recognized.

**AGE**

10 Years

The trachea shows dynamic, severe and long stretched collapse cranial to the thoracic inlet. Transverse diameter is reduced to approximately 90 % best seen in the left lateral projection. The carina and the bronchial tree are prominent but without relevant collapse in this respiratory phase.

The mediastinum presents expected soft tissue density, there is no evidence of tracheobronchial, cranial mediastinal or sternal lymphadenopathy. No mediastinal shift is seen.

**INTERPRETED BY**

Sebastian Jawinski,  
German Board  
Certified Vet Specialist  
in Diagnostic Imaging

The esophagus is not visible and considered to be normal. The diaphragm is unremarkable, no signs of pleural effusion.

**RADIOGRAPHIC DIAGNOSIS**

**HOSPITAL NAME**

Sylvan Lake VC

- Severe and long stretched tracheal collapse

**INTERPRETATION OF THE FINDINGS & FURTHER RECOMMENDATIONS**

**REFERRING VET**

Dr. Andrew Hodges

Radiographs do reflect the reported patient's history. I suspect a long stretched and at least moderate tracheal collapse. Grade needs to be confirmed with endoscopy. The latter could be used to get BAL for cytology and microbiologic testing. Involvement of the carina and the main stem bronchi cannot be ruled out since they are depending on the respiratory phase. Currently there is no secondary pneumonia recognized.

**INVOICE**

12937

**DATE**

9/1/21



**PATIENT**

Tank Brehmer

**SPECIES**

Canine

**BREED**

Chihuahua

**SEX**

Neutered Male

**AGE**

10 Years

**INTERPRETED BY**

Sebastian Jawinski,  
German Board  
Certified Vet Specialist  
in Diagnostic Imaging

**HOSPITAL NAME**

Sylvan Lake VC

**REFERRING VET**

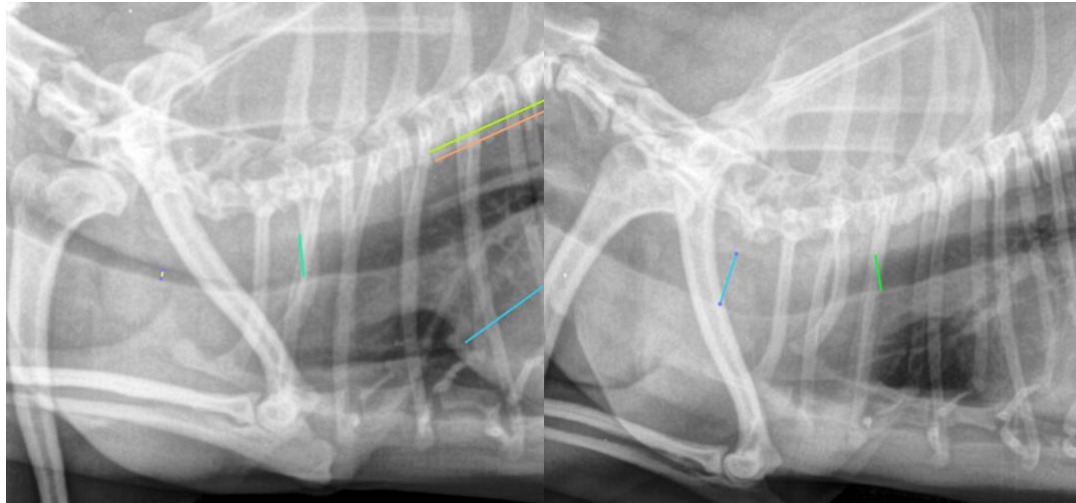
Dr. Andrew Hodges

**INVOICE**

12937

**DATE**

9/1/21



**The information and recommendations provided are based on the images presented by the referring veterinarian. No evaluation can be communicated regarding pathology that was not visible in the image/video clips provided.**

Thank you for this referral. If the clinical or image interpretation does not parallel your findings or if I can be of any further assistance please contact me.

**Sebastian Jawinski**, German Board Certified Vet Specialist in Diagnostic Imaging  
info@sonopath.com