



PATIENT

Rocky Fuchs

PRESENTING CLINICAL SIGNS

Patient presented for acutely down in the right rear leg, dragging right pelvic limb with absent CP

SPECIES

Canine

Spine:

The presented spine shows a harmonic course with inconspicuous vertebral bodies. The thoracolumbar transition presents a markedly narrowed intervertebral disc space at Th13/L1 with severe degenerative changes seen as formation of ventral spondylosis. The end plates of both vertebral bodies appear mild irregular, the correspondent facet joint is inconspicuous.

BREED

Miniature Schnauzer

There are no signs of a lytic or sclerotic process. There is no evidence of a fracture or subluxation. Relevant calcification of the nuclei is not recognized.

SEX

MN

Pelvis/coxofemoral joints:

The bony structures of the pelvis and the sacroiliac joints are unremarkable. There is no evidence of a lytic process noted. Coxofemoral joints are inconspicuous. Musculature of the thighs is symmetric and unremarkable.

AGE

9 Years

INTERPRETED BY

Sebastian Jawinski,
German Board
Certified Vet
Specialist in
Diagnostic Imaging

Stifles:

Both stifles present regular findings without relevant formation of osteophytes. Bony structures are unremarkable without signs of a lytic or sclerotic process. Intraarticular fat body is inconspicuous, there is no evidence of a relevant joint effusion. No evidence of a fracture and/or sub-/luxation is recognized. Sesamoid bones are bilaterally unremarkable. Periarticular soft tissues look normal.

HOSPITAL NAME

Boca Park Animal
Hospital

RADIOGRAPHIC DIAGNOSIS

- Narrowed intervertebral disc space Th13/L1 with marked degenerative changes (ventral spondylosis, irregular outline of the end plates)
- Normal findings of the coxofemoral joints and stifles

REFERRING VET

Dr. Corinna Gorgon

INTERPRETATION OF THE FINDINGS & FURTHER RECOMMENDATIONS

The narrowed disc space at Th13/L1 is an indirect sign for discopathy since a collapse of the intervertebral space indicates disc protrusion/herniation. However, ventral spondylosis and the mildly irregular end plates speak for a more chronic process and could represent residuals of a discospondylitis. Tomography could be the next diagnostic step.

INVOICE

47296

DATE

9-1-21

Lesions of muscles/tendons or inflammatory changes of soft tissues cannot be fully excluded as well as lateral compressive lesions of the spinal cord. Neoplasia is not suspected. Hip joints and stifles are inconspicuous.



PATIENT

Rocky Fuchs

SPECIES

Canine

BREED

Miniature Schnauzer

SEX

MN

AGE

9 Years

INTERPRETED BY

Sebastian Jawinski,
German Board
Certified Vet
Specialist in
Diagnostic Imaging

HOSPITAL NAME

Boca Park Animal
Hospital

REFERRING VET

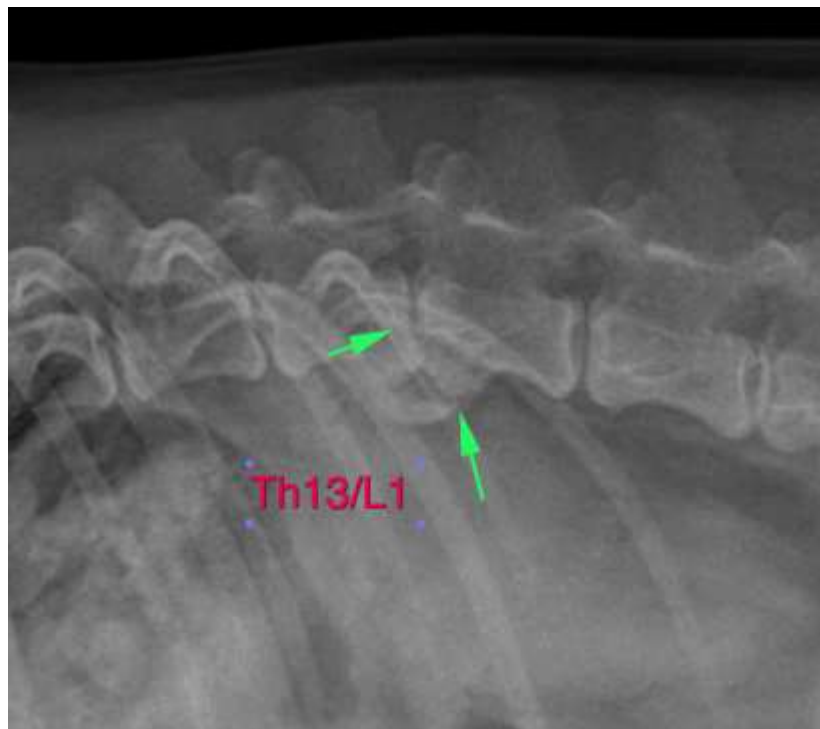
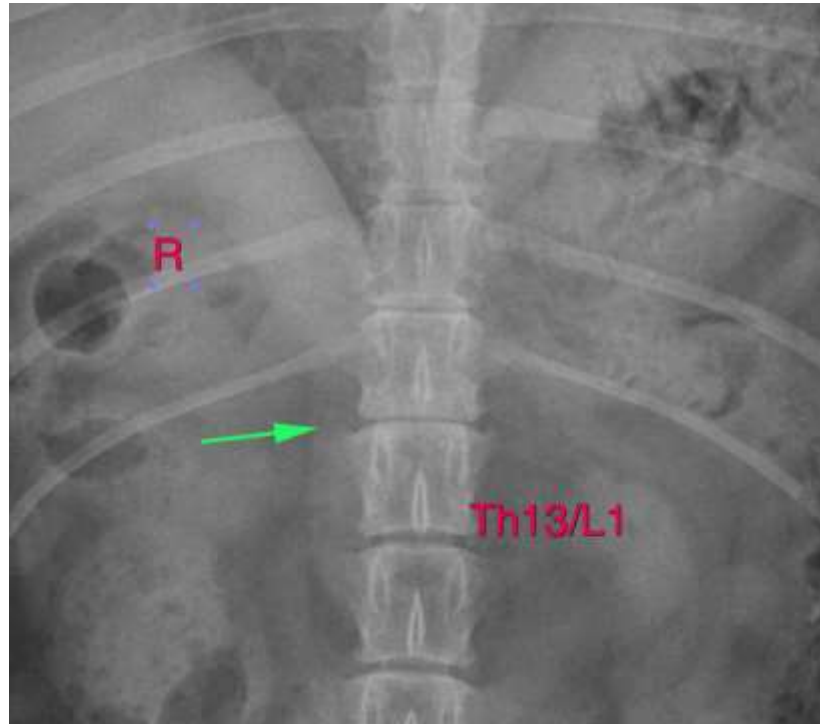
Dr. Corinna Gorgon

INVOICE

47296

DATE

9-1-21





PATIENT

Rocky Fuchs

SPECIES

Canine

The information and recommendations provided are based on the images presented by the referring veterinarian. No evaluation can be communicated regarding pathology that was not visible in the image/video clips provided.

BREED

Thank you for this referral. If the clinical or image interpretation does not parallel your findings or if I can be of any further assistance, please contact me.

Miniature Schnauzer

Sebastian Jawinski, German Board Certified Vet Specialist in Diagnostic Imaging
Sebastian.Jawinski@sonopath.com

SEX

MN

AGE

9 Years

INTERPRETED BY

Sebastian Jawinski,
German Board
Certified Vet
Specialist in
Diagnostic Imaging

HOSPITAL NAME

Boca Park Animal
Hospital

REFERRING VET

Dr. Corinna Gorgon

INVOICE

47296

DATE

9-1-21