



PATIENT PRESENTING CLINICAL SIGNS

Po Sussmann History: Intermittent episodes of ataxia
Abnormal PE/Chem/CBC/UA Results: Elevated Calcium value on recent bloodwork

SPECIES COMPUTED TOMOGRAPHIC STUDY OF THE HEAD

Feline The interhemispheric gap is in the midline with no evidence of a mass effect. As far as can be assessed, there are regular cortical gyri in the cerebral and cerebellar region with a symmetrical ventricular system. Brain stem and cerebellum are inconspicuous. Pituitary gland is within normal limits.

BREED

DSH Bony structures of skull and the skull foramina of the cranial nerves are laterally symmetrical and inconspicuous. Both tympanic bullae are completely ventilated with a regular tympanic bulla wall. External ear canals are ventilated in all sections, walls of the external ear canals, the adjacent temporomandibular joints and the nasopharyngeal meatus have no particular findings.

SEX

Neutered Male Frontal sinuses and the orbital contents are laterally symmetrical without evidence of a retrobulbar lesion. Nasal cavities are ventilated regularly.

AGE

7 Years

Post contrast images show no pathological enhancement. Soft tissues of the head and neck are symmetrical and of homogeneous density, especially the medial retropharyngeal lymph nodes.

COMPUTED TOMOGRAPHIC DIAGNOSIS

INTERPRETED BY

- Normal CT findings of the head

Sebastian Jawinski,
German Board
Certified Vet Specialist
in Diagnostic Imaging

INTERPRETATION OF THE FINDINGS & FURTHER RECOMMENDATIONS

CT findings show no signs of a neoplastic or an inflammatory process. Intra-axial lesions such as infarcts, small edema or low-grade neoplasia are difficult to recognize in CT and therefore not ruled out completely.

HOSPITAL NAME

Stone Cottage VH

REFERRING VET

Dr. Spaccarelli

INVOICE

12910

DATE

9/1/21



PATIENT

Po Sussmann

SPECIES

Feline

BREED

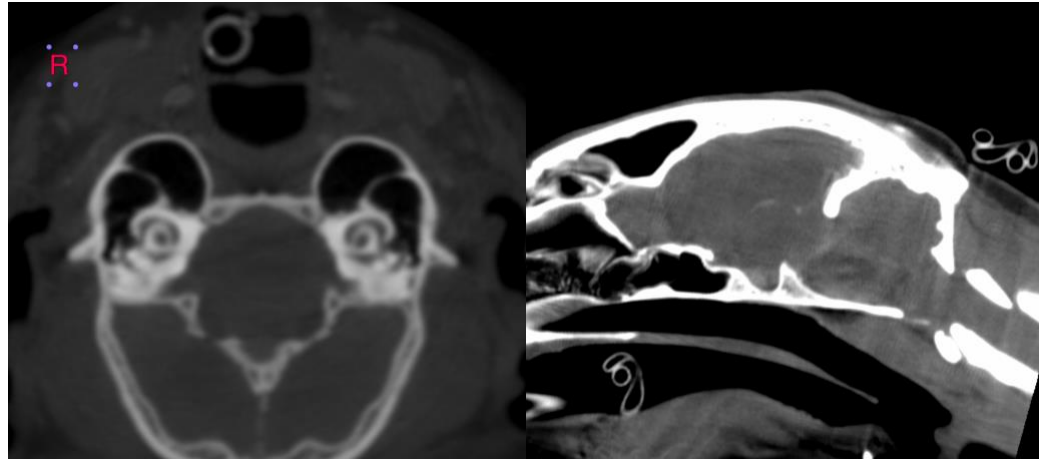
DSH

SEX

Neutered Male

AGE

7 Years



The information and recommendations provided are based on the images presented by the referring veterinarian. No evaluation can be communicated regarding pathology that was not visible in the image/video clips provided.

Thank you for this referral. If the clinical or image interpretation does not parallel your findings or if I can be of any further assistance please contact me.

Sebastian Jawinski, German Board Certified Vet Specialist in Diagnostic Imaging
info@sonopath.com

INTERPRETED BY

Sebastian Jawinski,
German Board
Certified Vet Specialist
in Diagnostic Imaging

HOSPITAL NAME

Stone Cottage VH

REFERRING VET

Dr. Spaccarelli

INVOICE

12910

DATE

9/1/21