

**PATIENT**

Penny Bowersox

**PRESENTING CLINICAL SIGNS**

spayed after her 1st heat cycle with no previous abnormalities. Approximately 4 months after spay began to become incontinent. Initially responsive to Proin but is now unresponsive. Abnormal PE/Chem/CBC/UA Results: Urinalysis, culture, and blood work were WNL

**SPECIES**

Canine

**COMPUTED TOMOGRAPHIC STUDY OF THE ABDOMEN**

Pre/post contrast studies provided for review.

**BREED**

Pitbull x

**COMPUTED TOMOGRAPHIC FINDINGS**

Unremarkable presentation of the bilaterally symmetrical kidneys is noted without signs of a pelvic dilation. Contrast phases show a regular excretion of contrast.

**SEX**

Female

The right ureter is inconspicuous and can be traced up to the trigone with regular inflow of urine.

The caudal section of the left ureter reveals marked distension with diameters of 7 mm which continues through the bladder wall at the level of the trigone and passes the cysto-urethral junction with accumulation of contrast in the course of the urethra, vestibulum and the vagina.

**AGE**

1 Year

Liver and spleen show normal findings in terms of size, surface, shape and contrast behavior. Gallbladder is inconspicuous without evidence of cholestasis. Pancreas presents normal size and shape with a smooth surface.

**INTERPRETED BY**

Sebastian Jawinski,  
German Board  
Certified Vet  
Specialist in  
Diagnostic Imaging

Adrenal glands are in normal limits.

As far as can be assessed, the stomach and all parts of intestine are regularly presented without any indication of a wall thickening or a mass.

**HOSPITAL NAME**

Mountain West  
Veterinary Hospital

**COMPUTED TOMOGRAPHIC DIAGNOSIS**

- Left ectopic transmural ureter

**REFERRING VET**

Andrew Burton

**INTERPRETATION OF THE FINDINGS & FURTHER RECOMMENDATIONS**

The CT findings are pathognomonic for a left sided ectopic ureter. Dilation of the left renal pelvis is currently not recognized.

**INVOICE**

47269

**DATE**

9-1-21



**PATIENT**

Penny Bowersox

**SPECIES**

Canine

**BREED**

Pitbull x

**SEX**

Female

**AGE**

1 Year

**INTERPRETED BY**

Sebastian Jawinski,  
German Board  
Certified Vet  
Specialist in  
Diagnostic Imaging

**HOSPITAL NAME**

Mountain West  
Veterinary Hospital

**REFERRING VET**

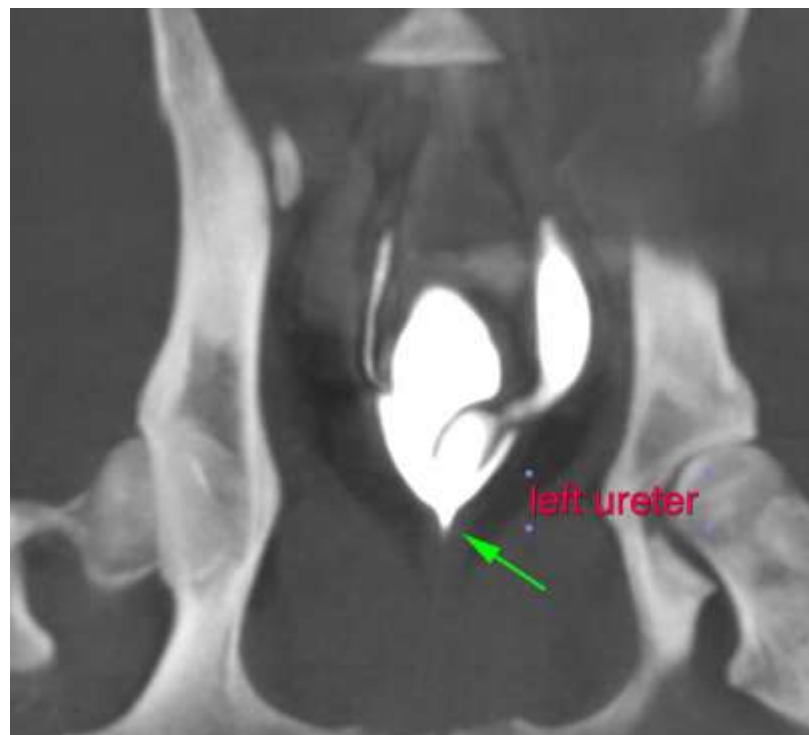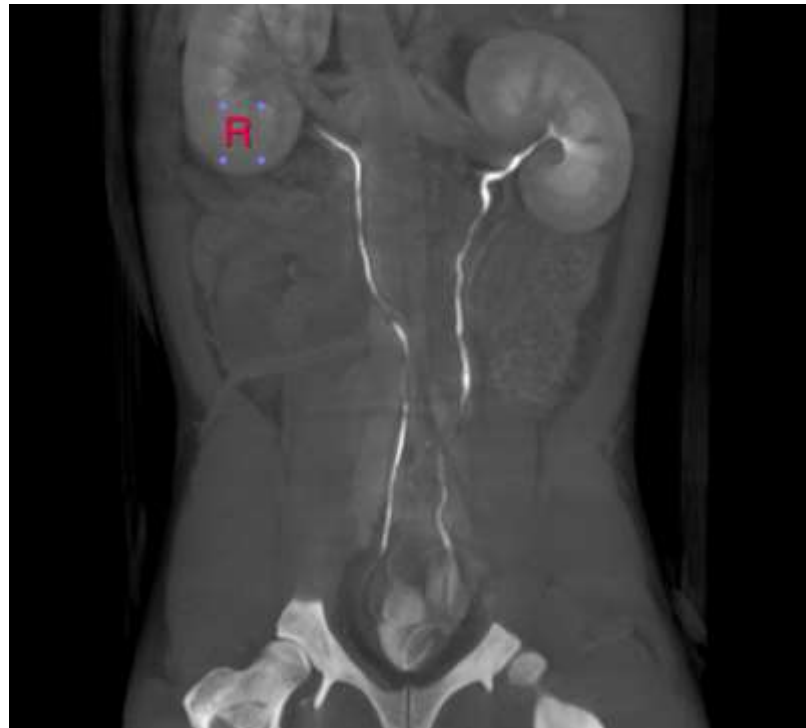Andrew Burton

**INVOICE**

47269

**DATE**

9-1-21





**PATIENT**

Penny Bowersox

**SPECIES**

Canine

**BREED**

Pitbull x

**SEX**

Female

**AGE**

1 Year

**INTERPRETED BY**

Sebastian Jawinski,  
German Board  
Certified Vet  
Specialist in  
Diagnostic Imaging

**HOSPITAL NAME**

Mountain West  
Veterinary Hospital

**REFERRING VET**

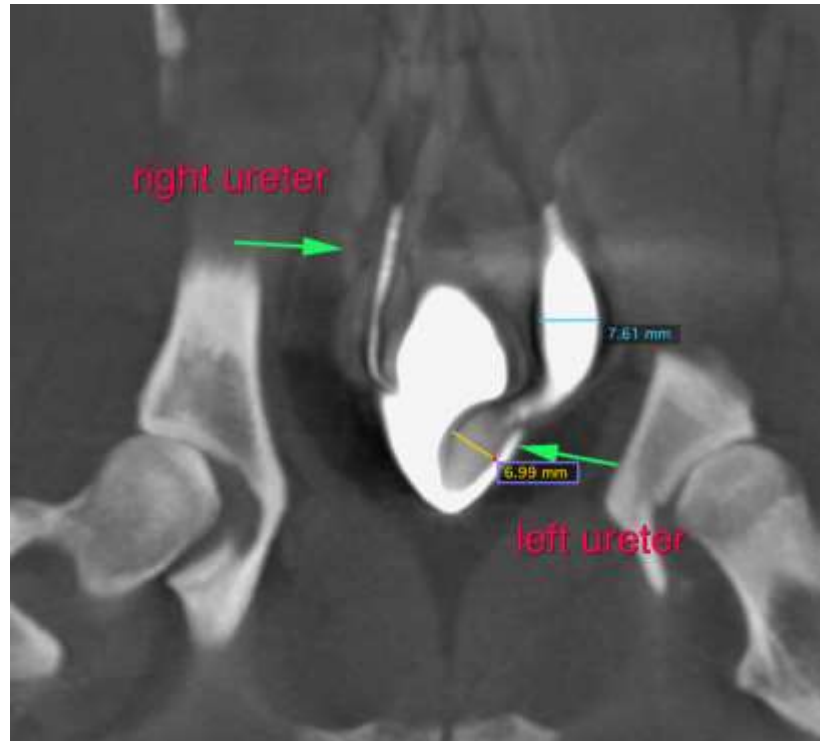
Andrew Burton

**INVOICE**

47269

**DATE**

9-1-21



The information and recommendations provided are based on the images presented by the referring veterinarian. No evaluation can be communicated regarding pathology that was not visible in the image/video clips provided.

Thank you for this referral. If the clinical or image interpretation does not parallel your findings or if I can be of any further assistance, please contact me.

**Sebastian Jawinski, German Board Certified Vet Specialist in Diagnostic Imaging**  
Sebastian.Jawinski@sonopath.com