



PATIENT	PRESENTING CLINICAL SIGNS
Mildred McCluskey	Presented to surgeon. Right ear canal ends blindly and left if narrow. Concern for congenital abnormality.
SPECIES	COMPUTED TOMOGRAPHIC STUDY OF THE HEAD
Canine	Pre/post contrast studies provided for review.
BREED	COMPUTED TOMOGRAPHIC FINDINGS
Golden Retriever	The right external canal ends in the transition from the vertical to the horizontal part. Adjacent to the tympanic membrane, which appears regular, a fluid-filled cavity is noted with a mildly enhancing wall showing a length of approximately 1.6 cm.
SEX	The left external ear canal is generally and mildly narrowed but appears regular. Both tympanic bullae are completely ventilated with a regular tympanic bulla wall. The neurocranium is inconspicuous.
Female Spayed	
AGE	Bony structures of skull and the skull foramina of the cranial nerves are laterally symmetrical and inconspicuous.
8 Months	
INTERPRETED BY	The temporomandibular joints and the nasopharyngeal meatus have no particular findings.
Sebastian Jawinski, German Board Certified Vet Specialist in Diagnostic Imaging	Frontal sinuses and the orbital contents are laterally symmetrical without evidence of a retrobulbar lesion.
HOSPITAL NAME	Soft tissues of the head and neck are symmetrical and of homogeneous density, especially the medial retropharyngeal lymph nodes.
Mobile Pet Imaging	COMPUTED TOMOGRAPHIC DIAGNOSIS
REFERRING VET	<ul style="list-style-type: none">Focal atresia of the right horizontal external ear canal
Meaux	INTERPRETATION OF THE FINDINGS & FURTHER RECOMMENDATIONS
INVOICE	CT findings likely represent a congenital disorder with focal atresia of the horizontal part of the external ear canal. The fluid filled cavity adjacent to the tympanic membrane shows a non-connected part. Mild inflammation/initial abscess formation is possible at this level. The tympanic membrane is intact.
47250	The left side is presented regularly without overt signs of inflammation.
DATE	
9-1-21	



PATIENT

Mildred McCluskey

SPECIES

Canine

BREED

Golden Retriever

SEX

Female Spayed

AGE

8 Months

INTERPRETED BY

Sebastian Jawinski,
German Board
Certified Vet
Specialist in
Diagnostic Imaging

HOSPITAL NAME

Mobile Pet Imaging

REFERRING VET

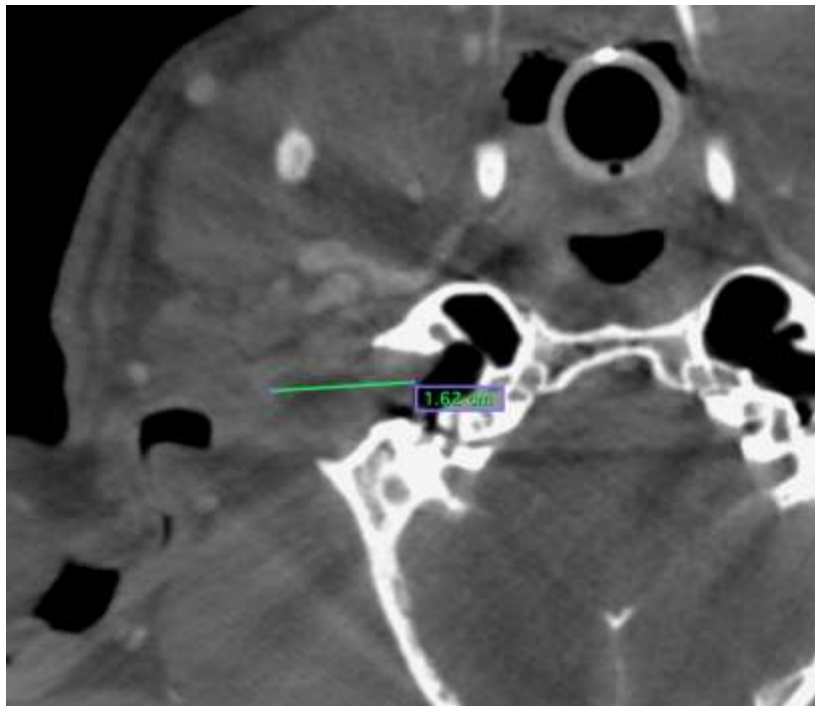
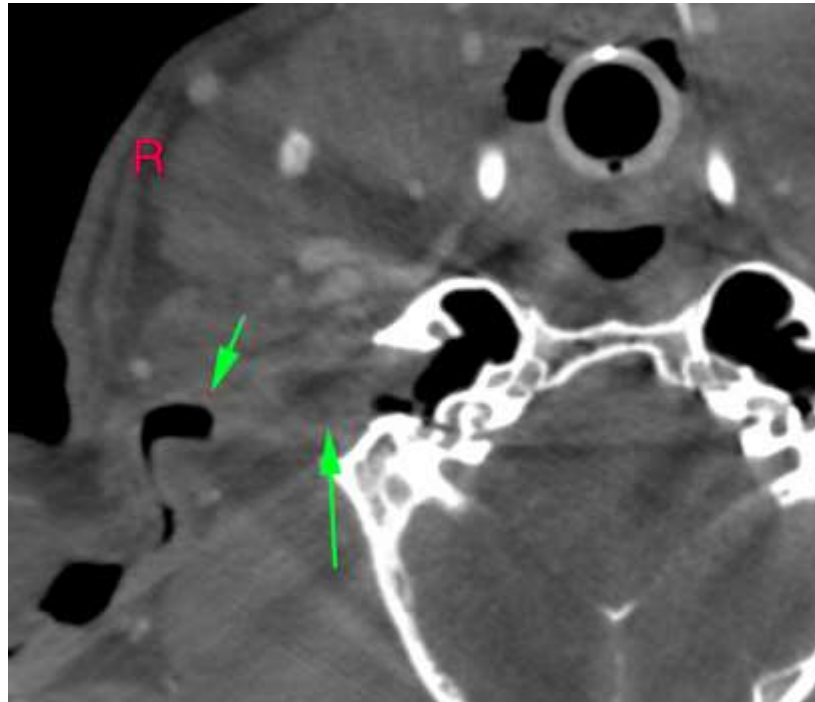
Meaux

INVOICE

47250

DATE

9-1-21





PATIENT

Mildred McCluskey

The information and recommendations provided are based on the images presented by the referring veterinarian. No evaluation can be communicated regarding pathology that was not visible in the image/video clips provided.

Thank you for this referral. If the clinical or image interpretation does not parallel your findings or if I can be of any further assistance, please contact me.

SPECIES

Canine

Sebastian Jawinski, German Board Certified Vet Specialist in Diagnostic Imaging
Sebastian.Jawinski@sonopath.com

BREED

Golden Retriever

SEX

Female Spayed

AGE

8 Months

INTERPRETED BY

Sebastian Jawinski,
German Board
Certified Vet
Specialist in
Diagnostic Imaging

HOSPITAL NAME

Mobile Pet Imaging

REFERRING VET

Meaux

INVOICE

47250

DATE

9-1-21