



PATIENT

Kobe Neadle

PRESENTING CLINICAL SIGNS

Hematuria noticed 4 days ago but nothing noticed since then and otherwise doing fine. NO PU/PD or stranguria noted and NO U accidents noted.

SPECIES

Canine

RADIOGRAPHIC STUDY OF THE ABDOMEN

Lateral and vd views provided for review.

BREED

Boston Terrier

RADIOGRAPHIC FINDINGS

All displayed bony structures are unremarkable without signs of a fracture, sub-/luxation and/or a lytic/sclerotic process. There is moderate and bilateral coxarthrosis noted.

SEX

Male Neutered

Liver and spleen present as expected and are well defined. M

Stomach and intestine are unremarkable, predominantly empty with some gas filling of stomach and small intestine. Large intestine shows some radiopaque ingesta.

AGE

7 Years, 9 Months

Both kidneys are normal with a length of 5.35 cm on the right and 5.72 cm on the left side. No signs of abdominal or retroperitoneal effusion.

INTERPRETED BY

Sebastian Jawinski,
German Board
Certified Vet
Specialist in
Diagnostic Imaging

Urinary bladder is moderately filled presenting multiple radiopaque cystic calculi with a maximum estimated diameter of 3.5 mm. Prostate appears normal. Urethra, intra- and post-pelvic soft tissues are as far as can be assessed inconspicuous without signs of radiopaque calculi especially in the course of the urethra passing the caudal flexure and penis.

RADIOGRAPHIC DIAGNOSIS

- Multiple cystic calculi

HOSPITAL NAME

Northvale Veterinary
Clinic

INTERPRETATION OF THE FINDINGS & FURTHER RECOMMENDATIONS

Radiographs present a moderately filled urinary bladder and is currently not suspicious for an obstructive lesion. Cystitis due to calculi is likely. The type of the calculi cannot be determined by radiographs. Spiculated calculi and Jackstone appearance could speak for struvite or silicate stones. However, the presented opacities may represent clusters of sediment as well. Urinary testing (sediment/culture) is recommended.

REFERRING VET

Dr. Simon

INVOICE

47298

DATE

9-1-21



PATIENT

Kobe Neadle

SPECIES

Canine

BREED

Boston Terrier

SEX

Male Neutered

AGE

7 Years, 9 Months

INTERPRETED BY

Sebastian Jawinski,
German Board
Certified Vet
Specialist in
Diagnostic Imaging

HOSPITAL NAME

Northvale Veterinary
Clinic

REFERRING VET

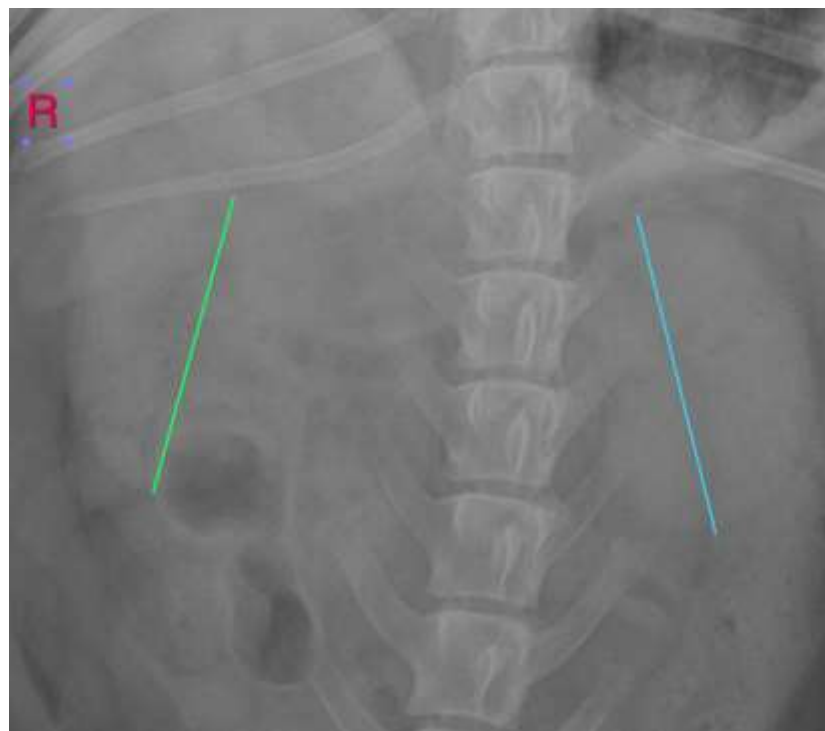
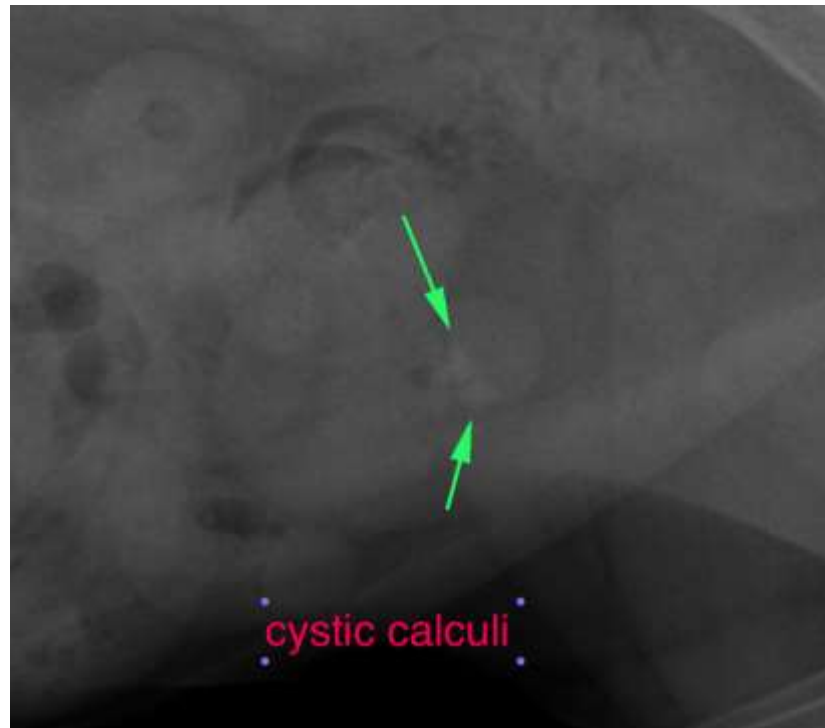
Dr. Simon

INVOICE

47298

DATE

9-1-21





PATIENT

Kobe Neadle

The information and recommendations provided are based on the images presented by the referring veterinarian. No evaluation can be communicated regarding pathology that was not visible in the image/video clips provided.

SPECIES

Canine

Thank you for this referral. If the clinical or image interpretation does not parallel your findings or if I can be of any further assistance, please contact me.

Sebastian Jawinski, German Board Certified Vet Specialist in Diagnostic Imaging
Sebastian.Jawinski@sonopath.com

BREED

Boston Terrier

SEX

Male Neutered

AGE

7 Years, 9 Months

INTERPRETED BY

Sebastian Jawinski,
German Board
Certified Vet
Specialist in
Diagnostic Imaging

HOSPITAL NAME

Northvale Veterinary
Clinic

REFERRING VET

Dr. Simon

INVOICE

47298

DATE

9-1-21