



PATIENT PRESENTING CLINICAL SIGNS

PATIENT Iggy Malone
HISTORY: Had a dental at another vet 1 month ago. Had a tumor removed from R cheek area around that time also. Now, the entire R side of his face is severely swollen and he is very painful on opening the mouth. Other than the severe periodontal disease (and retained tooth roots), is there anything else there that could be causing the swelling?

SPECIES

Canine **COMPUTED TOMOGRAPHIC STUDY OF THE HEAD**

BREED

Boxer

There is a marked brachycephalic breed-appropriate head formation noted with hyperostosis of the skull and bullae. The latter are inconspicuous. The neurocranium is inconspicuous as far as can be assessed.

SEX

Neutered Male

The right face/periorbital region presents prominent soft tissue swelling. Radiopaque foreign material is not detected. Fluid-filled areas are not obvious, orbital detail is reduced.

AGE

7 Years

107/108 show significant lysis of the alveolar bone. Dilated bony canals can be traced from the buccal roots of 108 and 109 into the subcutaneous region, and the palatal root of 109 and 110 into the orbit. The left maxillary teeth show similar findings with a residual caudal root of 206.

The nasopharyngeal meatus is inconspicuous. Both nasal cavities show a swelling of the mucous membranes more obvious on the left with mild pooling of fluid. Frontal sinuses are laterally symmetrical and inconspicuous.

INTERPRETED BY

Sebastian Jawinski,
 German Board
 Certified Vet Specialist
 in Diagnostic Imaging

The right mandibular lymph nodes are moderately enlarged and of homogeneous density, especially the medial retropharyngeal lymph nodes.

HOSPITAL NAME

Animal Health Care
 Denver

COMPUTED TOMOGRAPHIC DIAGNOSIS

- Prominent swelling of the right face/periorbital region
- Multiple teeth lesions (s. above)
- Moderate right mandibular lymphadenitis
- Unspecific signs of a bilateral rhinitis

INTERPRETATION OF THE FINDINGS & FURTHER RECOMMENDATIONS

REFERRING VET

Dr. Cathryn Sayer

CT findings of the right face and orbit represent likely an inflammatory process. A mature abscess is currently not recognized, and neoplasia is not obvious. Especially the buccal roots of 107/108 could cause the swelling.

INVOICE

12908

The swelling of the nasal mucous membranes is unspecific and likely secondary. Excision of the right and left maxillary teeth is recommended. Foreign body triggered phlegmon and initial abscess are potentially possible. Radiopaque foreign material is not detected but cannot be fully excluded.

DATE

9/1/21



PATIENT

Iggy Malone

SPECIES

Canine

BREED

Boxer

SEX

Neutered Male

AGE

7 Years

INTERPRETED BY

Sebastian Jawinski,
German Board
Certified Vet Specialist
in Diagnostic Imaging

HOSPITAL NAME

Animal Health Care
Denver

REFERRING VET

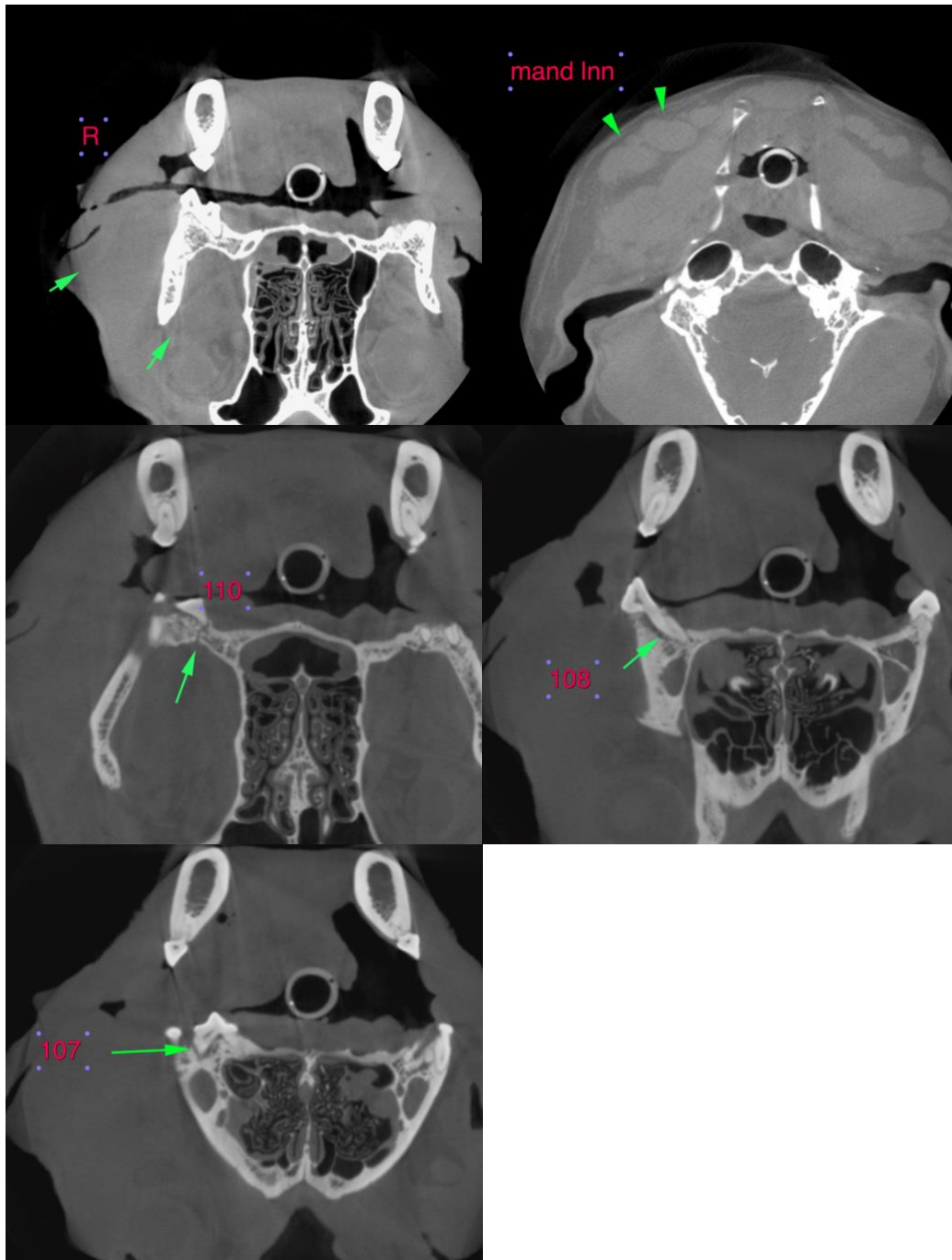
Dr. Cathryn Sayer

INVOICE

12908

DATE

9/1/21



The information and recommendations provided are based on the images presented by the referring veterinarian. No evaluation can be communicated regarding pathology that was not visible in the image/video clips provided.



PATIENT

Iggy Malone

Thank you for this referral. If the clinical or image interpretation does not parallel your findings or if I can be of any further assistance please contact me.

SPECIES

Canine

Sebastian Jawinski, German Board Certified Vet Specialist in Diagnostic Imaging
info@sonopath.com

BREED

Boxer

SEX

Neutered Male

AGE

7 Years

INTERPRETED BY

Sebastian Jawinski,
German Board
Certified Vet Specialist
in Diagnostic Imaging

HOSPITAL NAME

Animal Health Care
Denver

REFERRING VET

Dr. Cathryn Sayer

INVOICE

12908

DATE

9/1/21