

**PATIENT**

Gigi Rubinetti

PRESENTING CLINICAL SIGNS

1yr history of coughing. Was going to Denville AH for issue. Not improving with Depomedrol. Rads on 7/30/21 show chronic airway dz with involvement of left caudal lung lobe. Losing weight, on and off not eating.

SPECIES

Feline

COMPUTED TOMOGRAPHIC FINDINGS**Thorax****BREED**

DSH

The right and left caudal lobe present each significant emphysema with highly distended bronchi and nodular-like areas. Emphysematous changes are worse on the right. The medial and dorsal part of the left caudal lobe shows a rounded soft tissue opacity of 1.4 cm. The perihilar region is inconspicuous as far as can be assessed. There are multiple pleural lines detected.

SEX

FS

Mediastinum is regular in width and density. Mediastinal (sternal, tracheal-, bronchial) lymph nodes are considered as normal. Thoracic trachea and esophagus present as expected.

Diaphragm is normal.

AGE

12

The extra-thoracic soft tissues, thoracic spine as well as ribs and sternum are unremarkable. There is no evidence of bony lysis or abnormal sclerosis.

INTERPRETED BY

Sebastian Jawinski,
German Board
Certified Vet
Specialist in
Diagnostic Imaging

COMPUTED TOMOGRAPHIC DIAGNOSIS

- Severe lung emphysema right and left caudal lobes
- Questionable soft tissue nodule medial/dorsal left caudal lobe

INTERPRETATION OF THE FINDINGS & FURTHER RECOMMENDATIONS

CT findings are severe especially on the right showing severe bronchiectasis with large cavitory areas. Initial perihilar air trapping due to obstruction/stenosis of the supplying bronchi is likely. Chronic issues such feline asthma with chronic bronchitis/bronchopneumonia are potential differentials. The soft tissue nodule on the left may represent pulmonary atelectasis. However, neoplasia such as bronchial carcinoma cannot be fully excluded. The current CT does not show overt evidence of metastatic spread. Endoscopic BAL/cytology/microbiological testing may be beneficial, but I assume there is no curative treatment possible, and findings have a bad prognosis.

HOSPITAL NAME

American Animal
Hospital

REFERRING VET

Dr. Vogel

INVOICE

47251

DATE

9-1-21



PATIENT

Gigi Rubinetti

SPECIES

Feline

BREED

DSH

SEX

FS

AGE

12

INTERPRETED BY

Sebastian Jawinski,
German Board
Certified Vet
Specialist in
Diagnostic Imaging

HOSPITAL NAME

American Animal
Hospital

REFERRING VET

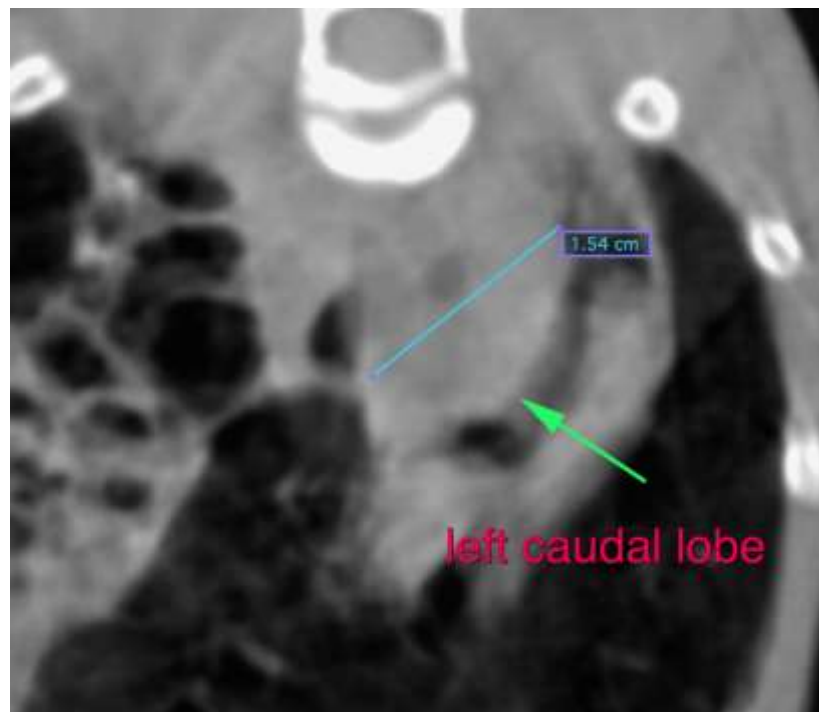
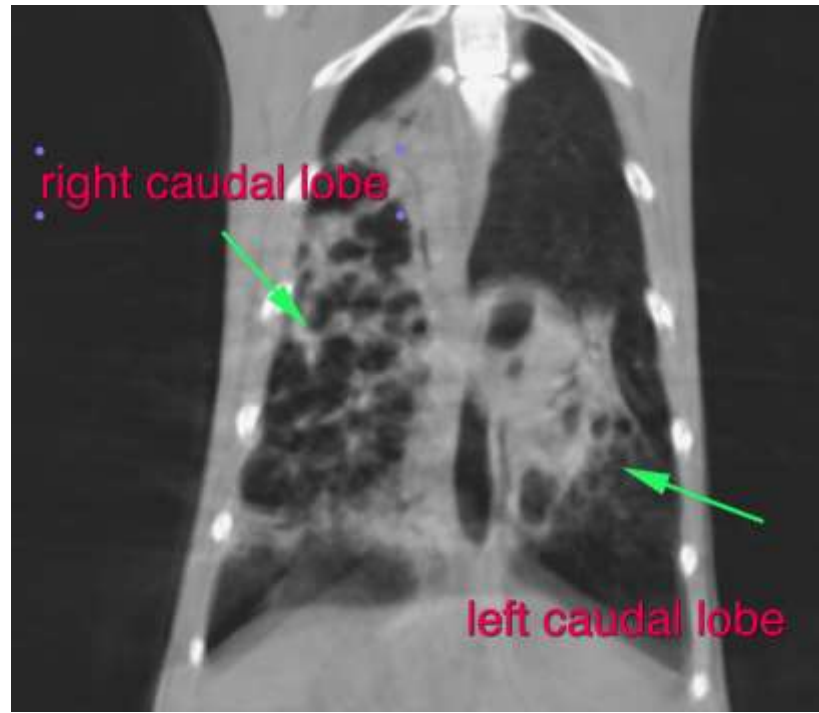
Dr. Vogel

INVOICE

47251

DATE

9-1-21





PATIENT

Gigi Rubinetti

The information and recommendations provided are based on the images presented by the referring veterinarian. No evaluation can be communicated regarding pathology that was not visible in the image/video clips provided.

Thank you for this referral. If the clinical or image interpretation does not parallel your findings or if I can be of any further assistance, please contact me.

SPECIES

Feline

Sebastian Jawinski, German Board Certified Vet Specialist in Diagnostic Imaging
Sebastian.Jawinski@sonopath.com

BREED

DSH

SEX

FS

AGE

12

INTERPRETED BY

Sebastian Jawinski,
German Board
Certified Vet
Specialist in
Diagnostic Imaging

HOSPITAL NAME

American Animal
Hospital

REFERRING VET

Dr. Vogel

INVOICE

47251

DATE

9-1-21