

**PATIENT**

Coco Itskovich

PRESENTING CLINICAL SIGNS

Patient presented for struggling to breathe, owner states started acutely this morning. Not currently on any medications. No heart murmur ausculted

SPECIES

Canine

RADIOGRAPHIC STUDY OF THE THORAX

Right/left lateral and vd views provided for review.

BREED

Yorkshire Terrier

RADIOGRAPHIC FINDINGS

The surrounding bony structures are within normal limits. The extra-thoracic soft tissues are homogenous without abnormalities.

SEX

FS

There is no evidence of cardiovascular disease.

The lung density appears normal throughout. There is no evidence of nodular or focal lesions recognized.

AGE

12 Years

The trachea shows severe, partially complete and long stretched collapse cranial and caudal to the thoracic inlet. The carina and the bronchial tree are recognized without relevant collapse in this respiratory phase.

INTERPRETED BY

Sebastian Jawinski,
German Board
Certified Vet
Specialist in
Diagnostic Imaging

The mediastinum presents expected soft tissue density, there is no evidence of tracheobronchial, cranial mediastinal or sternal lymphadenopathy. No mediastinal shift is seen. The esophagus is not visible and considered to be normal. The diaphragm is unremarkable, no signs of pleural effusion.

RADIOGRAPHIC DIAGNOSIS

- Severe/complete dynamic tracheal collapse

HOSPITAL NAME

Boca Park Animal
Hospital

INTERPRETATION OF THE FINDINGS & FURTHER RECOMMENDATIONS

Radiographs do reflect the reported patient's history. I suspect a long stretched and severe dynamic tracheal collapse. Grade needs to be confirmed with endoscopy. The latter could be used to get BAL for cytology and microbiologic testing. Involvement of the carina and the main stem bronchi cannot be ruled out since they are depending on the respiratory phase. Currently there is no secondary pneumonia recognized.

REFERRING VET

Dr. Corinna Gorgon

INVOICE

47341

DATE

9-1-21



PATIENT

Coco Itskovich

SPECIES

Canine

BREED

Yorkshire Terrier

SEX

FS

AGE

12 Years

INTERPRETED BY

Sebastian Jawinski,
German Board
Certified Vet
Specialist in
Diagnostic Imaging

HOSPITAL NAME

Boca Park Animal
Hospital

REFERRING VET

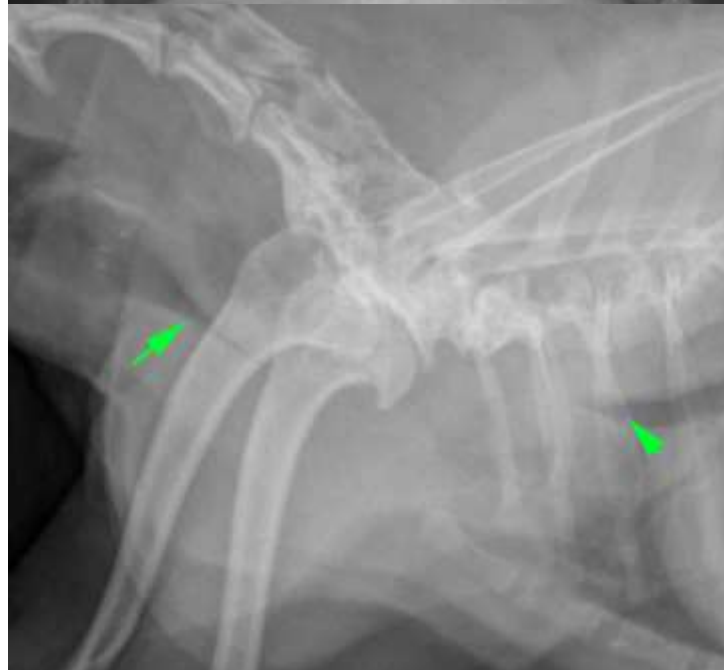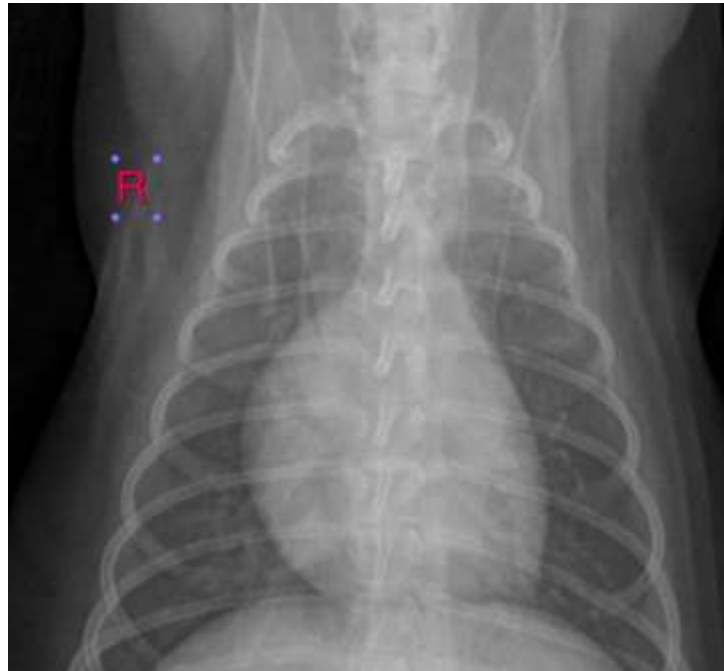
Dr. Corinna Gorgon

INVOICE

47341

DATE

9-1-21





PATIENT

Coco Itskovich

SPECIES

Canine

BREED

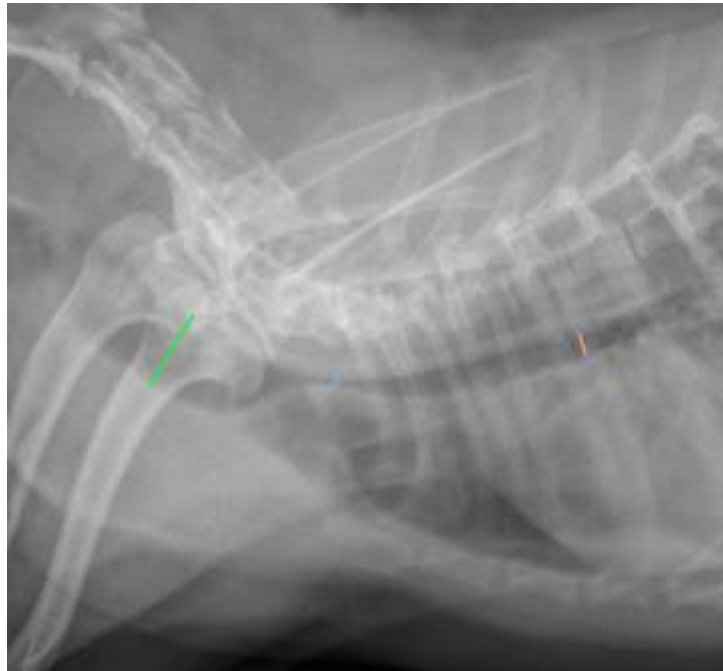
Yorkshire Terrier

SEX

FS

AGE

12 Years



INTERPRETED BY

Sebastian Jawinski,
German Board
Certified Vet
Specialist in
Diagnostic Imaging

HOSPITAL NAME

Boca Park Animal
Hospital

REFERRING VET

Dr. Corinna Gorgon

INVOICE

47341

DATE

9-1-21

The information and recommendations provided are based on the images presented by the referring veterinarian. No evaluation can be communicated regarding pathology that was not visible in the image/video clips provided.

Thank you for this referral. If the clinical or image interpretation does not parallel your findings or if I can be of any further assistance, please contact me.

Sebastian Jawinski, German Board Certified Vet Specialist in Diagnostic Imaging
Sebastian.Jawinski@sonopath.com