

**PATIENT**

Silvie Golden
Retriever Freedom
Rescue

PRESENTING CLINICAL SIGNS

Rescue dog, recently required. Ears are so stentotic that an otoscope cannot be inserted.
Abnormal PE/Chem/CBC/UA Results: NSF

SPECIES

Canine

Head

The neurocranium shows normal findings. Bony structures of skull and the skull foramina of the cranial nerves are laterally symmetrical and inconspicuous.

BREED

Golden Retriever

The right tympanic bulla is ventilated with a regular tympanic bulla wall. The right external ear canal is completely obliterated with residual gas pockets and presents a markedly thickened and irregular wall with multiple metaplastic calcifications. All sections are involved. The tympanic membrane appears intact.

SEX

FS

The left bulla reveals a small amount of fluid but is predominantly ventilated. Bulla wall is inconspicuous. Changes of the external ear canal are similar to the right but less obvious. The horizontal and vertical section of the canal are ventilated, integrity of the tympanic membrane is questionable since there is a prominent inwards protrusion recognized.

AGE

8 Years

The adjacent temporomandibular joints and the nasopharyngeal meatus have no particular findings.

INTERPRETED BY

Sebastian Jawinski,
German Board
Certified Vet
Specialist in
Diagnostic Imaging

Frontal sinuses and the orbital contents are laterally symmetrical without evidence of a retrobulbar lesion. Nasal cavities are ventilated regularly. Conches look normal as well as the maxillary/mandibular teeth.

Soft tissues of the head and neck are symmetrical and of homogeneous density, especially the medial retropharyngeal lymph nodes.

HOSPITAL NAME

Animal Health Care
Denver

COMPUTED TOMOGRAPHIC DIAGNOSIS

- Severe, chronic and active otitis externa right
- Moderate, chronic otitis externa left
- Signs of a mild otitis media left

REFERRING VET

Cathryn Sayer

INTERPRETATION OF THE FINDINGS & FURTHER RECOMMENDATIONS**INVOICE**

47219

CT findings show severe and chronic inflammatory changes of both external ear canals, especially on the right side. An aggressive lesion and/or neoplasia are not suspected as far as can be assessed. Presence of polyps is possible. Biopsy and/or contrast CT are needed for further evaluation.

DATE

8-31-21



PATIENT

Silvie Golden
Retriever Freedom
Rescue

The subtle filling of the left bulla may be due to involvement/rupture of the tympanic membrane.
Nasopharyngeal polyps are not recognized.

SPECIES

Canine

BREED

Golden Retriever

SEX

FS

AGE

8 Years

INTERPRETED BY

Sebastian Jawinski,
German Board
Certified Vet
Specialist in
Diagnostic Imaging

HOSPITAL NAME

Animal Health Care
Denver

REFERRING VET

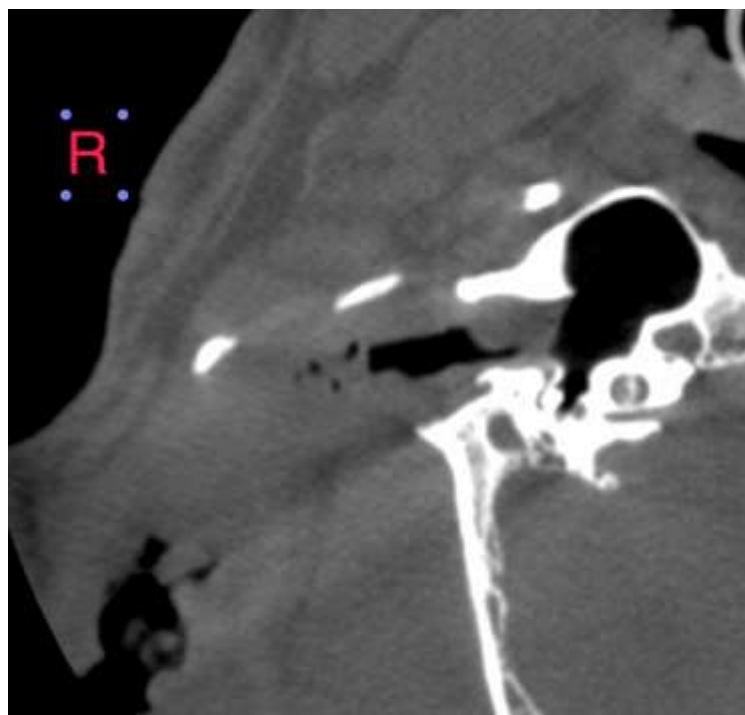
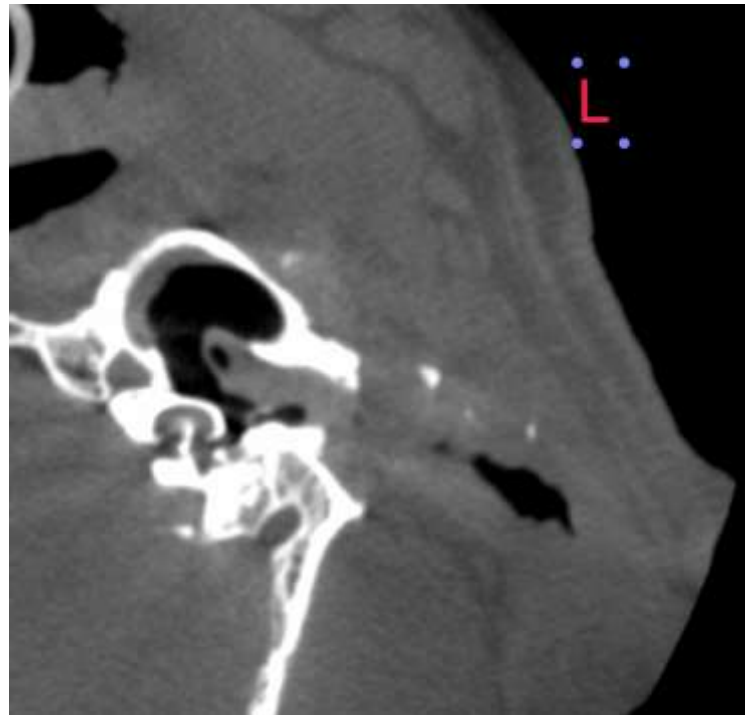Cathryn Sayer

INVOICE

47219

DATE

8-31-21





PATIENT

Silvie Golden
Retriever Freedom
Rescue

SPECIES

Canine

BREED

Golden Retriever

SEX

FS

AGE

8 Years

INTERPRETED BY

Sebastian Jawinski,
German Board
Certified Vet
Specialist in
Diagnostic Imaging

HOSPITAL NAME

Animal Health Care
Denver

REFERRING VET

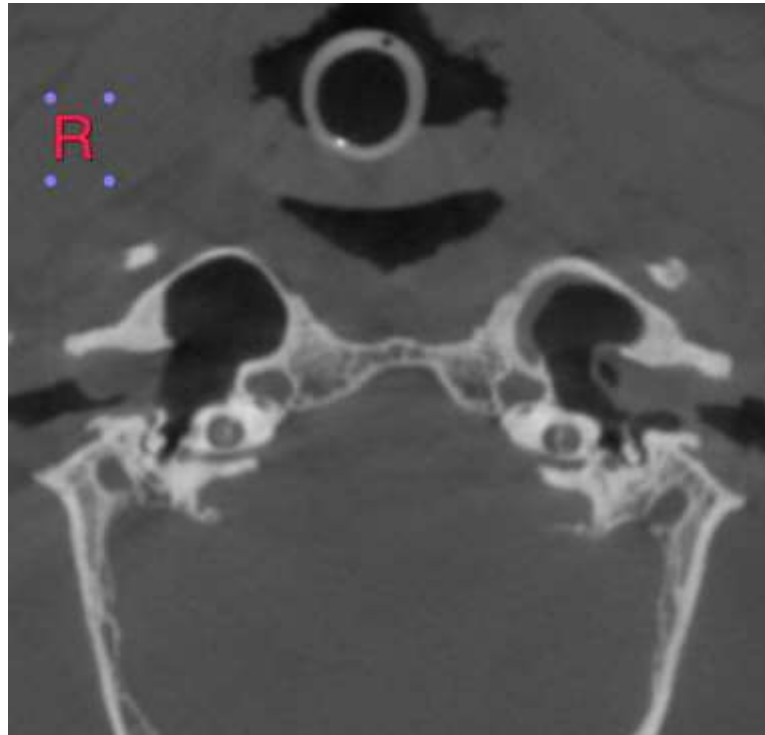
Cathryn Sayer

INVOICE

47219

DATE

8-31-21



The information and recommendations provided are based on the images presented by the referring veterinarian. No evaluation can be communicated regarding pathology that was not visible in the image/video clips provided.

Thank you for this referral. If the clinical or image interpretation does not parallel your findings or if I can be of any further assistance, please contact me.

Sebastian Jawinski, German Board Certified Vet Specialist in Diagnostic Imaging
Sebastian.Jawinski@sonopath.com