

**PATIENT**

Reilly McDowell

PRESENTING CLINICAL SIGNS

Dog not feeling comfortable when standing up on the back legs. On palpating the spine, particularly the thoracolumbar area, there is discomfort (T13-L1). :

SPECIES

Canine

RADIOGRAPHIC FINDINGS**Thoracic & Lumbar Spine**

The presented spine shows a harmonic course with inconspicuous vertebral bodies.

BREED

Labrador Retriever

There are moderate degenerative changes detected showing multiple ventral spondylosis (Th1/2, Th3/4, Th4/5, Th10/11, L4/5 and L7/S1) and mild hypertrophic arthrosis of the facet joints of the lumbar spine.

SEX

Male Neutered

There is no evidence of osteolysis, a fracture, or subluxation. Calcification of the nuclei is not recognized.

AGE

6 Years

RADIOGRAPHIC DIAGNOSIS

- Moderate degenerative changes of the spine

INTERPRETED BY

Sebastian Jawinski,
German Board
Certified Vet
Specialist in
Diagnostic Imaging

INTERPRETATION OF THE FINDINGS & FURTHER RECOMMENDATIONS

The thoracolumbar transition is inconspicuous. This does not exclude non-radiopaque protrusions with compression of the spinal cord. Lesions of muscles/tendons or inflammatory changes of soft tissues cannot be fully excluded as well. Especially the lumbosacral transition shows marked ventral spondylosis and could be an indirect sign for degenerative lumbosacral (dynamic) stenosis.

HOSPITAL NAME

Truscott Animal
Hospital

REFERRING VET

Dr. Medhat Meawad

INVOICE

47246

DATE

8-31-21



PATIENT

Reilly McDowell

SPECIES

Canine

BREED

Labrador Retriever

SEX

Male Neutered

AGE

6 Years

INTERPRETED BY

Sebastian Jawinski,
German Board
Certified Vet
Specialist in
Diagnostic Imaging

HOSPITAL NAME

Truscott Animal
Hospital

REFERRING VET


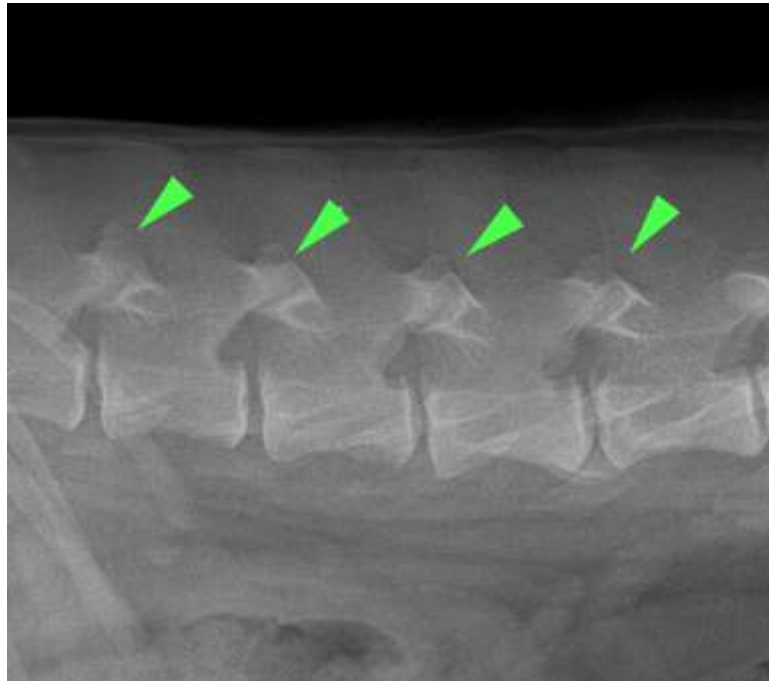
Dr. Medhat Meawad

INVOICE

47246

DATE

8-31-21





PATIENT

Reilly McDowell

The information and recommendations provided are based on the images presented by the referring veterinarian. No evaluation can be communicated regarding pathology that was not visible in the image/video clips provided.

SPECIES

Canine

Thank you for this referral. If the clinical or image interpretation does not parallel your findings or if I can be of any further assistance, please contact me.

Sebastian Jawinski, German Board Certified Vet Specialist in Diagnostic Imaging
Sebastian.Jawinski@sonopath.com

BREED

Labrador Retriever

SEX

Male Neutered

AGE

6 Years

INTERPRETED BY

Sebastian Jawinski,
German Board
Certified Vet
Specialist in
Diagnostic Imaging

HOSPITAL NAME

Truscott Animal
Hospital

REFERRING VET

Dr. Medhat Meawad

INVOICE

47246

DATE

8-31-21