



PATIENT

Maggie Rickard

PRESENTING CLINICAL SIGNS

Has been Vomiting since yesterday. Did get into the trash a few days ago. There was paper and plastic in the trash.
Abnormal PE/Chem/CBC/UA Results: PE:SOME DISCOMFORT TO CRANIAL ABDOMINAL PALPATION. Seemed healthy other wise. NO RESENT LABS

SPECIES

Canine

RADIOGRAPHIC STUDY OF THE ABDOMEN

Right/left lateral and vd views provided for review.

BREED

Labrador Retriever
Mix

RADIOGRAPHIC FINDINGS

All displayed bony structures are unremarkable without signs of a fracture, sub-/luxation and/or a lytic/sclerotic process.

SEX

Spayed

Liver and spleen present as expected and are well defined.

AGE

6 Years, 11 Months

The stomach is mildly gas distended showing a thickened wall in the vd projection. The left lateral view presents a linear mineral-dense structure of approximately 10.7 cm, partially superimposing with the stomach and running horizontally. The small intestine presents some chaotic, gas filled loops in the right cranial abdomen and is predominantly empty apart from that. The descendent colon present mild hyperperistaltic areas with some radiopaque ingesta cranial to the pelvis.

INTERPRETED BY

Sebastian Jawinski,
German Board
Certified Vet
Specialist in
Diagnostic Imaging

Both kidneys are not well visualized but considered to be normal.

No signs of abdominal or retroperitoneal effusion.

HOSPITAL NAME

Elizabeth Animal
Hospital

RADIOGRAPHIC DIAGNOSIS

- Mild signs of a gastroenteritis
- Questionable linear foreign body (only seen in the left lateral projection)

REFERRING VET

Kim Allyn, DVM

INTERPRETATION OF THE FINDINGS & FURTHER RECOMMENDATIONS

Radiographs likely represent an inflammatory process such as unspecific gastroenteritis. The questionable linear structure is only recognized in the left lateral projection. A gastric or intestinal foreign body cannot be fully excluded. This finding may be artificial showing a skin fold in left lateral recumbency. An overt obstructive pattern is not recognized. A radiographic follow-up and/or a complementary abdominal ultrasound could be performed next.

INVOICE

47244

DATE

8-31-21



PATIENT

Maggie Rickard

SPECIES

Canine

BREED

Labrador Retriever
Mix

SEX

Spayed

AGE

6 Years, 11 Months

INTERPRETED BY

Sebastian Jawinski,
German Board
Certified Vet
Specialist in
Diagnostic Imaging

HOSPITAL NAME

Elizabeth Animal
Hospital

REFERRING VET

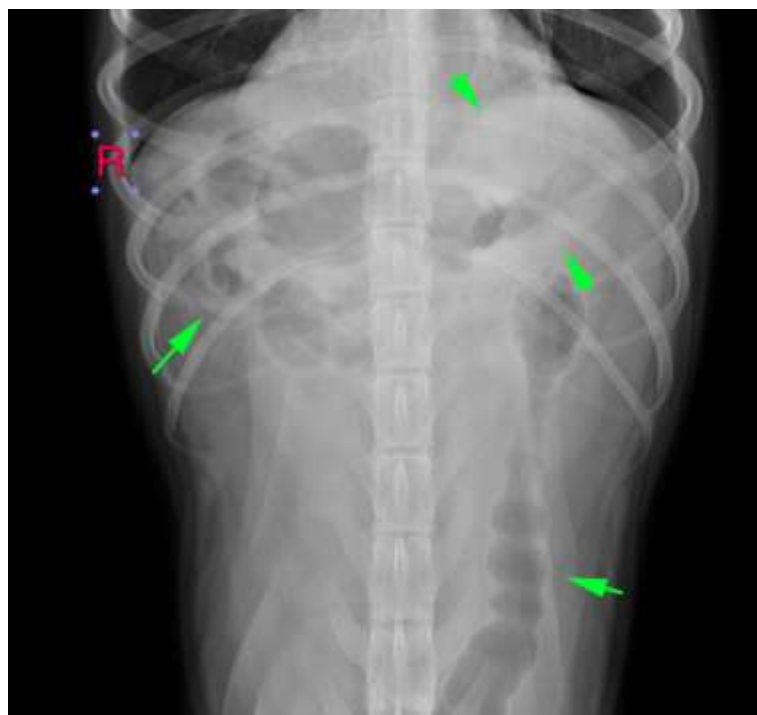
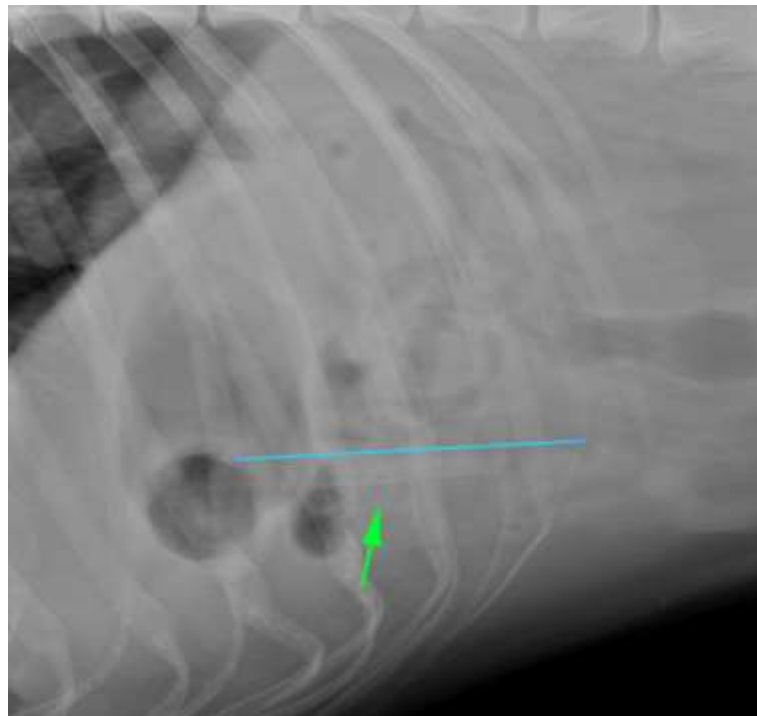
Kim Allyn, DVM

INVOICE

47244

DATE

8-31-21





PATIENT

Maggie Rickard

The information and recommendations provided are based on the images presented by the referring veterinarian. No evaluation can be communicated regarding pathology that was not visible in the image/video clips provided.

Thank you for this referral. If the clinical or image interpretation does not parallel your findings or if I can be of any further assistance, please contact me.

SPECIES

Canine

Sebastian Jawinski, German Board Certified Vet Specialist in Diagnostic Imaging
Sebastian.Jawinski@sonopath.com

BREED

Labrador Retriever
Mix

SEX

Spayed

AGE

6 Years, 11 Months

INTERPRETED BY

Sebastian Jawinski,
German Board
Certified Vet
Specialist in
Diagnostic Imaging

HOSPITAL NAME

Elizabeth Animal
Hospital

REFERRING VET

Kim Allyn, DVM

INVOICE

47244

DATE

8-31-21