

**PATIENT**

Ellie Pezzillo

PRESENTING CLINICAL SIGNS

Patient presented for limping off and on for the last month, occurs more when patient is laying down for long periods of time. Crepitus palpated in back right stifle and intermittently lame on this leg when at a trop

SPECIES

Canine

RADIOGRAPHIC FINDINGS

Pelvis/coxofemoral joints:

BREED

English Bulldog

The bony structures of the pelvis and the sacroiliac joints show marked degenerative changes. There is no evidence of a lytic process noted.

SEX

FS

The coxofemoral joints reveal bilateral prominent remodeling of the femoral head/neck with smooth and even new bone formation at the level of the cranial and lateral joint space/acetabular rim. In the current positioning the femoral head lies outside the acetabulum and with marked incongruity of the joint space.

AGE

7 Years

Stifles:

There is a moderate amount of smooth new bone at all joint levels recognized including the tip and base of the patella, the femoral condyles and the fabellae as well as the tibial plateau. The patella has a normal position in the lateral projections. No other osseous abnormalities are detected. The right stifle additionally reveals cranial displacement of the infrapatellar fat pad.

INTERPRETED BY

Sebastian Jawinski,
German Board
Certified Vet
Specialist in
Diagnostic Imaging

RADIOGRAPHIC DIAGNOSIS

- Moderate bilateral coxarthrosis
- Moderate bilateral arthrosis of the stifles with signs of an active osteoarthritis/synovitis on the right side

HOSPITAL NAME

Boca Park Animal
Hospital

INTERPRETATION OF THE FINDINGS & FURTHER RECOMMENDATIONS

The described degenerative changes of the hip joints and both stifles are chronic issues and somehow age- and breed-appropriate. However, joint effusion of the right stifle indicates an active/reactive process such synovitis/osteoarthritis. The findings could be secondary to a lesion of the CCL. Other soft tissue injuries (meniscus, other ligaments, etc.) cannot be completely excluded.

REFERRING VET

Dr. Corinna Gorgon

INVOICE

47234

DATE

8-31-21



PATIENT

Ellie Pezzillo

SPECIES

Canine

BREED

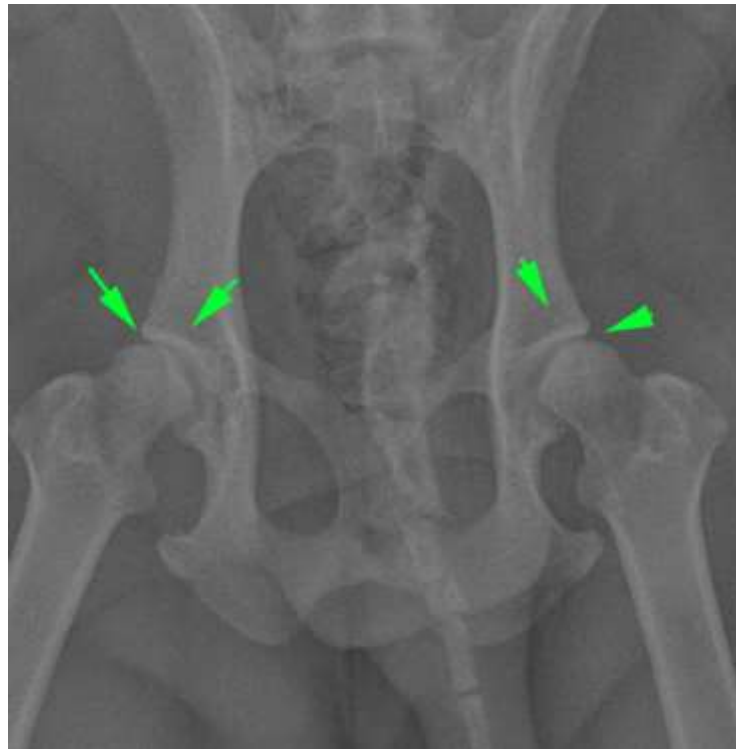
English Bulldog

SEX

FS

AGE

7 Years



INTERPRETED BY

Sebastian Jawinski,
German Board
Certified Vet
Specialist in
Diagnostic Imaging

HOSPITAL NAME

Boca Park Animal
Hospital

REFERRING VET

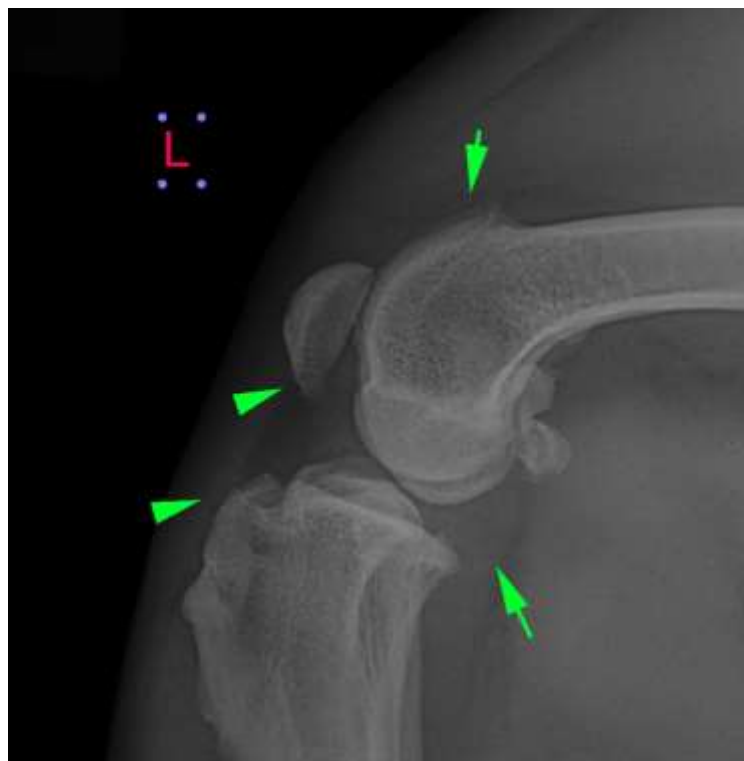
Dr. Corinna Gorgon

INVOICE

47234

DATE

8-31-21





PATIENT

Ellie Pezzillo

SPECIES

Canine

BREED

English Bulldog

SEX

FS

AGE

7 Years

INTERPRETED BY

Sebastian Jawinski,
German Board
Certified Vet
Specialist in
Diagnostic Imaging

HOSPITAL NAME

Boca Park Animal
Hospital

REFERRING VET

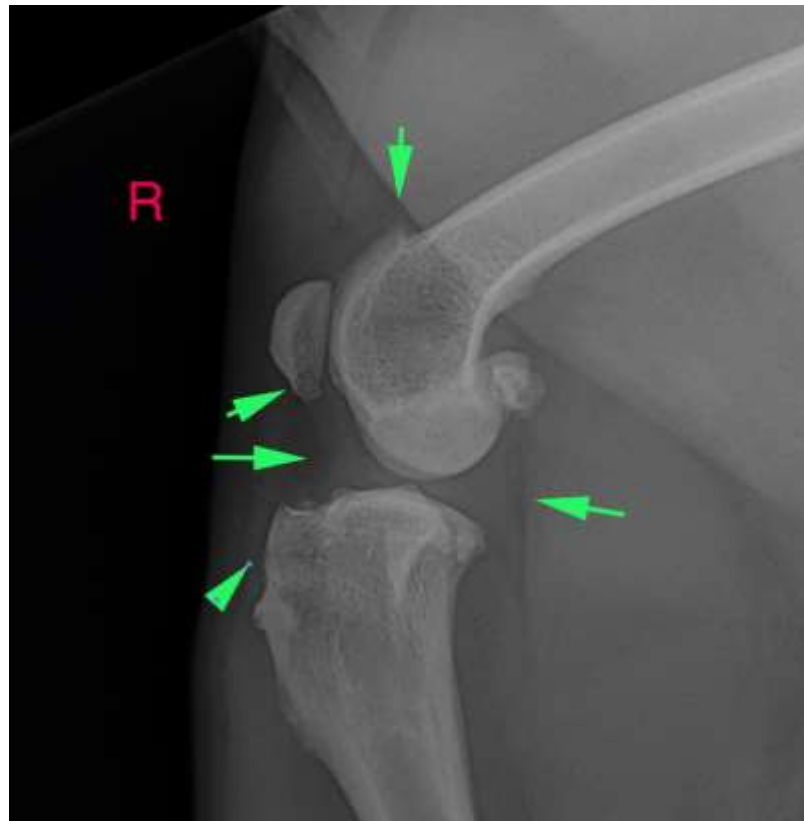Dr. Corinna Gorgon

INVOICE

47234

DATE

8-31-21



The information and recommendations provided are based on the images presented by the referring veterinarian. No evaluation can be communicated regarding pathology that was not visible in the image/video clips provided.

Thank you for this referral. If the clinical or image interpretation does not parallel your findings or if I can be of any further assistance, please contact me.

Sebastian Jawinski, German Board Certified Vet Specialist in Diagnostic Imaging
Sebastian.Jawinski@sonopath.com