

**PATIENT**

Betty Ruff Rescue

PRESENTING CLINICAL SIGNS

Foster notes 1 month ago slightly limping LFL then 2-3 days ago favoring all the time. Dasuquin qd in pm, sentinel q 30 d, O notes slight improvement with chondroprotec. O notes possible nail bed pain. Previously dx'd with cutaneous hemangiosarcoma

SPECIES

Canine

Abnormal PE/Chem/CBC/UA Results: Heart murmur

BREED

Lab Mix

RADIOGRAPHIC FINDINGS**Shoulders**

On the left there is marked lysis of the glenoid and irregular peripheral new bone formation of the glenoidal region of the scapula with extension in the peripheral soft tissue noted. The lesion is predominantly lytic with mild sclerotic and irregular margins. The caudal humeral head is inconspicuous.

SEX

FS

Relevant osteoarthritis is not recognized.

AGE

9 Years

The right shoulder is inconspicuous.

RADIOGRAPHIC DIAGNOSIS

- Osteolytic lesion of the left scapula with destruction of glenoidal cortical bone margins

INTERPRETED BY

Sebastian Jawinski,
German Board
Certified Vet
Specialist in
Diagnostic Imaging

INTERPRETATION OF THE FINDINGS & FURTHER RECOMMENDATIONS

Radiographs speak for an aggressive bone lesion as seen with malignant neoplasia. Osteosarcoma is a common differential diagnosis. Pathologic (micro-) fractures of the glenoid are likely.

HOSPITAL NAME

All Creatures Animal
Hospital Stuart

For a confirmation of the radiographic assumed diagnosis biopsy is needed. However, consider that bone biopsy often does not reflect reality and verified diagnosis is a matter of clinical presentation and follow up radiographs. I would rule out osteomyelitis in this case. Consider chest rads for further evaluation.

REFERRING VET

Mary Bressman

INVOICE

47233

DATE

8-31-21



PATIENT

Betty Ruff Rescue

SPECIES

Canine

BREED

Lab Mix

SEX

FS

AGE

9 Years

INTERPRETED BY

Sebastian Jawinski,
German Board
Certified Vet
Specialist in
Diagnostic Imaging

HOSPITAL NAME

All Creatures Animal
Hospital Stuart

REFERRING VET

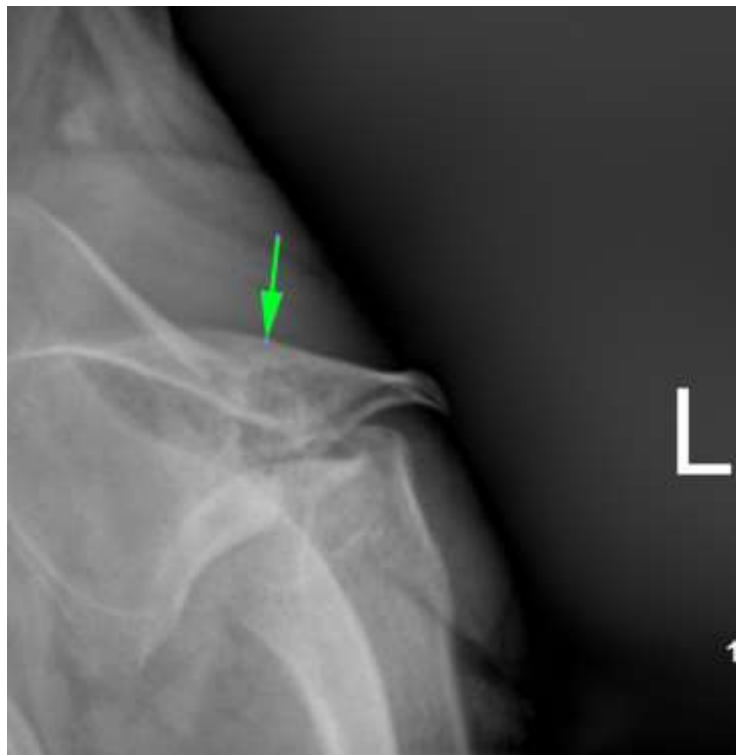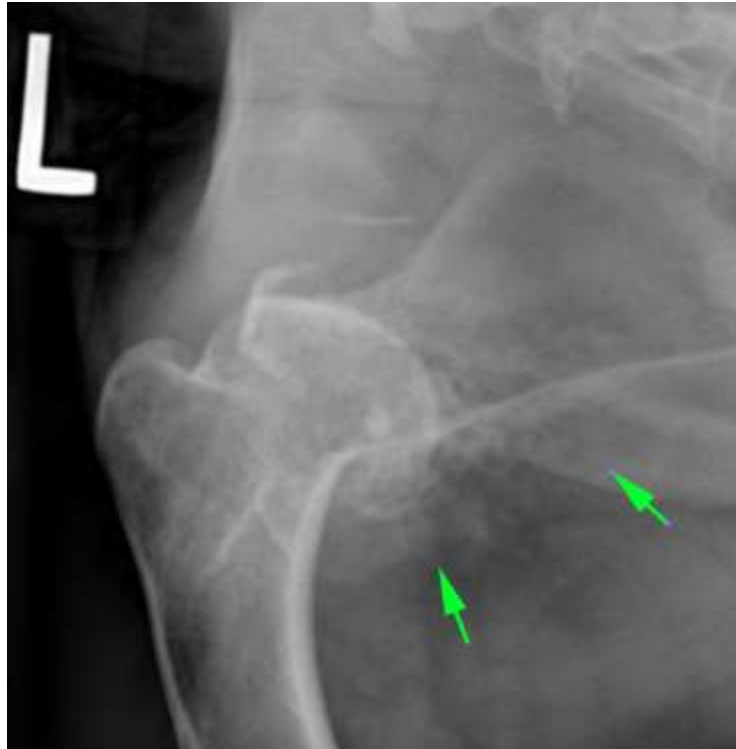
Mary Bressman

INVOICE

47233

DATE

8-31-21





PATIENT

Betty Ruff Rescue

The information and recommendations provided are based on the images presented by the referring veterinarian. No evaluation can be communicated regarding pathology that was not visible in the image/video clips provided.

SPECIES

Canine

Thank you for this referral. If the clinical or image interpretation does not parallel your findings or if I can be of any further assistance, please contact me.

BREED

Lab Mix

Sebastian Jawinski, German Board Certified Vet Specialist in Diagnostic Imaging
Sebastian.Jawinski@sonopath.com

SEX

FS

AGE

9 Years

INTERPRETED BY

Sebastian Jawinski,
German Board
Certified Vet
Specialist in
Diagnostic Imaging

HOSPITAL NAME

All Creatures Animal
Hospital Stuart

REFERRING VET

Mary Bressman

INVOICE

47233

DATE

8-31-21