



PATIENT

Ezio Carlin

PRESENTING CLINICAL SIGNS

Large intra-abdominal mass. CT for surgical evaluation and staging

SPECIES

Feline

COMPUTED TOMOGRAPHY STUDY OF THE THORAX & ABDOMEN

Pre/post contrast studies provided for review.

BREED

DSH

Thorax:

The lungs are regularly ventilated with close contact to the inner thoracic wall on all sides. No evidence of pleural thickening, fluid accumulation or free pleural gas is noticed.

SEX

Male Neutered

Pulmonary density is within normal limits, there is no evidence of focal or nodular pulmonary lesions.

AGE

12 Years

Mediastinum is regular in width and density. The sternal lymph nodes show mild enlargement.

Thoracic trachea and esophagus present as expected.

INTERPRETED BY

Sebastian Jawinski,
German Board
Certified Vet
Specialist in
Diagnostic Imaging

Heart is inconspicuous as far as can be assessed with CT.

Diaphragm is normal.

The extra-thoracic soft tissues, thoracic spine as well as ribs and sternum are unremarkable.

Abdomen:

HOSPITAL NAME

Mobile Pet Imaging
CFL

The right lateral abdomen presents a large, rounded, soft tissue dense mass of 6.0 x 5.4 cm. After contrast, a prominent ring enhancing uptake is noted with a mildly irregular hypodense center. The right pancreas has broad-based contact as well as the duodenum. The periphery reveals marked increase of the fat tissue density. There is moderate free fluid in the peritoneal space recognized. Liver and spleen show normal findings in terms of size, surface, shape, and contrast behavior. Both are clearly separated from the mass as well as the right kidney. Gallbladder is inconspicuous without evidence of cholestasis.

REFERRING VET

Meaux

Unremarkable presentation of the bilaterally symmetrical kidneys.

INVOICE

47196

Adrenal glands are in normal limits.

Ureters, urinary bladder, trigonum and urethra are presented as expected.

DATE

8-30-21

Abdominal lymph nodes and abdominal vessels have no particular findings.



PATIENT

Ezio Carlin

SPECIES

Feline

BREED

DSH

SEX

Male Neutered

AGE

12 Years

INTERPRETED BY

Sebastian Jawinski,
German Board
Certified Vet
Specialist in
Diagnostic Imaging

HOSPITAL NAME

Mobile Pet Imaging
CFL

REFERRING VET

Meaux

INVOICE

47196

DATE

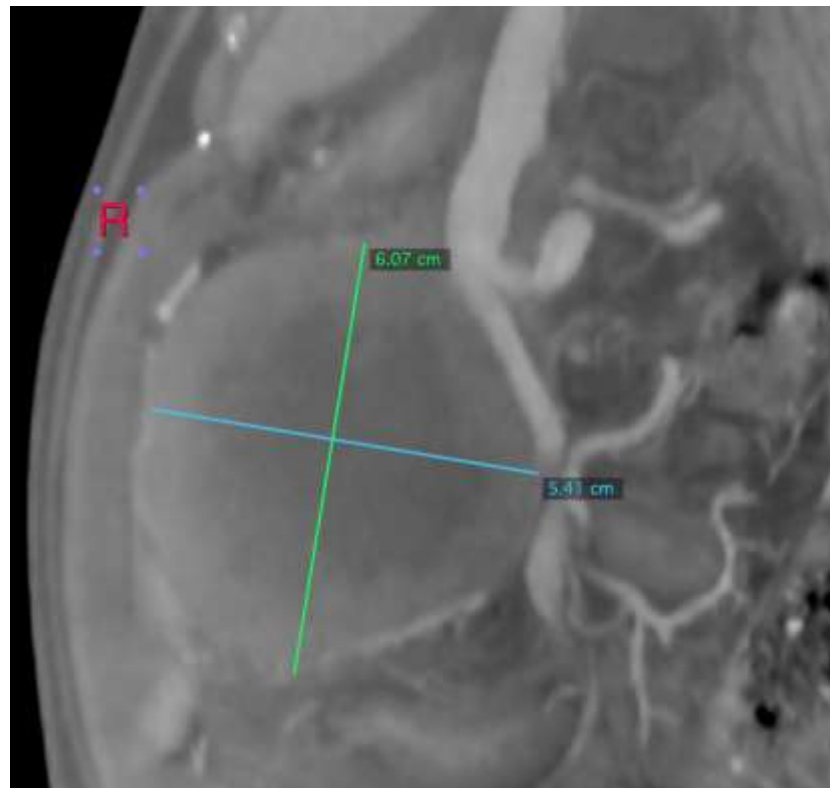
8-30-21

COMPUTED TOMOGRAPHIC DIAGNOSIS

- Abscess of the right pancreas
- Moderate ascites with signs of a peritonitis
- Mild sternal lymphadenopathy
- Normal findings of the thorax apart from that

INTERPRETATION OF THE FINDINGS & FURTHER RECOMMENDATIONS

The CT findings most likely present a pancreatic lesion as commonly seen with pancreatic abscess and central necrosis. This may be a foreign body triggered/infectious lesion, the duodenum is adjacent to the mass and not clearly separated. A pancreatic or intestinal tumor is unlikely (adenocarcinoma) but cannot be fully excluded. The current CT does not show signs of a regional or distant metastatic spread.





PATIENT

Ezio Carlin

SPECIES

Feline

BREED

DSH

SEX

Male Neutered

AGE

12 Years

INTERPRETED BY

Sebastian Jawinski,
German Board
Certified Vet
Specialist in
Diagnostic Imaging

HOSPITAL NAME

Mobile Pet Imaging
CFL

REFERRING VET

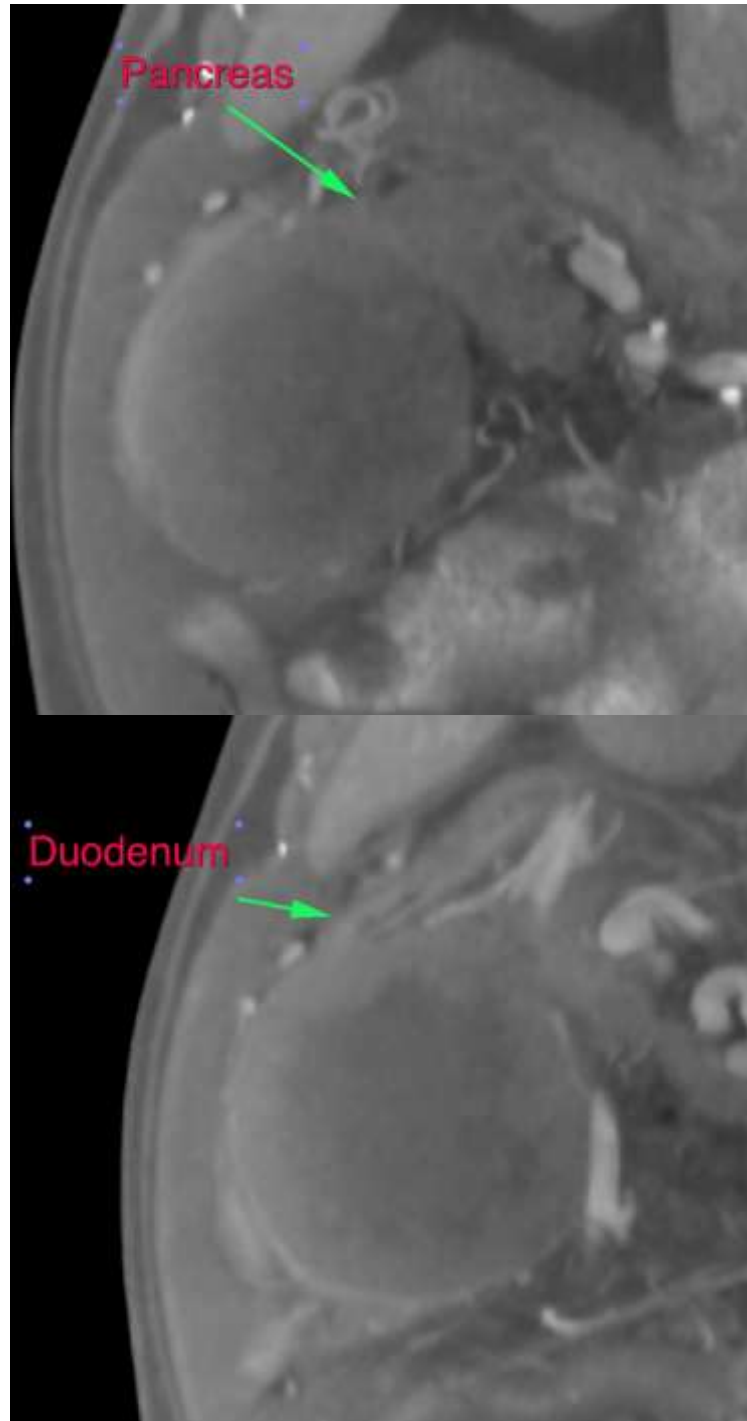
Meaux

INVOICE

47196

DATE

8-30-21





PATIENT

Ezio Carlin

SPECIES

Feline

BREED

DSH

SEX

Male Neutered

AGE

12 Years

INTERPRETED BY

Sebastian Jawinski,
German Board
Certified Vet
Specialist in
Diagnostic Imaging

HOSPITAL NAME

Mobile Pet Imaging
CFL

REFERRING VET

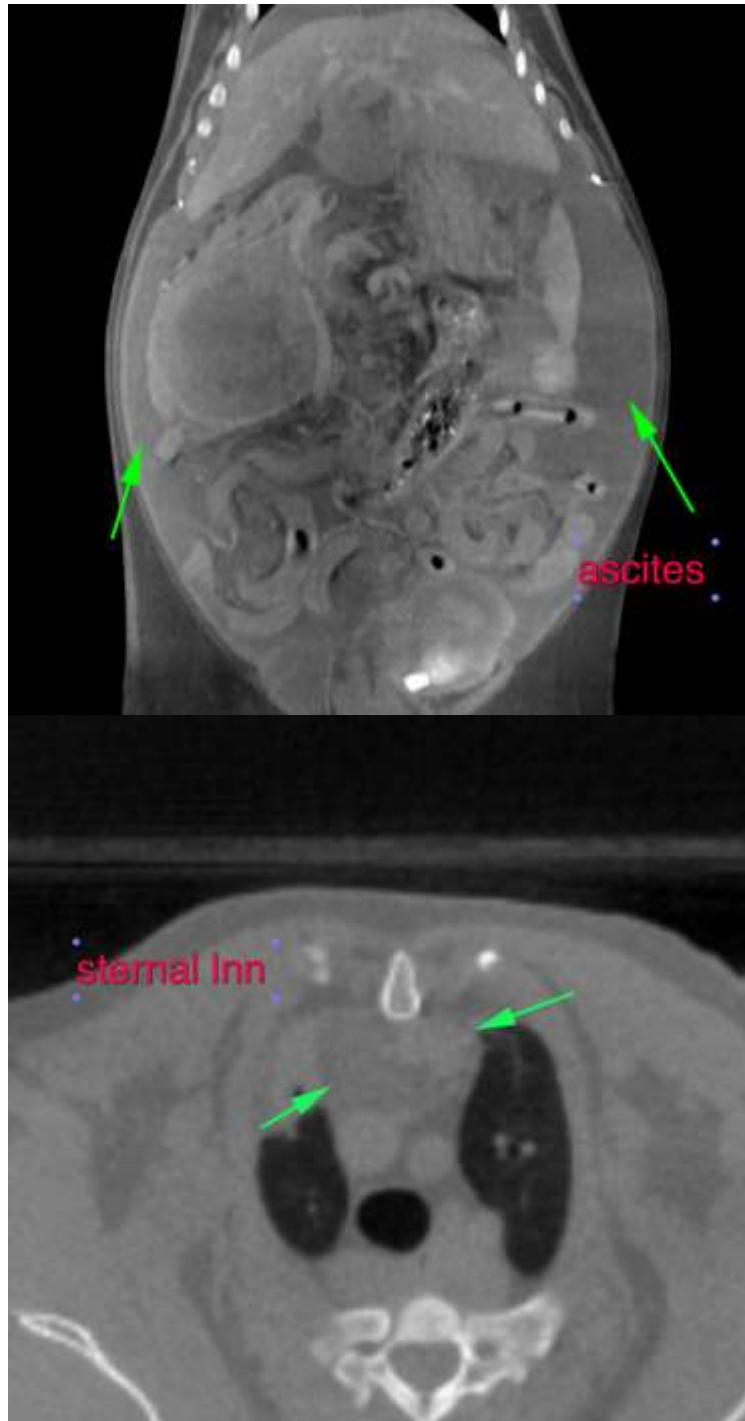
Meaux

INVOICE

47196

DATE

8-30-21





PATIENT

Ezio Carlin

The information and recommendations provided are based on the images presented by the referring veterinarian. No evaluation can be communicated regarding pathology that was not visible in the image/video clips provided.

Thank you for this referral. If the clinical or image interpretation does not parallel your findings or if I can be of any further assistance, please contact me.

SPECIES

Feline

Sebastian Jawinski, German Board Certified Vet Specialist in Diagnostic Imaging
Sebastian.Jawinski@sonopath.com

BREED

DSH

SEX

Male Neutered

AGE

12 Years

INTERPRETED BY

Sebastian Jawinski,
German Board
Certified Vet
Specialist in
Diagnostic Imaging

HOSPITAL NAME

Mobile Pet Imaging
CFL

REFERRING VET

Meaux

INVOICE

47196

DATE

8-30-21