



PATIENT

Stiletto Maloney

PRESENTING CLINICAL SIGNS

Acute onset of IVDD. CP deficits, ataxia

SPECIES

K9

COMPUTED TOMOGRAPHY OF THE HEAD & SPINE

Pre/post contrast studies provided for review.

BREED

Chihuahua Mix

Head:

The interhemispheric gap is in the midline with no evidence of a mass effect. As far as can be assessed, there are regular cortical gyri in the cerebral and cerebellar region with a symmetrical ventricular system. Brain stem and cerebellum are inconspicuous. Pituitary gland is within normal limits.

SEX

FS

Bony structures of skull and the skull foramina of the cranial nerves are laterally symmetrical and inconspicuous. Both tympanic bullae are completely ventilated with a regular tympanic bulla wall. External ear canals are ventilated in all sections, walls of the external ear canals, the adjacent temporomandibular joints and the nasopharyngeal meatus have no particular findings.

AGE

9 Years

INTERPRETED BY

Sebastian Jawinski,
German Board
Certified Vet
Specialist in
Diagnostic Imaging

Frontal sinuses and the orbital contents are laterally symmetrical without evidence of a retrobulbar lesion. Nasal cavities are ventilated regularly. Post contrast images show no pathological enhancement. Soft tissues of the head and neck are symmetrical and of homogeneous density, especially the medial retropharyngeal lymph nodes.

Spine:

HOSPITAL NAME

Rockaway Animal
Hospital

Presented bony structures of the spine are unremarkable with an inconspicuous harmonic atlanto-occipital and -axial transition and a thoracolumbar- and lumbosacral transition.

Vertebral bodies are of regular density without signs of a lytic or sclerotic process. There is no evidence of a fracture and/or sub-/luxation.

REFERRING VET

Dr. Sanam Maniar

There is a mild disc protrusion recognized at the level of Th12/13. The protrusion is broad-based and located medial to left-lateral and extends caudally to the cranial section of Th13. The spinal cord gets mildly dorsally elevated. The equine cauda/cauda fibers are central and homogeneous and show no compressive lesion.

INVOICE

47186

Calcification of the nuclei is not recognized. The intervertebral disc spaces are of even diameter.

DATE

8-27-21

Paravertebral soft tissues are bilaterally symmetrical, especially the course of the femoral and sciatic nerves is inconspicuous. Unilateral atrophy of the paraspinal and/or pelvic musculature is not noted.

**PATIENT**

Stiletto Maloney

SPECIES

K9

BREED

Chihuahua Mix

SEX

FS

AGE

9 Years

INTERPRETED BY

Sebastian Jawinski,
German Board
Certified Vet
Specialist in
Diagnostic Imaging

HOSPITAL NAME

Rockaway Animal
Hospital

REFERRING VET

Dr. Sanam Maniar

INVOICE

47186

DATE

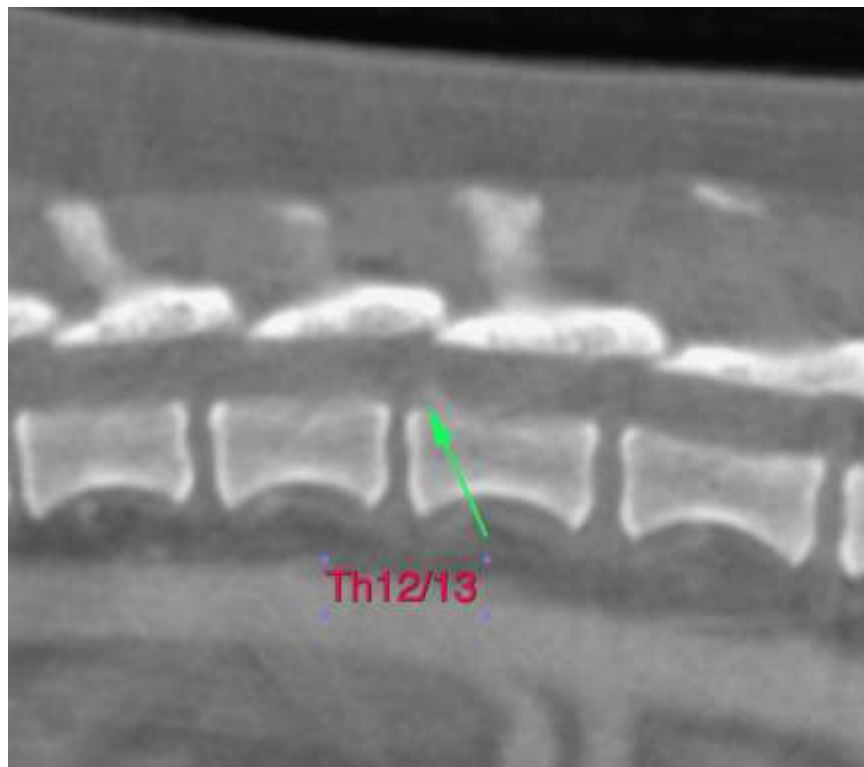
8-27-21

COMPUTED TOMOGRAPHIC DIAGNOSIS

- Normal CT findings of the head
- Mild protrusion Th12/13

INTERPRETATION OF THE FINDINGS & FURTHER RECOMMENDATIONS

The CT findings must be correlated with the clinical presentation. The protrusion at the level of Th12/13 indicates mild compression of the spinal cord. There is no compelling indication for decompressive surgery from a CT perspective. However, acute/explosive herniations are difficult to detect with CT; therefore, further compressive lesions are not ruled out completely. I would favor a conservative approach unless neurologic deficits progress. A complementary CT myelogram is recommended then to reassure the right localization.





PATIENT

Stiletto Maloney

SPECIES

K9

BREED

Chihuahua Mix

SEX

FS

AGE

9 Years

INTERPRETED BY

Sebastian Jawinski,
German Board
Certified Vet
Specialist in
Diagnostic Imaging

HOSPITAL NAME

Rockaway Animal
Hospital

REFERRING VET

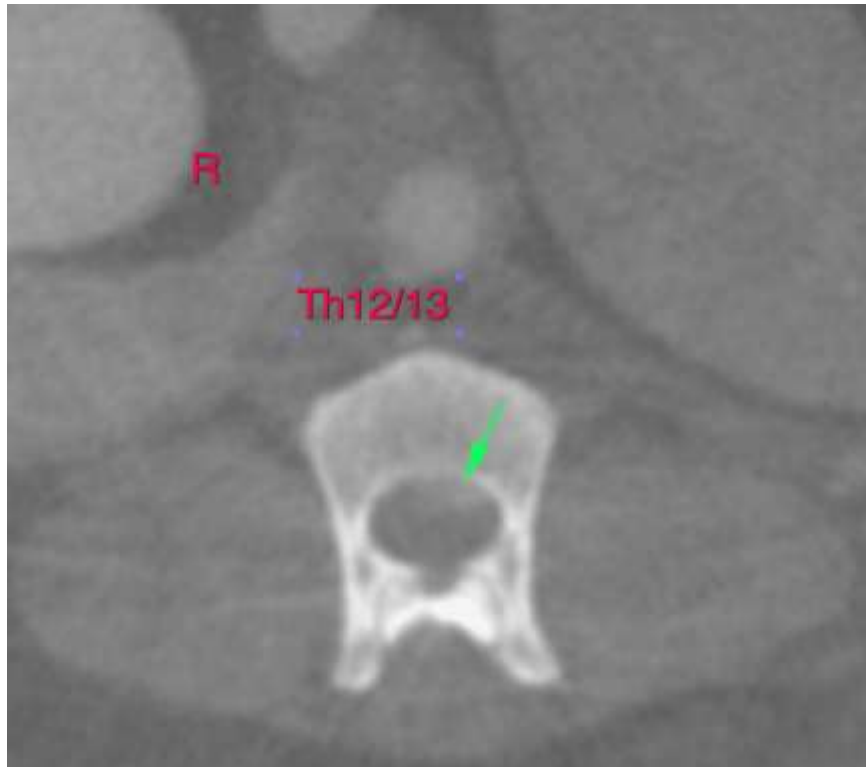Dr. Sanam Maniar

INVOICE

47186

DATE

8-27-21



The information and recommendations provided are based on the images presented by the referring veterinarian. No evaluation can be communicated regarding pathology that was not visible in the image/video clips provided.

Thank you for this referral. If the clinical or image interpretation does not parallel your findings or if I can be of any further assistance, please contact me.

Sebastian Jawinski, German Board Certified Vet Specialist in Diagnostic Imaging
Sebastian.Jawinski@sonopath.com