



PATIENT

Kaytie Dysart

PRESENTING CLINICAL SIGNS

Kaytie presents for CT and rhinoscopy after one month duration of persistent mucoid drainage from the left nostril. Chronic congestion and intermittent epistaxis noted. Not responsive to steroids. Slight response to Cerenia nose drops. Minimal benefit from clindamycin.

SPECIES

Canine

COMPUTED TOMOGRAPHY OF THE HEAD

Pre/post contrast studies provided for review.

BREED

Irish Setter

COMPUTED TOMOGRAPHIC FINDINGS

The neurocranium shows normal findings. Bony structures of skull and the skull foramina of the cranial nerves are laterally symmetrical and inconspicuous.

SEX

FS

The left tympanic bulla is nearly completely obliterated by soft tissue dense material which shows a sharp margination to air. The bulla wall shows multiple lytic perforations with marked new bone formation. Petrosal structures are respected and intact.

AGE

9 Years

The right tympanic bulla presents similar findings but less obvious than left. External ear canals are ventilated in all sections, walls of the external ear canals present mild calcifications. The adjacent temporomandibular joints and the nasopharyngeal meatus have no particular findings.

INTERPRETED BY

Sebastian Jawinski,
German Board
Certified Vet
Specialist in
Diagnostic Imaging

The left nasal cavity and the left frontal sinus are completely obliterated with fluid-dense/soft tissue dense material. There are several small mineral dense structures detected showing an amorphous shape. In the ventral and lateral section, a more linear structure is seen. The bony borders are intact, especially margins to the cribriform plate.

Orbital contents are laterally symmetrical without evidence of a retrobulbar lesion.

HOSPITAL NAME

Suncoast Veterinary

Post contrast images show no pathological enhancement. Soft tissues of the head and neck are symmetrical and of homogeneous density, especially the medial retropharyngeal lymph nodes.

REFERRING VET

Byron Young

COMPUTED TOMOGRAPHIC DIAGNOSIS

- Signs of a severe left sided rhinitis/sinusitis, foreign material is suspected
- Chronic moderate otitis media left, mild otitis media right
- Bilateral, mild and chronic otitis externa

INVOICE

47183

INTERPRETATION OF THE FINDINGS & FURTHER RECOMMENDATIONS

The unilateral appearance of the nasal changes and the mineral dense structures are highly suspicious for foreign body triggered rhinitis/sinusitis. Osteolysis is not detected, neoplasia therefore is unlikely. Rhinoscopy and lavage are recommended including biopsy and microbiological testing.

DATE

8-27-21



PATIENT

Kaytie Dysart

Findings of both bullae must be correlated with the clinical presentation and may be incidental. Obliteration and mild reactive bone lysis of the bulla wall are commonly seen with polyps which I suspect on the left. Signs of a nasopharyngeal extension are not recognized.

SPECIES

Canine

BREED

Irish Setter

SEX

FS

AGE

9 Years

INTERPRETED BY

Sebastian Jawinski,
German Board
Certified Vet
Specialist in
Diagnostic Imaging

HOSPITAL NAME

Suncoast Veterinary

REFERRING VET

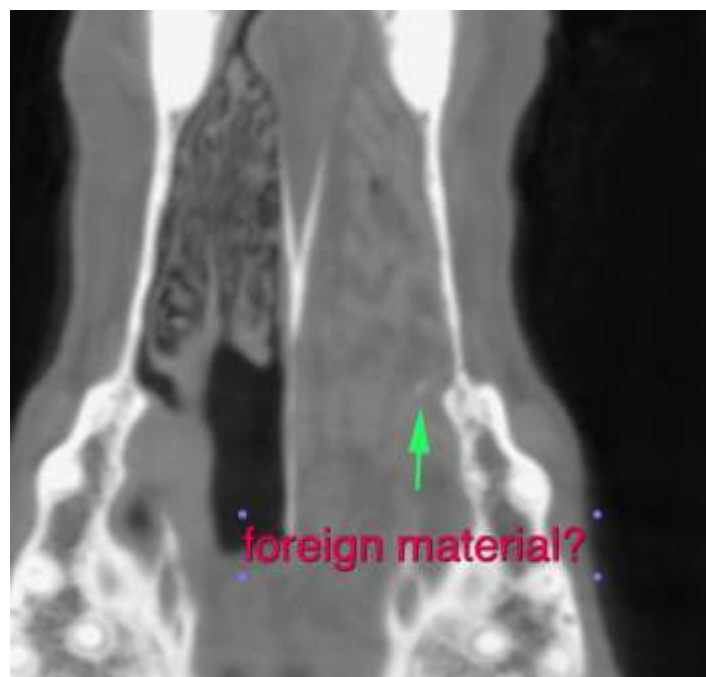
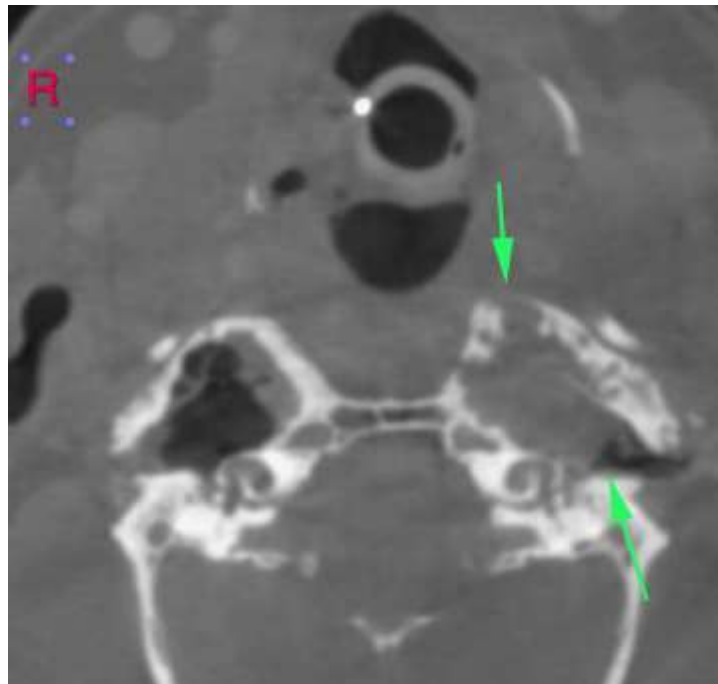
Byron Young

INVOICE

47183

DATE

8-27-21





PATIENT

Kaytie Dysart

SPECIES

Canine

BREED

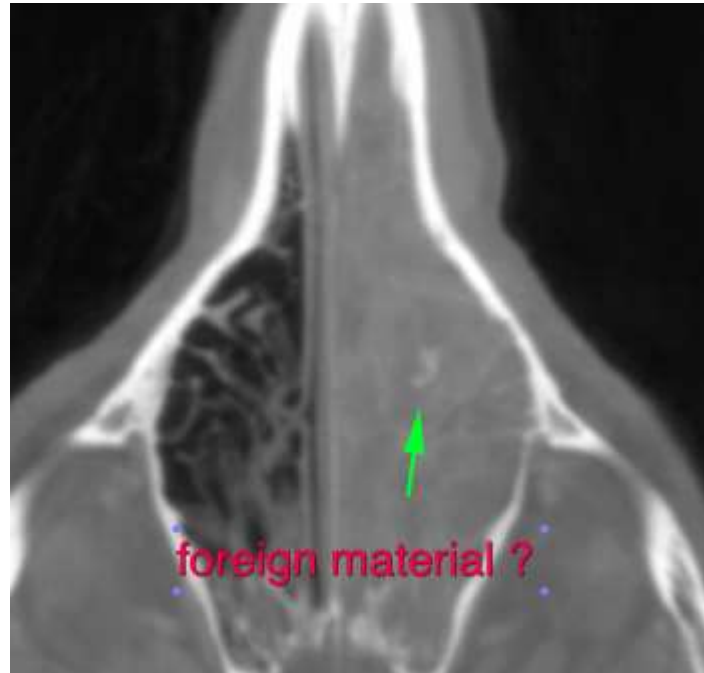
Irish Setter

SEX

FS

AGE

9 Years



INTERPRETED BY

Sebastian Jawinski,
German Board
Certified Vet
Specialist in
Diagnostic Imaging

HOSPITAL NAME

Suncoast Veterinary

REFERRING VET

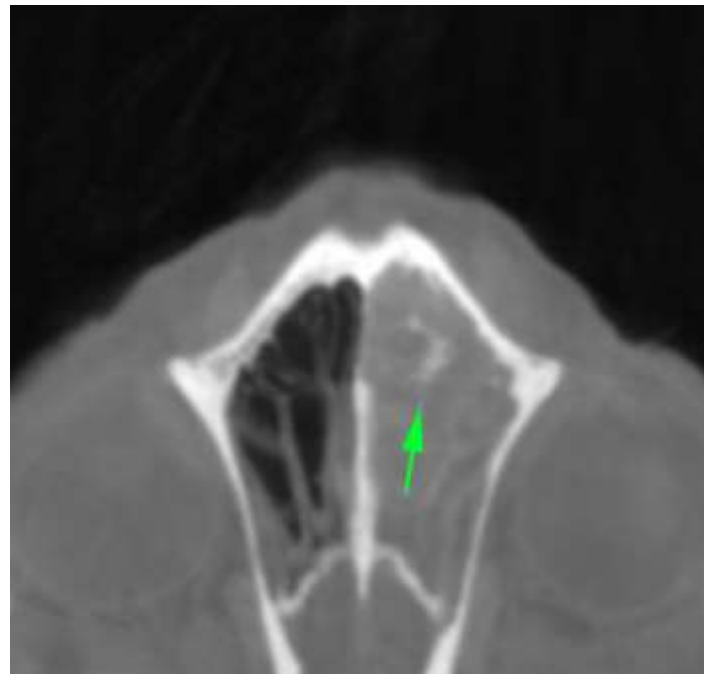
Byron Young

INVOICE

47183

DATE

8-27-21





PATIENT

Kaytie Dysart

The information and recommendations provided are based on the images presented by the referring veterinarian. No evaluation can be communicated regarding pathology that was not visible in the image/video clips provided.

Thank you for this referral. If the clinical or image interpretation does not parallel your findings or if I can be of any further assistance, please contact me.

SPECIES

Canine

Sebastian Jawinski, German Board Certified Vet Specialist in Diagnostic Imaging
Sebastian.Jawinski@sonopath.com

BREED

Irish Setter

SEX

FS

AGE

9 Years

INTERPRETED BY

Sebastian Jawinski,
German Board
Certified Vet
Specialist in
Diagnostic Imaging

HOSPITAL NAME

Suncoast Veterinary

REFERRING VET

Byron Young

INVOICE

47183

DATE

8-27-21