



PATIENT PRESENTING CLINICAL SIGNS

Dana Arroyo
SPECIES History: patient came in bc of vomiting after eating notice slight jaundice of the sclera recommended hospitalization antiemetics and fluids with abdominal ultrasound asap addendum - abdominal ultrasound gallbladder has some debris but does not seem to be inflamed or blocked the rest of the abdominal ultrasound preliminary report is ok recommended abdominal CT scan tomorrow with contrast

Canine

Abnormal PE/Chem/CBC/UA Results: CBC --- WNL CHEM --- total bilirubin is high --electrolyte na cl high

BREED

Toy Poodle

COMPUTED TOMOGRAPHIC STUDY OF THE ABDOMEN

Liver and spleen show normal findings in terms of size, surface, shape and contrast behavior. Gallbladder is inconspicuous without evidence of cholestasis presenting small amounts of hyperdense sludge. The common bile duct is considered to be normal.

SEX

Spayed Female

Pancreas presents normal size and shape with a smooth surface. The peripancreatic fat tissue and omentum are inconspicuous.

AGE

13 Years

Kidneys are bilaterally symmetrical with small cortical hypodense wedge-shaped areas after contrast. Ureters, urinary bladder, trigonum and urethra are presented as expected. Adrenal glands are in normal limits.

INTERPRETED BY

Sebastian Jawinski,
 German Board
 Certified Vet Specialist
 in Diagnostic Imaging

The stomach is predominantly empty with some structured content with small gas pockets. Gastric rugae are prominent. Pylorus and duodenum are inconspicuous. The small intestine shows mild fluid-filled loops. The transverse and descendent colon present marked filling with radiopaque, mottled-mineralized ingesta which can be traced caudally up to the level of the sphincter. There are no signs of an obstructive or functional ileus.

HOSPITAL NAME

Veterinary Image
 Center

Portal lymph nodes appear enlarged but show regular shape and periphery. All other abdominal lymph nodes and abdominal vessels have no particular findings. Signs of peritoneal/retroperitoneal effusion or free gas are not recognized.

REFERRING VET

Dr. F. Ortiz Vidal

COMPUTED TOMOGRAPHIC DIAGNOSIS

- Questionable gastric content, prominent gastric rugae
- Portal lymphadenomegaly
- Well-filled colon
- Degenerative age-appropriate changes of both kidneys

INVOICE

12750

INTERPRETATION OF THE FINDINGS & FURTHER RECOMMENDATIONS

DATE

8/25/21



PATIENT

Dana Arroyo

The questionable structured gastric content in the area of the pyloric antrum may represent foreign material not able to pass the pylorus. Gastritis is likely. Pancreas and the gastric periphery are inconspicuous. Follow-up radiographs and/or a barium contrast study could be performed to monitor gastric emptying.

SPECIES

Canine

There are no signs of an obstructive ileus, ingesta of the colon will pass the sphincter.

The enlargement of the portal lymph nodes is consistent with mild reactive-inflammatory lymphadenopathy and unspecific. Signs of a severe inflammatory or even neoplastic process are missing.

BREED

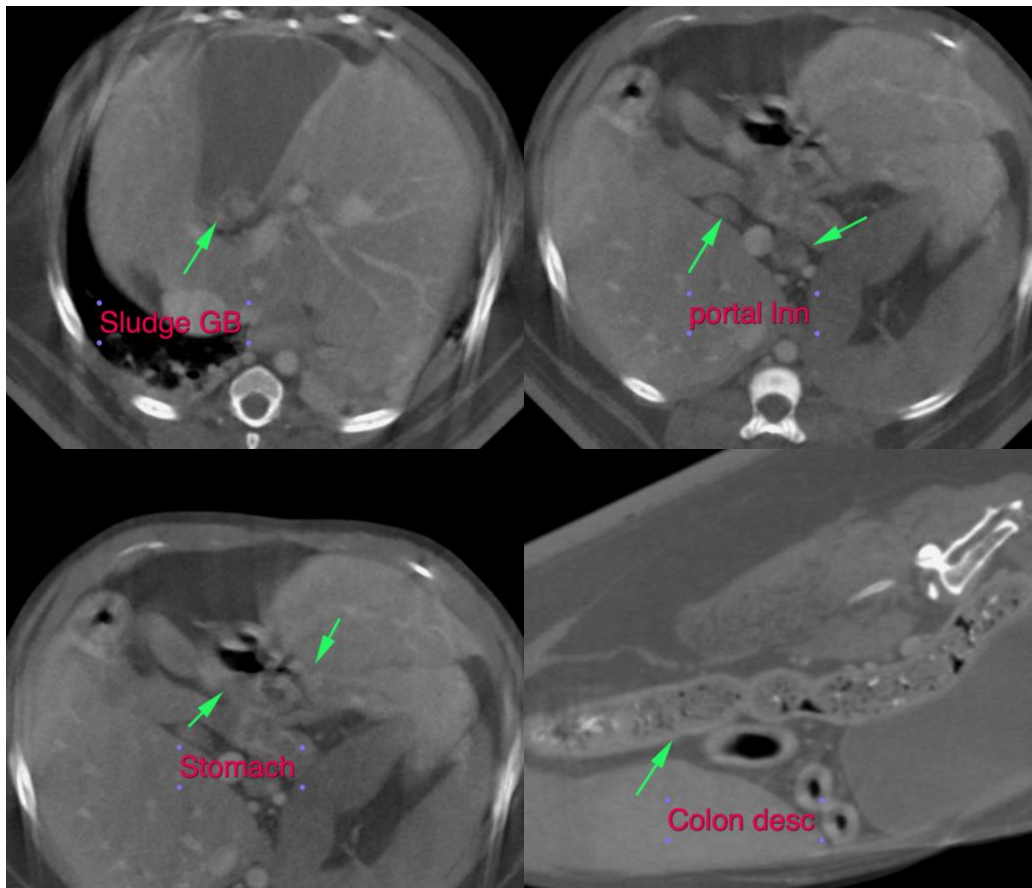
Toy Poodle

SEX

Spayed Female

AGE

13 Years



INTERPRETED BY

Sebastian Jawinski,
German Board
Certified Vet Specialist
in Diagnostic Imaging

HOSPITAL NAME

Veterinary Image
Center

REFERRING VET

Dr. F. Ortiz Vidal

The information and recommendations provided are based on the images presented by the referring veterinarian. No evaluation can be communicated regarding pathology that was not visible in the image/video clips provided.

INVOICE

12750

Thank you for this referral. If the clinical or image interpretation does not parallel your findings or if I can be of any further assistance please contact me.

DATE

8/25/21



PATIENT

Sebastian Jawinski, German Board Certified Vet Specialist in Diagnostic Imaging
info@sonopath.com

Dana Arroyo

SPECIES

Canine

BREED

Toy Poodle

SEX

Spayed Female

AGE

13 Years

INTERPRETED BY

Sebastian Jawinski,
German Board
Certified Vet Specialist
in Diagnostic Imaging

HOSPITAL NAME

Veterinary Image
Center

REFERRING VET

Dr. F. Ortiz Vidal

INVOICE

12750

DATE

8/25/21