



PATIENT	PRESENTING CLINICAL SIGNS
Krum Victor Taylor	Head tilt and pyrexia of unknown origin on and off since June. Had medications slight improvement , had severe otitis externa when was a kitten
SPECIES	COMPUTED TOMOGRAPHY OF THE HEAD
Feline	Pre/post contrast studies provided for review.
BREED	COMPUTED TOMOGRAPHIC FINDINGS
Russian Blue	The interhemispheric gap is in the midline with no evidence of a mass effect. As far as can be assessed, there are regular cortical gyri in the cerebral and cerebellar region with a symmetrical ventricular system. Brain stem and cerebellum are inconspicuous. Pituitary gland is within normal limits.
SEX	
Male Neutered	Bony structures of skull and the skull foramina of the cranial nerves are laterally symmetrical and inconspicuous.
AGE	
5 Months	Both tympanic bullae are completely ventilated with a regular tympanic bulla wall. External ear canals are ventilated in all sections, walls of the external ear canals, the adjacent temporomandibular joints and the nasopharyngeal meatus have no particular findings.
INTERPRETED BY	
Sebastian Jawinski, German Board Certified Vet Specialist in Diagnostic Imaging	Frontal sinuses and the orbital contents are laterally symmetrical without evidence of a retrobulbar lesion. Nasal cavities are ventilated regularly. Conches look normal as well as the maxillary/mandibular teeth.
HOSPITAL NAME	
Myerscough Veterinary Group	Post contrast images show no pathological enhancement. Soft tissues of the head and neck are symmetrical and of homogeneous density, especially the medial retropharyngeal lymph nodes.
REFERRING VET	COMPUTED TOMOGRAPHIC DIAGNOSIS
Alice Tighe	<ul style="list-style-type: none">Normal CT findings of the head
INVOICE	INTERPRETATION OF THE FINDINGS & FURTHER RECOMMENDATIONS
47111	CT findings show no signs of a neoplastic or an inflammatory process. Intraaxial lesions such as infarcts, small edema or low-grade neoplasia are difficult to recognize in CT and therefore not ruled out completely.
DATE	
8-24-21	



PATIENT

Krum Victor Taylor

SPECIES

Feline

BREED

Russian Blue

SEX

Male Neutered

AGE

5 Months

INTERPRETED BY

Sebastian Jawinski,
German Board
Certified Vet
Specialist in
Diagnostic Imaging

HOSPITAL NAME

Myerscough
Veterinary Group

REFERRING VET

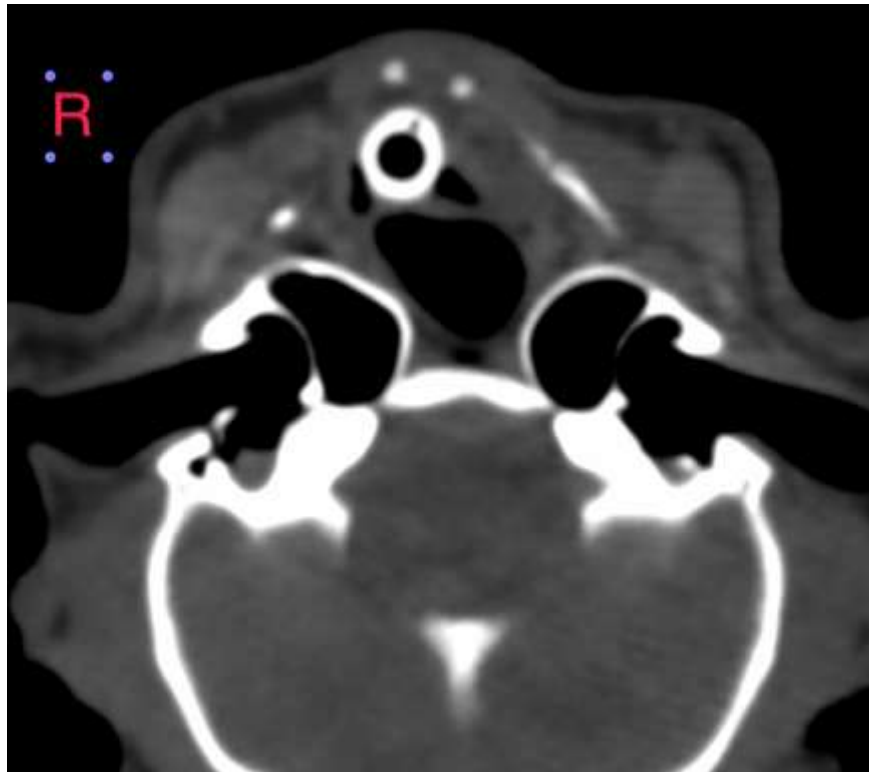
Alice Tighe

INVOICE

47111

DATE

8-24-21



The information and recommendations provided are based on the images presented by the referring veterinarian. No evaluation can be communicated regarding pathology that was not visible in the image/video clips provided.

Thank you for this referral. If the clinical or image interpretation does not parallel your findings or if I can be of any further assistance, please contact me.

Sebastian Jawinski, German Board Certified Vet Specialist in Diagnostic Imaging
Sebastian.Jawinski@sonopath.com