



PATIENT PRESENTING CLINICAL SIGNS

Juve Villani History: Juve's clinical signs were first noted around end of June and include low head carriage, weakness and lethargy. The signs were noted acutely after he fell backwards from his couch about 2 months ago. From the last exam, he has not been showing signs of improvement. He continues to be lethargic, has a hunched a back and still whimpers in pain when other dogs bump into his neck. He also hesitates to shake his head and continues to have a low head carriage.

SPECIES

Canine

MAGNETIC RESONANCE IMAGING STUDY OF THE SPINE & HEAD/NECK

BREED

Spine:

Miniature Pinscher

Presented bony structures of the spine are unremarkable with an inconspicuous harmonic atlanto-occipital, and -axial transition. The medullary bone of C4 appears mildly hyperintense in its caudal part in the T2- and T1- weighted images. All other vertebral bodies present a regular signal in all sequences, there are no signs of bone edema recognized. The spinal cord is located centrally and is homogeneous and shows no compressive lesion.

SEX

Neutered Male

AGE

11 Years

The intervertebral discs show loss of signal with subtle protrusions but without evidence of a relevant spinal cord compression.

Paravertebral soft tissues are bilaterally symmetrical und appear regular.

INTERPRETED BY

Head/Neck:

Sebastian Jawinski,
German Board
Certified Vet Specialist
in Diagnostic Imaging

There is a rounded to amorphous mass of 1.83 x 2.06 cm recognized at the level of the right entrance to the larynx protruding into the oral cavity caudal to the tongue with subtle deviation of the larynx to the left. Inhomogenous contrast uptake is recognized. The peripheral soft tissue presents mild edema. The right medial retropharyngeal lymph node is significantly enlarged measuring 4.0 x 2.0 cm again with a reactive, mildly edematous peripheral soft tissue. Contrast images show a hypodense center of the lymph node. The thoracic inlet is inconspicuous as far as can be assessed.

HOSPITAL NAME

Animal Health
Partners

MRI DIAGNOSIS

REFERRING VET

Dr. Kilburn

- Neoplasia of the right tonsil
- Local infiltration of the adjacent tissue with regional metastasis of the right medial retropharyngeal lymph node
- Degenerative and age-appropriate findings of the cervical spine (fatty infiltration C4)

INVOICE

12726

INTERPRETATION OF THE FINDINGS & FURTHER RECOMMENDATIONS

MRI findings show an aggressive and infiltrative lesion most probably of the right tonsil. Tonsil carcinoma is a common differential diagnosis. I would exclude inflammatory lesions. I assume this to be the relevant finding causing the reported clinical symptoms. The enlargement of the lymph node

DATE

8/24/21



PATIENT

Juve Villani

and the reactive periphery indicate an active most likely painful process. Findings of the spine are inconspicuous without signs of a compressive/spinal cord lesion. Biopsy/FNA are needed for a final diagnosis. Complementary radiographs/CT of the chest are recommended.

SPECIES

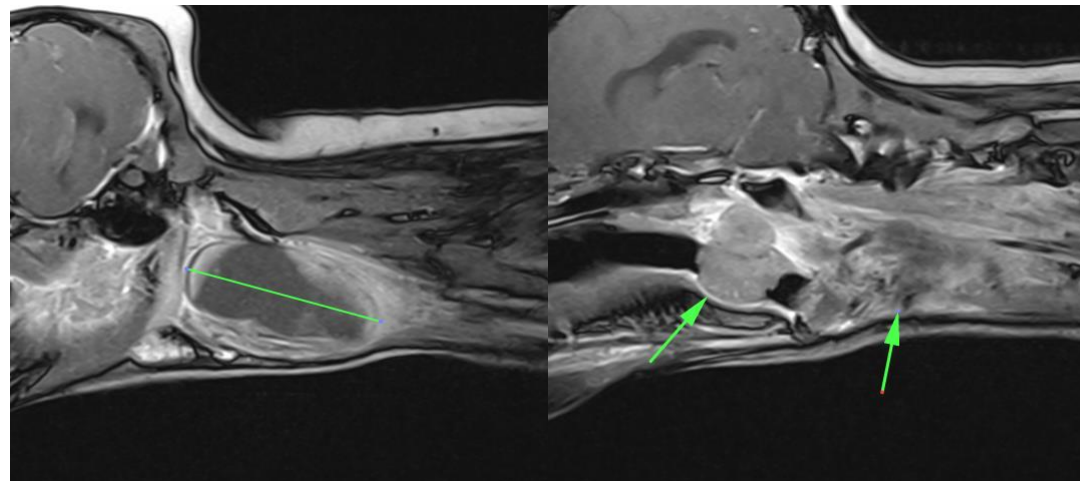
Canine

BREED

Miniature Pinscher

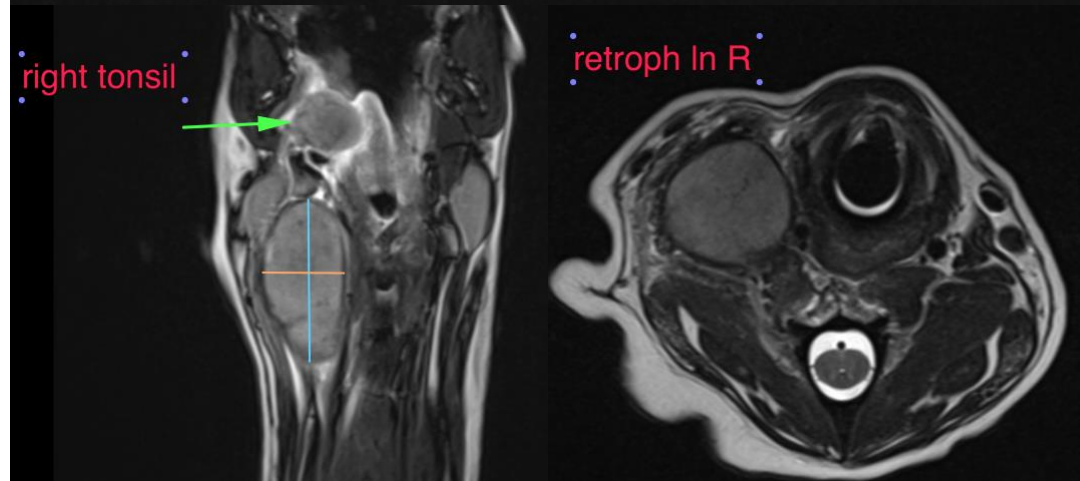
SEX

Neutered Male



AGE

11 Years



INTERPRETED BY

Sebastian Jawinski,
German Board
Certified Vet Specialist
in Diagnostic Imaging

HOSPITAL NAME

Animal Health
Partners

REFERRING VET

Dr. Kilburn

INVOICE

12726

DATE

8/24/21



PATIENT

Juve Villani

SPECIES

Canine

BREED

Miniature Pinscher

SEX

Neutered Male

AGE

11 Years

INTERPRETED BY

Sebastian Jawinski,
German Board
Certified Vet Specialist
in Diagnostic Imaging

HOSPITAL NAME

Animal Health
Partners

REFERRING VET

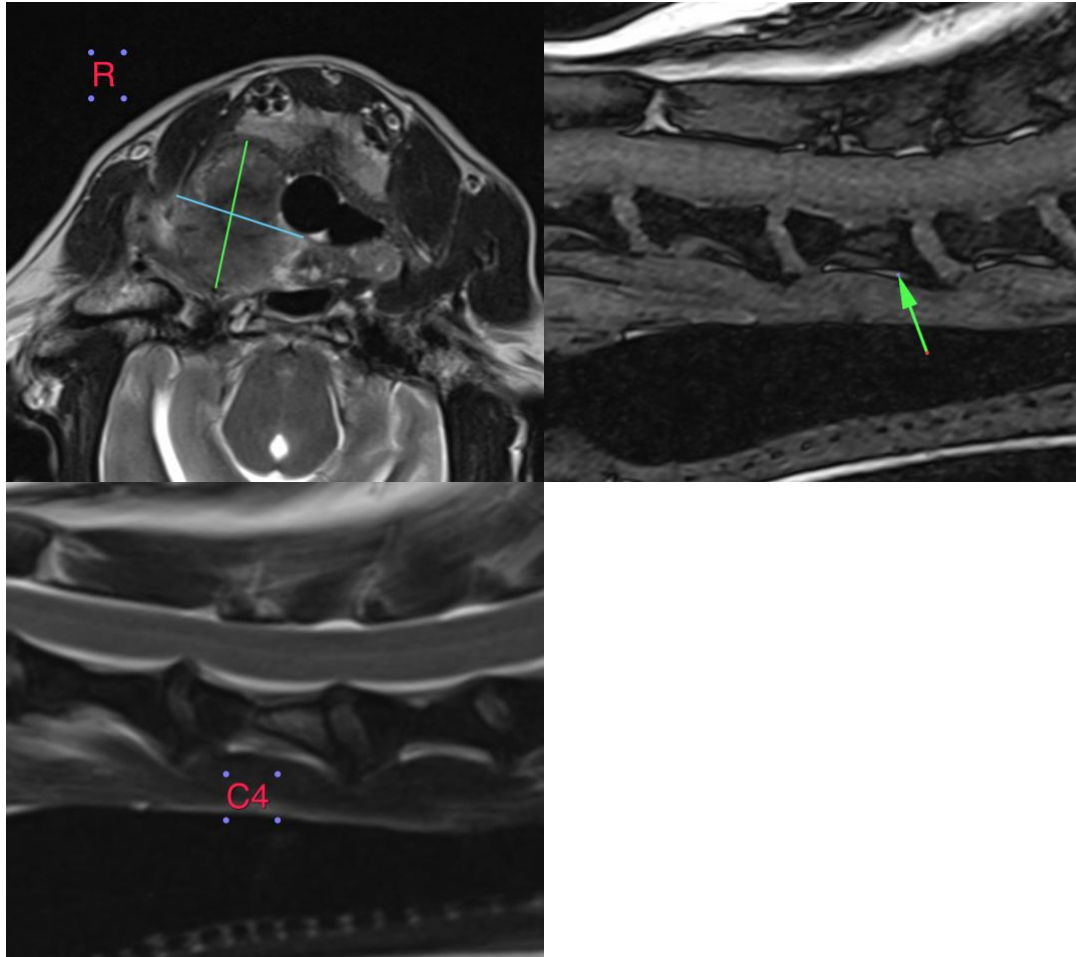
Dr. Kilburn

INVOICE

12726

DATE

8/24/21



The information and recommendations provided are based on the images presented by the referring veterinarian. No evaluation can be communicated regarding pathology that was not visible in the image/video clips provided.

Thank you for this referral. If the clinical or image interpretation does not parallel your findings or if I can be of any further assistance please contact me.

Sebastian Jawinski, German Board Certified Vet Specialist in Diagnostic Imaging
info@sonopath.com