

**PATIENT**Mattie 470D  
Martinez**PRESENTING CLINICAL SIGNS**

Recent progression in symptoms -- previous CT and histopath attached. Owners have declined re-biopsy but elected re-imaging with progression of symptoms - now with hemorrhagic discharge unless on daily steroid use.

Abnormal PE/Chem/CBC/UA Results: No changes with recent labs completed

**SPECIES**

Canine

**COMPUTED TOMOGRAPHY OF THE HEAD**

Pre/post contrast studies provided for review.

**BREED**

Schnauzer

**COMPUTED TOMOGRAPHIC FINDINGS**

The neurocranium shows normal findings. Bony structures of skull and the skull foramina of the cranial nerves are laterally symmetrical and inconspicuous. Both tympanic bullae are completely ventilated with a regular tympanic bulla wall. External ear canals are ventilated in all sections, walls of the external ear canals, the adjacent temporomandibular joints and the nasopharyngeal meatus have no particular findings.

**SEX**

FS

**AGE**

11 Years, 3 Months

There is severe shortening and destruction of the conches noted predominantly affecting the concha nasalis ventralis on both sides. The residual mucous membranes show significant thickening with partial stenosis of the nasal exits. The septum appears intact, but the palatine bone bilaterally presents erosion and focal lysis at multiple locations.

**INTERPRETED BY**

Sebastian Jawinski,  
German Board  
Certified Vet  
Specialist in  
Diagnostic Imaging

Post contrast images show marked enhancement of the mucous membranes. The left medial retropharyngeal lymph node still shows mild enlargement but appears regular in shape and contrast behavior.

The esophagus still is dilated, and fluid filled.

**HOSPITAL NAME**Gentle Doctor Animal  
Hospital**COMPUTED TOMOGRAPHIC DIAGNOSIS**

- Severe, bilateral signs of a chronic, erosive and active rhinitis
- Mild left sided retropharyngeal lymphadenitis
- Dilation of the esophagus

**REFERRING VET**

Pete Bashara, DVM

**INTERPRETATION OF THE FINDINGS & FURTHER RECOMMENDATIONS**

There is marked progression of the CT findings present compared to the previous CT from 9/15/19.

**INVOICE**

47038

Compelling signs of a neoplastic process are missing. However, neoplasia cannot be fully excluded. I do not suspect the latter. Appearance of the rhinitis is commonly seen with chronic infection (mycosis?), or foreign body triggered inflammation. Lympho-plasma cellular inflammation may have been an initial trigger, the current CT findings however are not typical.

**DATE**

8-19-21



**PATIENT**

Mattie 470D  
Martinez

Please rule out regurgitation/vomiting since the erosive changes could be due to gastric acid (megaesophagus/chronic esophagitis?).

**SPECIES**

Canine

**BREED**

Schnauzer

**SEX**

FS

**AGE**

11 Years, 3 Months

**INTERPRETED BY**

Sebastian Jawinski,  
German Board  
Certified Vet  
Specialist in  
Diagnostic Imaging

**HOSPITAL NAME**

Gentle Doctor Animal  
Hospital

**REFERRING VET**

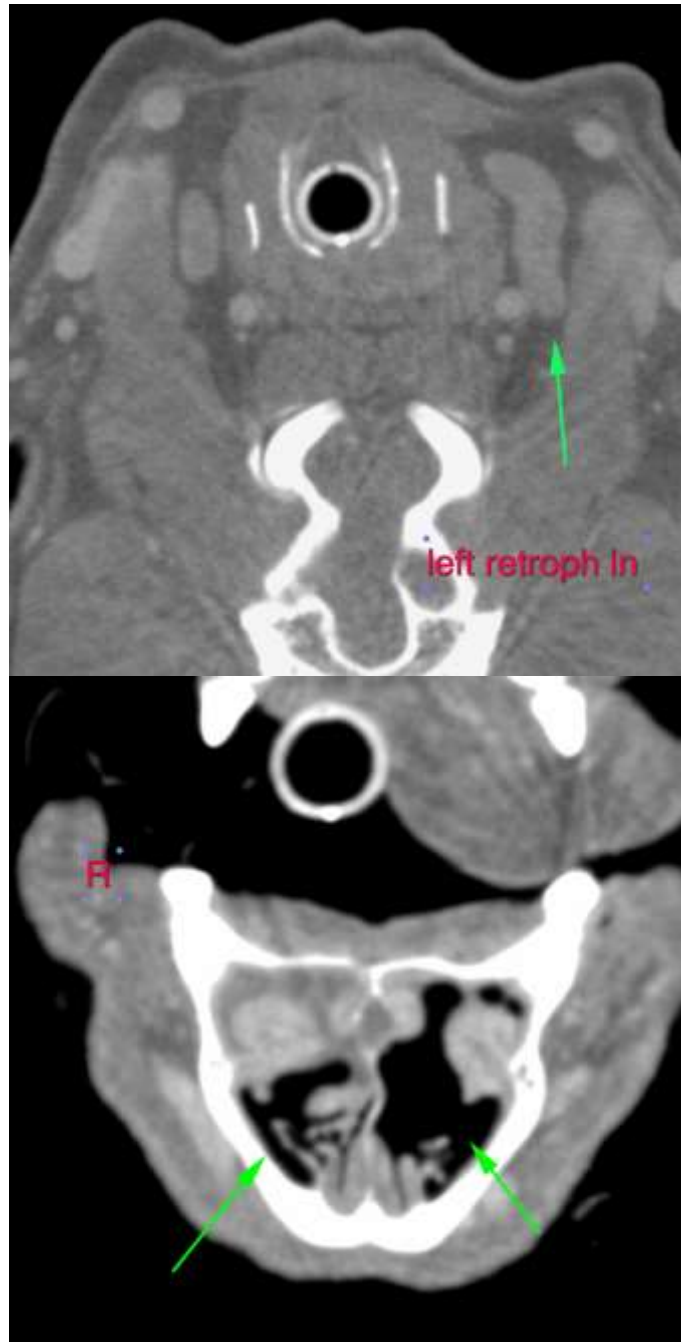
Pete Bashara, DVM

**INVOICE**

47038

**DATE**

8-19-21





**PATIENT**

Mattie 470D  
Martinez

**SPECIES**

Canine

**BREED**

Schnauzer

**SEX**

FS

**AGE**

11 Years, 3 Months

**INTERPRETED BY**

Sebastian Jawinski,  
German Board  
Certified Vet  
Specialist in  
Diagnostic Imaging

**HOSPITAL NAME**

Gentle Doctor Animal  
Hospital

**REFERRING VET**

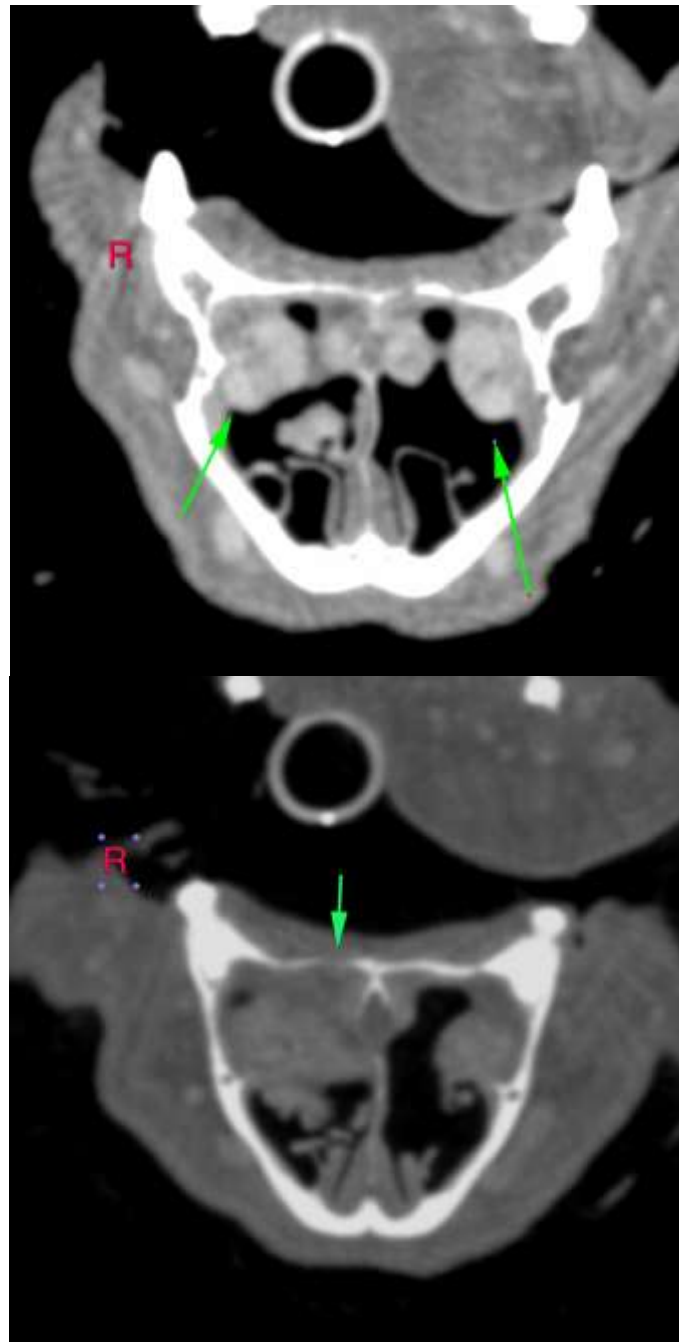
Pete Bashara, DVM

**INVOICE**

47038

**DATE**

8-19-21





**PATIENT**

Mattie 470D  
Martinez

**SPECIES**

Canine

**BREED**

Schnauzer

**SEX**

FS

**AGE**

11 Years, 3 Months

**INTERPRETED BY**

Sebastian Jawinski,  
German Board  
Certified Vet  
Specialist in  
Diagnostic Imaging

**HOSPITAL NAME**

Gentle Doctor Animal  
Hospital

**REFERRING VET**

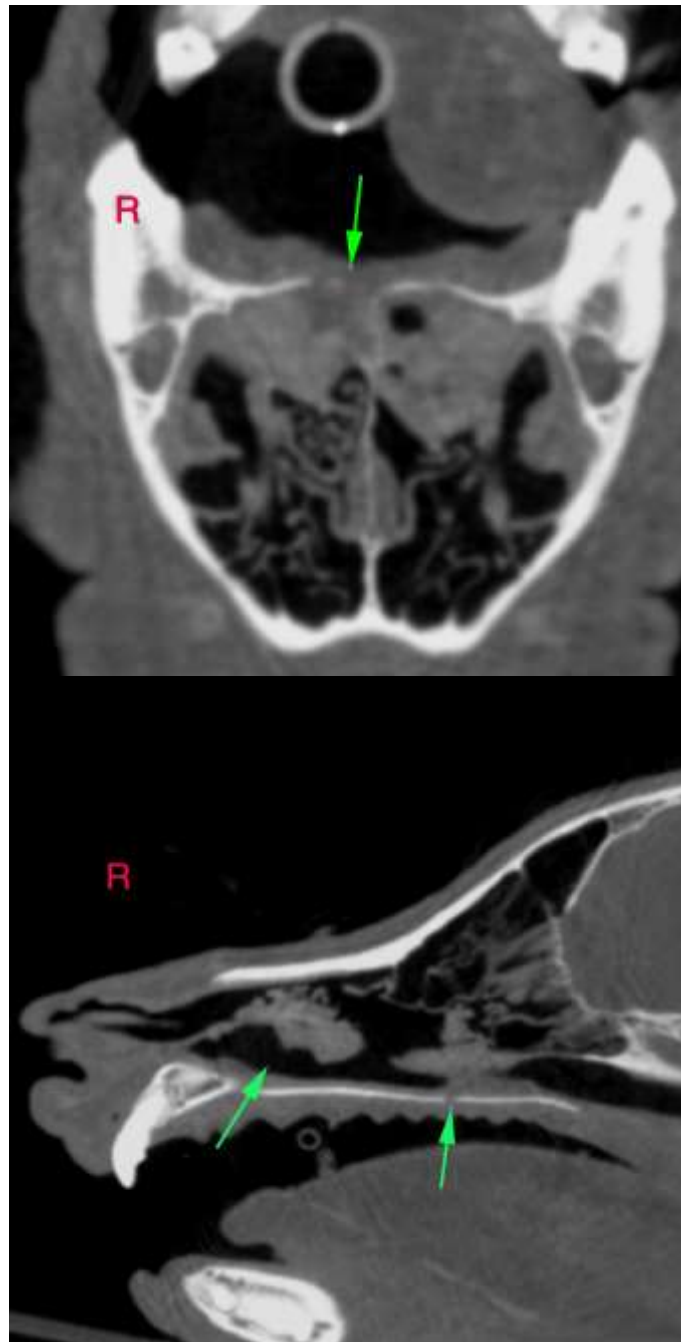
Pete Bashara, DVM

**INVOICE**

47038

**DATE**

8-19-21





**PATIENT**

Mattie 470D  
Martinez

**SPECIES**

Canine

**BREED**

Schnauzer

**SEX**

FS

**AGE**

11 Years, 3 Months

**INTERPRETED BY**

Sebastian Jawinski,  
German Board  
Certified Vet  
Specialist in  
Diagnostic Imaging

**HOSPITAL NAME**

Gentle Doctor Animal  
Hospital

**REFERRING VET**

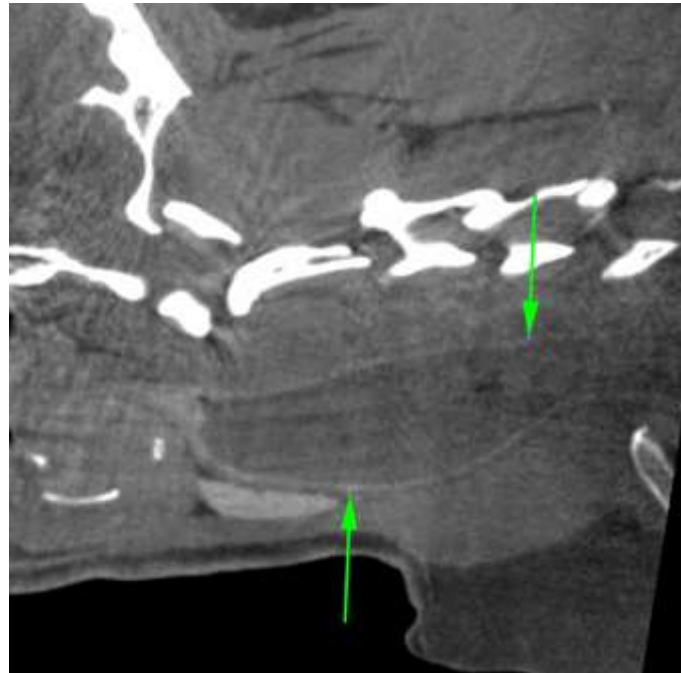
Pete Bashara, DVM

**INVOICE**

47038

**DATE**

8-19-21



The information and recommendations provided are based on the images presented by the referring veterinarian. No evaluation can be communicated regarding pathology that was not visible in the image/video clips provided.

Thank you for this referral. If the clinical or image interpretation does not parallel your findings or if I can be of any further assistance, please contact me.

**Sebastian Jawinski, German Board Certified Vet Specialist in Diagnostic Imaging**  
Sebastian.Jawinski@sonopath.com