



**PATIENT PRESENTING CLINICAL SIGNS**

**Cosmo Mussina** History: Cat came for a sedated grooming, pre-anesthetic radiographs show abnormal heart/lungs. Cat is prone to coughing up hairballs.

**SPECIES RADIOGRAPHIC STUDY OF THE THORAX**

**Feline** The surrounding bony structures are within normal limits. The extra-thoracic soft tissues are homogenous and show marked fat storage.

**BREED** The cranial margin of the cardiac silhouette is ill-defined in the lateral projections, the vd view is inconspicuous and shows no evidence of chamber enlargement. The vertebral heart score equals 7.8. The pulmonary vessels are normal in size and taper appropriately in the periphery.

**SEX** The lung density appears hyperlucent due to inspiratory radiographs. There is no evidence of nodular or focal lesions recognized. The lungs present multiple bronchiectasis.

**Male** The trachea is unremarkable in diameter and course. Luminal outline of the trachea is smooth.

**AGE** The mediastinum presents expected soft tissue density, there is no evidence of tracheobronchial, cranial mediastinal or sternal lymphadenopathy. No mediastinal shift is seen. The esophagus is not visible and considered to be normal. The diaphragm is unremarkable, no signs of pleural effusion.

8 Years

**RADIOGRAPHIC DIAGNOSIS**

**INTERPRETED BY**

Sebastian Jawinski,  
German Board  
Certified Vet Specialist  
in Diagnostic Imaging

- Peripheral bronchiectasis
- Obesity with pericardial fat storage

**INTERPRETATION OF THE FINDINGS & FURTHER RECOMMENDATIONS**

**HOSPITAL NAME**

Loving Care VH

The mildly hyperinflated lungs and the detected bronchiectasis most likely represent chronic findings as commonly seen with bronchitis/mild bronchopneumonia due infectious disease or allergic issues/feline asthma. Their clinical relevance is questionable. The superimposing density and the ill-defined margination of the cardiac silhouette most probably are caused by pericardial fat storage.

**REFERRING VET**

Kristie Steele

Signs of a florid inflammatory or even neoplastic process are missing.

**INVOICE**

12569

**DATE**

8/17/21



**PATIENT**

Cosmo Mussina

**SPECIES**

Feline

**BREED**

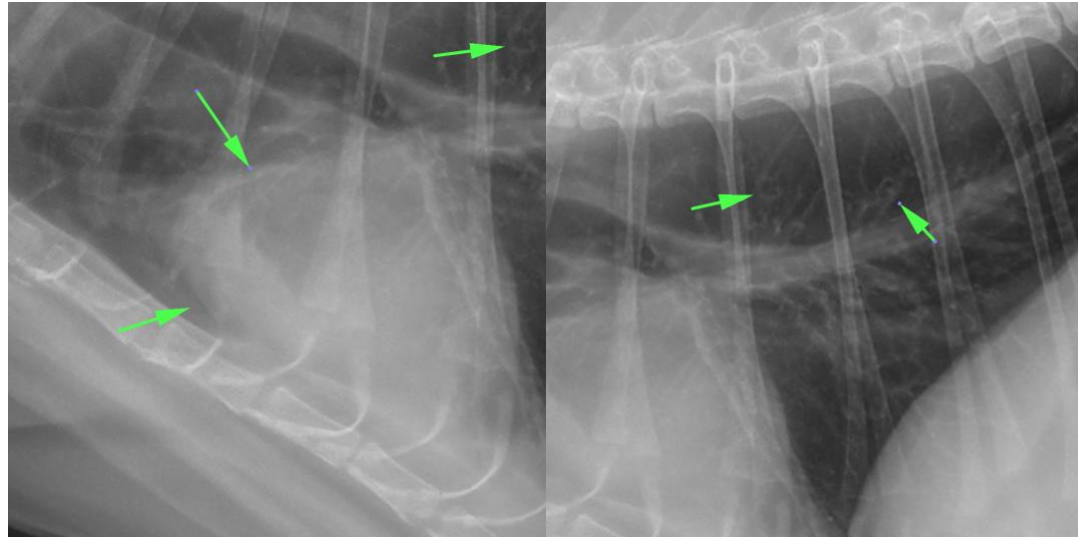
Ragdoll

**SEX**

Male

**AGE**

8 Years



**The information and recommendations provided are based on the images presented by the referring veterinarian. No evaluation can be communicated regarding pathology that was not visible in the image/video clips provided.**

Thank you for this referral. If the clinical or image interpretation does not parallel your findings or if I can be of any further assistance please contact me.

**INTERPRETED BY**

**Sebastian Jawinski**, German Board Certified Vet Specialist in Diagnostic Imaging  
info@sonopath.com

Sebastian Jawinski,  
German Board  
Certified Vet Specialist  
in Diagnostic Imaging

**HOSPITAL NAME**

Loving Care VH

**REFERRING VET**

Kristie Steele

**INVOICE**

12569

**DATE**

8/17/21