



PATIENT PRESENTING CLINICAL SIGNS

Lucky Camacho Problem urinating and Hematuria.

COMPUTED TOMOGRAPHY OF THE THORAX & ABDOMEN

SPECIES Pre/post contrast studies provided for review.

Canine **COMPUTED TOMOGRAPHIC FINDINGS**

Chest:

BREED Yorkshire The lungs are regularly ventilated with close contact to the inner thoracic wall on all sides. There is no evidence of pleural thickening, fluid accumulation or free pleural gas. Pulmonary density is within normal limits, there is no evidence of focal or nodular pulmonary lesions.

SEX IM The mediastinum is regular in width and density. Mediastinal (sternal, tracheal-, bronchial) lymph nodes are considered to be normal. The thoracic trachea and esophagus present as expected. The heart is inconspicuous as far as can be assessed with CT.

AGE The diaphragm appears normal.

9 Years Abdomen:

INTERPRETED BY The liver shows normal findings in terms of size, surface, shape and contrast behavior. The gallbladder is inconspicuous without evidence of cholestasis. The common bile duct is considered to be normal.

Sebastian Jawinski,
German Board
Certified Vet Specialist
in Diagnostic Imaging

The pancreas presents normal size and shape with a smooth surface. The peripancreatic fat tissue and omentum are inconspicuous.

The spleen shows normal findings in terms of size, surface, shape and contrast behavior.

HOSPITAL NAME Mobile Pet Imaging CFL The right kidney presents tiny, calcified spots. Apart from that, the kidneys unremarkable and symmetrical measuring 4.02 cm (right) and 4.28 (left) in length. Images post contrast are inconspicuous with a regular pelvic excretion and filling of the ureters and the urinary bladder. The latter is highly filled without signs of cystic calculi.

REFERRING VET Xavier Meaux The prostate is markedly enlarged presenting a bilobular shape (3.8 x 4.0 x 3.1 cm) and multiple cysts. There is an inhomogeneous contrast uptake noted. The periphery is unremarkable. The prostatic parts of the urethra and the post-prostatic urethra appear subjectively thickened with a strong contrast enhancement. Both testicles have no particular findings.

INVOICE Adrenal glands are in normal limits.

59275

As far as can be assessed, the stomach and all parts of intestine are regularly presented without any indication of a wall thickening or a mass. There are no signs of an obstructive or functional ileus.

DATE

7-11-23



PATIENT Abdominal lymph nodes and abdominal vessels are normal. Signs of peritoneal/retroperitoneal effusion or free gas are not recognized.
Lucky Camacho

COMPUTED TOMOGRAPHIC DIAGNOSIS

- SPECIES**
- Severe, benign hyperplasia of the prostate with multiple cysts with questionable urethritis
 - Mild nephrocalcinosis on the right
 - Normal findings of the thorax
- Canine

BREED **INTERPRETATION OF THE FINDINGS & FURTHER RECOMMENDATIONS**

Yorkshire
The CT findings present an inflammatory process including the prostate and the urethra (prostatitis/urethritis). These would match with the reported clinical symptoms. Signs of an abscess formation and/or a perifocal peritonitis are currently not recognized. Secondary bacterial infection is common. Therapy should achieve prostatic involution (castration, hormone therapy). Non-radiopaque calculi cannot be fully excluded. An obstructive issue not detected.

SEX

IM

The mild calcifications found in the right kidney are likely incidental. Neoplasia is not suspected. Sonographic follow ups are recommended.

AGE

9 Years

INTERPRETED BY

Sebastian Jawinski,
German Board
Certified Vet Specialist
in Diagnostic Imaging

HOSPITAL NAME

Mobile Pet Imaging
CFL

REFERRING VET

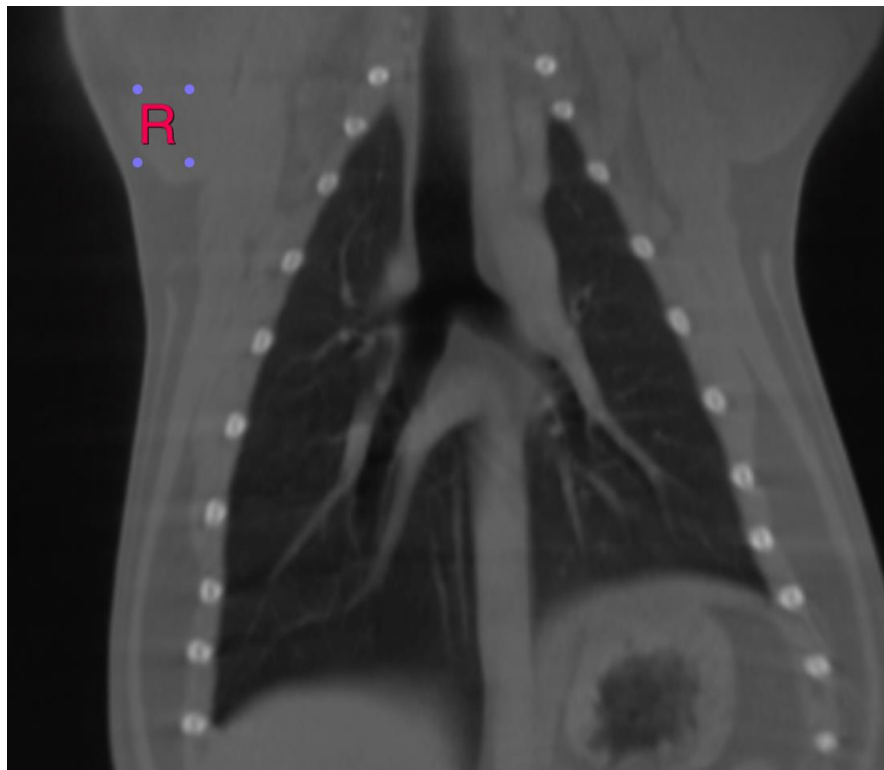
Xavier Meaux

INVOICE

59275

DATE

7-11-23





PATIENT

Lucky Camacho

SPECIES

Canine

BREED

Yorkshire

SEX

IM

AGE

9 Years

INTERPRETED BY

Sebastian Jawinski,
German Board
Certified Vet Specialist
in Diagnostic Imaging

HOSPITAL NAME

Mobile Pet Imaging
CFL

REFERRING VET

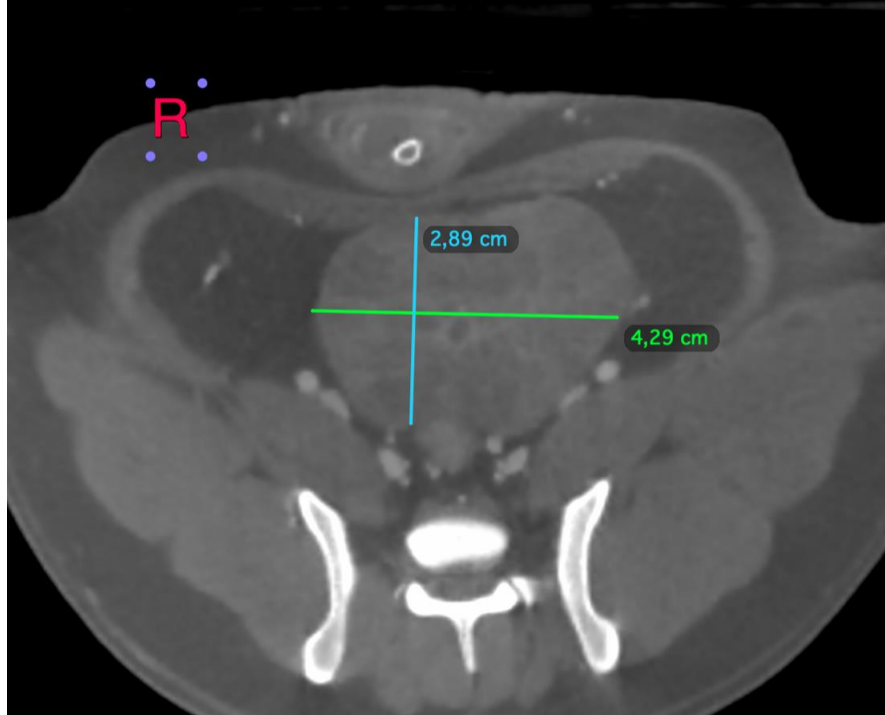
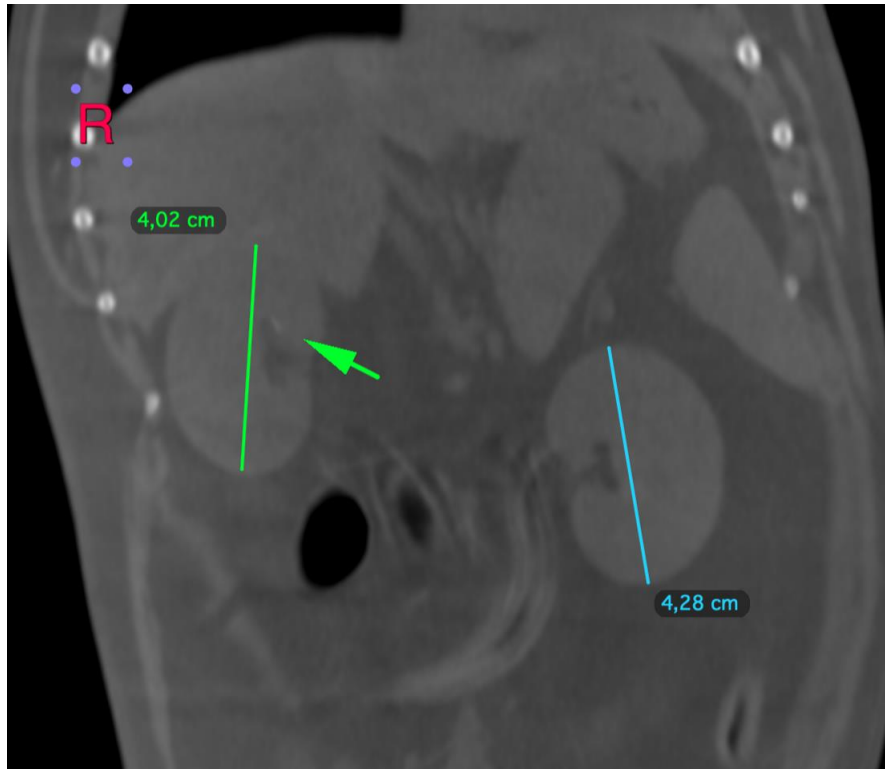
Xavier Meaux

INVOICE

59275

DATE

7-11-23





PATIENT

Lucky Camacho

SPECIES

Canine

BREED

Yorkshire

SEX

IM

AGE

9 Years

INTERPRETED BY

Sebastian Jawinski,
German Board
Certified Vet Specialist
in Diagnostic Imaging

HOSPITAL NAME

Mobile Pet Imaging
CFL

REFERRING VET

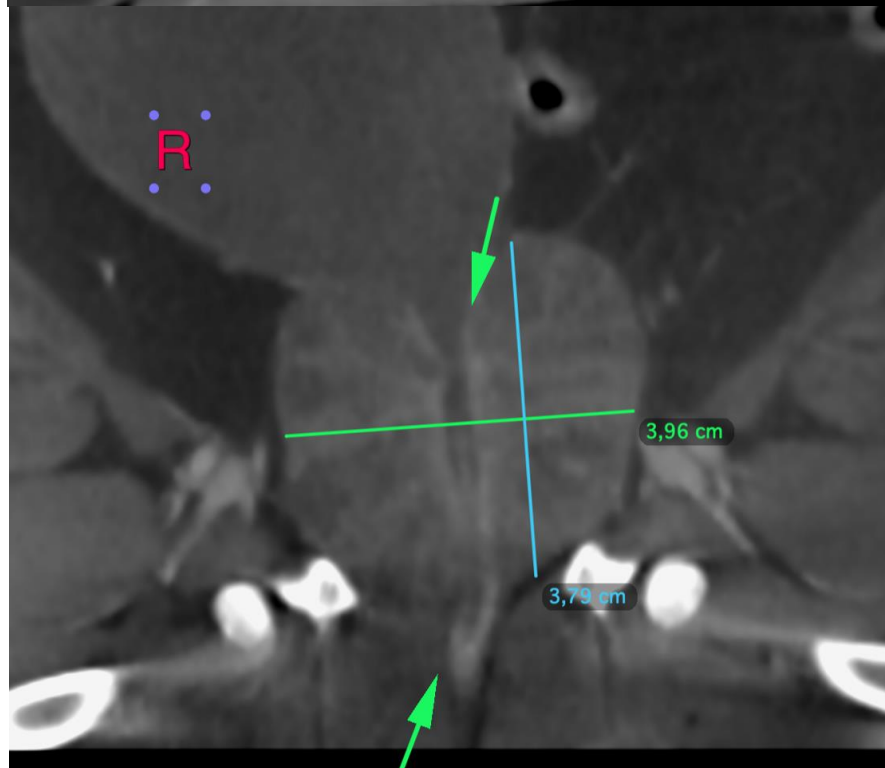
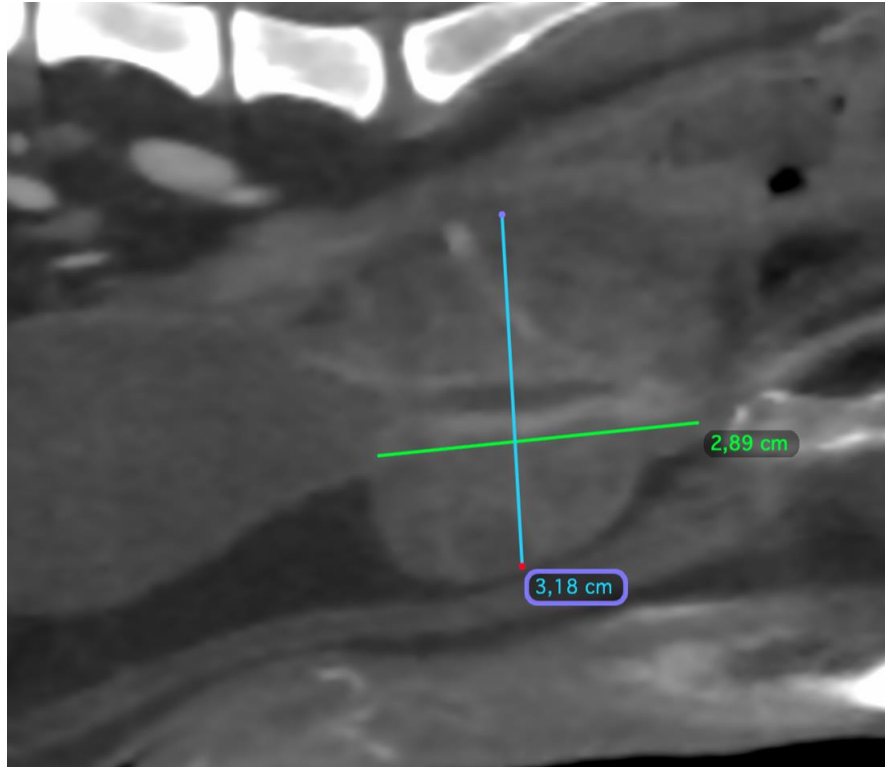
Xavier Meaux

INVOICE

59275

DATE

7-11-23





PATIENT

Lucky Camacho

SPECIES

Canine

BREED

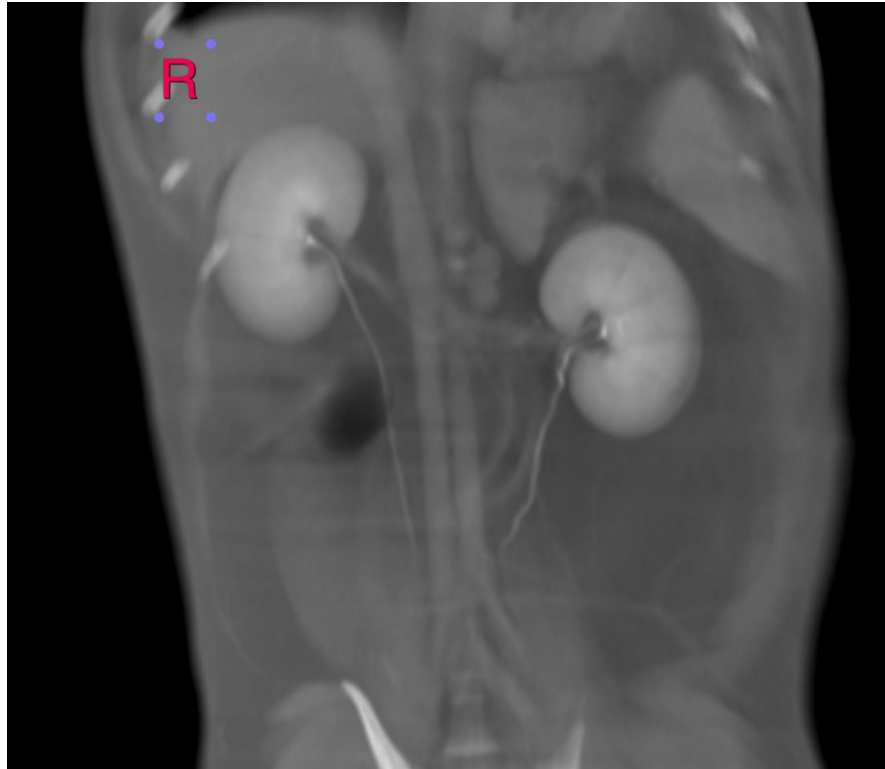Yorkshire

SEX

IM

AGE

9 Years



INTERPRETED BY

Sebastian Jawinski,
German Board
Certified Vet Specialist
in Diagnostic Imaging

The information and recommendations provided are based on the images presented by the referring veterinarian/sonographer. No evaluation can be communicated regarding pathology that was not visible in the image/video clips provided.

HOSPITAL NAME

Mobile Pet Imaging
CFL

Thank you for this referral. If the clinical or image interpretation does not parallel your findings or if I can be of any further assistance, please contact me.

Sebastian Jawinski, German Board Certified Vet Specialist in Diagnostic Imaging
info@sonopath.com

REFERRING VET

Xavier Meaux

INVOICE

59275

DATE

7-11-23