



**PATIENT PRESENTING CLINICAL SIGNS**

Elmo Pritcher bleeding from left nostral for about a week. bloodwork normal.

**SPECIES COMPUTED TOMOGRAPHY OF THE HEAD**

Canine

Pre/post contrast studies provided for review.

**BREED**

Lab Mix

**COMPUTED TOMOGRAPHIC FINDINGS**

The left nasal cavity shows a focal fluid accumulation affecting the caudal part of the ventral nasal concha and the ventral nasal meatus showing some mineralized spots. The adjacent bony structures, the nasal septum and turbinate appear normal without relevant osteolysis or atrophy.

**SEX**

Frontal sinuses and the orbital contents are laterally symmetrical without evidence of a retrobulbar lesion. The maxillary/mandibular teeth have no particular findings.

**MN**

The neurocranium shows normal findings. Bony structures of the skull and the skull foramina of the cranial nerves are laterally symmetrical and inconspicuous.

**AGE**

11 Years

Post contrast images show no pathological enhancement. Soft tissues of the head and neck are symmetrical and of homogeneous density, especially the mandibular and medial retropharyngeal lymph nodes.

**INTERPRETED BY**

Sebastian Jawinski,  
German Board  
Certified Vet  
Specialist in  
Diagnostic Imaging

**COMPUTED TOMOGRAPHIC DIAGNOSIS**

- Local fluid accumulation left ventral nasal cavity with questionable foreign material

**INTERPRETATION OF THE FINDINGS & FURTHER RECOMMENDATIONS**

**HOSPITAL NAME**

Animal Medical  
Center of Mt.  
Pleasant

The unilateral appearance and absence of aggressive/lytic changes are suspicious for a foreign body induced inflammation. Foreign material at least could have been an initial cause. Secondary bacterial infection is common. Neoplasia is not suspected. Rhinoscopy could be the next diagnostic and therapeutic step.

**REFERRING VET**

Dr. Steven Epstein

**INVOICE**

59274

**DATE**

7-11-23



**PATIENT**

Elmo Pritcher

**SPECIES**

Canine

**BREED**

Lab Mix

**SEX**

MN

**AGE**

11 Years

**INTERPRETED BY**

Sebastian Jawinski,  
German Board  
Certified Vet  
Specialist in  
Diagnostic Imaging

**HOSPITAL NAME**

Animal Medical  
Center of Mt.  
Pleasant

**REFERRING VET**

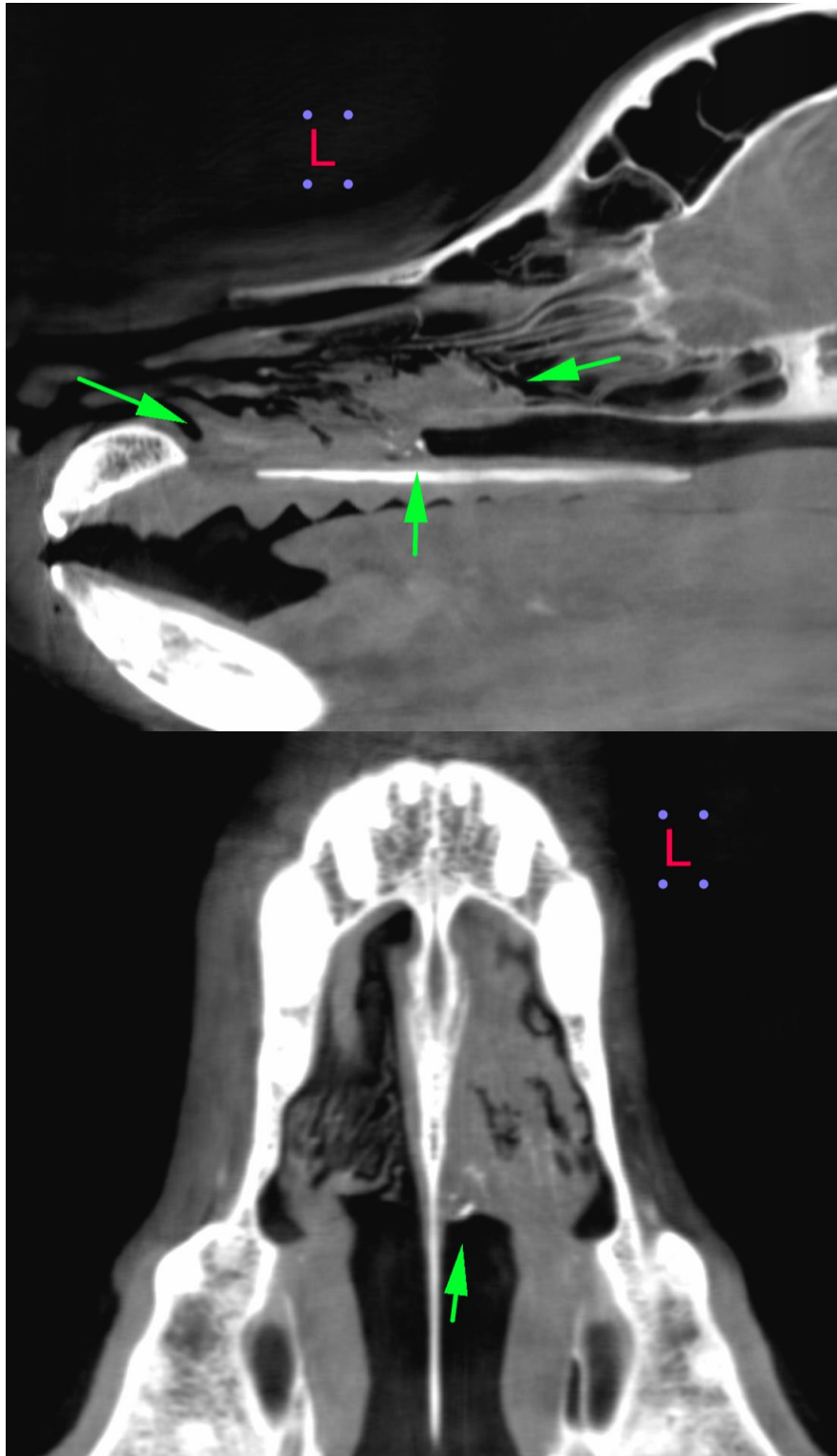
Dr. Steven Epstein

**INVOICE**

59274

**DATE**

7-11-23





**PATIENT**

Elmo Pritcher

**SPECIES**

Canine

**BREED**

Lab Mix

**SEX**

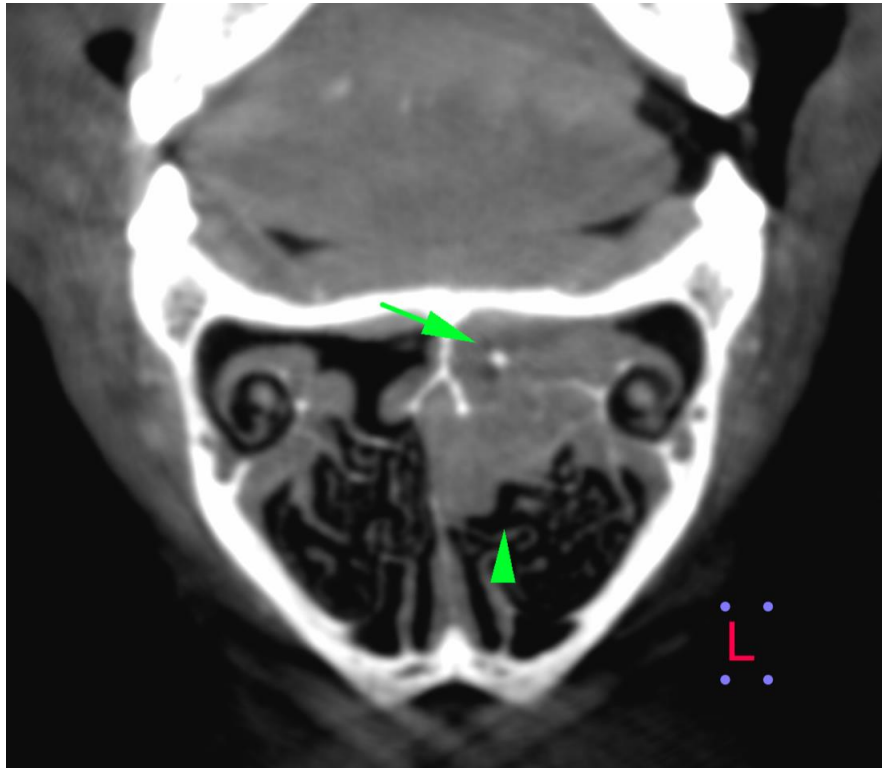
MN

**AGE**

11 Years

**INTERPRETED BY**

Sebastian Jawinski,  
German Board  
Certified Vet  
Specialist in  
Diagnostic Imaging



The information and recommendations provided are based on the images presented by the referring veterinarian/sonographer. No evaluation can be communicated regarding pathology that was not visible in the image/video clips provided.

**HOSPITAL NAME**

Animal Medical  
Center of Mt.  
Pleasant

Thank you for this referral. If the clinical or image interpretation does not parallel your findings or if I can be of any further assistance, please contact me.

Sebastian Jawinski, German Board Certified Vet Specialist in Diagnostic Imaging  
[info@sonopath.com](mailto:info@sonopath.com)

**REFERRING VET**

Dr. Steven Epstein

**INVOICE**

59274

**DATE**

7-11-23