



PATIENT PRESENTING CLINICAL SIGNS

Aspen Bendana Reason for Visit: Coughing/Bloodwork History: 9 y/o FS bichon frise presented for coughing + bloodwork. P has always had a reverse sneeze triggered when excited but starting 2 months ago O noticed that P started to develop a cough/hack that happens multiple time throuhgout the day especially at night- P does have a heart murmur O made a cardiologist appt for the end of this month but no excercise intolerance or respiratory distress noticed. P has also been scooting- has a hx of anal gland

SPECIES Canine

BREED Bichon Frise

Abnormal PE/Chem/CBC/UA Results: Hydration: N Mentation: N EENT: early central cataracts OU, positive menace ou Oral Cavity: mod-heavy tartar Lymph Nodes: N Skin: N CV/Respiratory: 4/6 left sys murmur, lungs clear, good femoral pulses Abd/GI: N Uro/Perineum: N Musculoskeletal: Bilateral grade 2-3 MPL's Neurological: N Assessment: 1) Worsening cough - r/o cardiac, collapsing trachea 2) 4/6 left sys murmur Treatment Plan: 1+2) Vetmedin, hycodan until appt with Dr Shroeder in 2 weeks pending rad consult

SEX

SF

RADIOGRAPH OF THE THORAX

Right/left lateral and ventrodorsal views provided for review.

AGE RADIOGRAPHIC FINDINGS

9 Years, 4 Months The surrounding bony structures present age-appropriate degenerative changes without further relevance. The extra-thoracic soft tissues are homogenous without abnormalities.

INTERPRETED BY

Sebastian Jawinski,
German Board
Certified Vet
Specialist in
Diagnostic Imaging

The thoracic trachea appears elevated running parallel to the thoracic spine. Transverse diameters measure 11 – 13 mm. The luminal outline of the trachea is smooth.
The left atrium is prominent with a well-defined cardiac silhouette. The vertebral heart score is estimated due to positioning and equals 11.0.
The pulmonary vessels are normal in size and taper appropriately in the periphery.
The lung density appears normal throughout. There is no evidence of nodular or focal lesions recognized.

HOSPITAL NAME

DPC Veterinary
Hospital

The mediastinum presents expected soft tissue density, there is no evidence of tracheobronchial, cranial mediastinal or sternal lymphadenopathy. No mediastinal shift is seen. The esophagus is not visible and considered to be normal. The diaphragm is unremarkable, no signs of pleural effusion.

REFERRING VET

Dr. Feldt

RADIOGRAPHIC DIAGNOSIS

- Dorsal elevation of the trachea with suspected left atrial enlargement

INVOICE INTERPRETATION OF THE FINDINGS & FURTHER RECOMMENDATIONS

59276

The increase of interstitial lung density in the lateral projection most likely is artificial due to the expiratory phase and the mild torsion of the chest. The VHS could be misinterpreted. However, the dorsal elevation and the suspected left atrial enlargement would match with the reported clinical presentation. Signs of a relevant tracheal collapse or congestive heart failure are currently not detected.

DATE

7-11-23



PATIENT

Aspen Bendana

Next diagnostic steps could be echocardiography and endoscopy with BAL for cytology and microbiological testing if empiric therapy is not successful.

SPECIES

Canine

BREED

Bichon Frise

SEX

SF

AGE

9 Years, 4 Months

INTERPRETED BY

Sebastian Jawinski,
German Board
Certified Vet
Specialist in
Diagnostic Imaging

HOSPITAL NAME

DPC Veterinary
Hospital

REFERRING VET

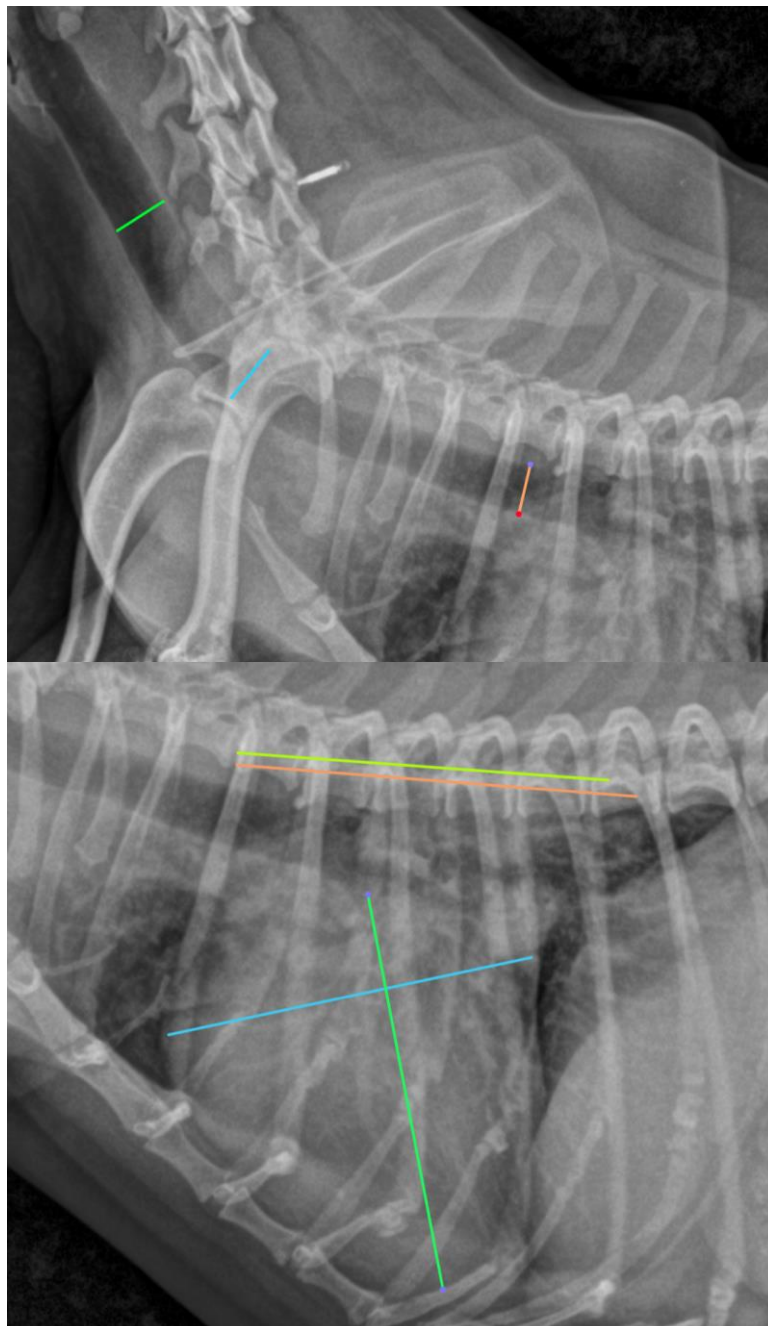
Dr. Feldt

INVOICE

59276

DATE

7-11-23





PATIENT

Aspen Bendana

SPECIES

Canine

BREED

Bichon Frise

SEX

SF

AGE

9 Years, 4 Months

INTERPRETED BY

Sebastian Jawinski,
German Board
Certified Vet
Specialist in
Diagnostic Imaging

HOSPITAL NAME

DPC Veterinary
Hospital

REFERRING VET

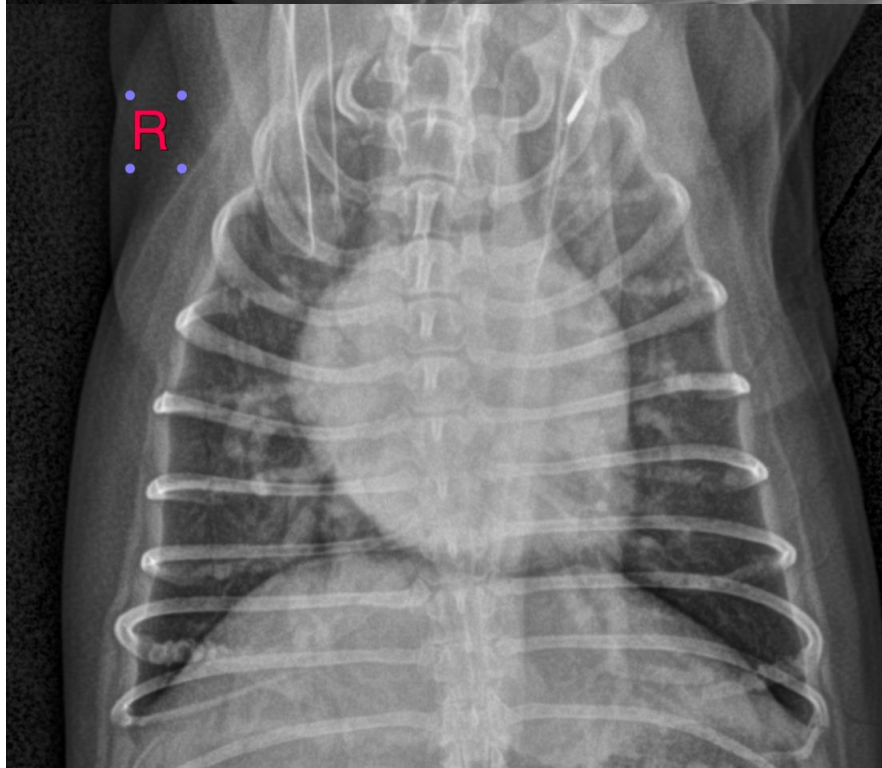
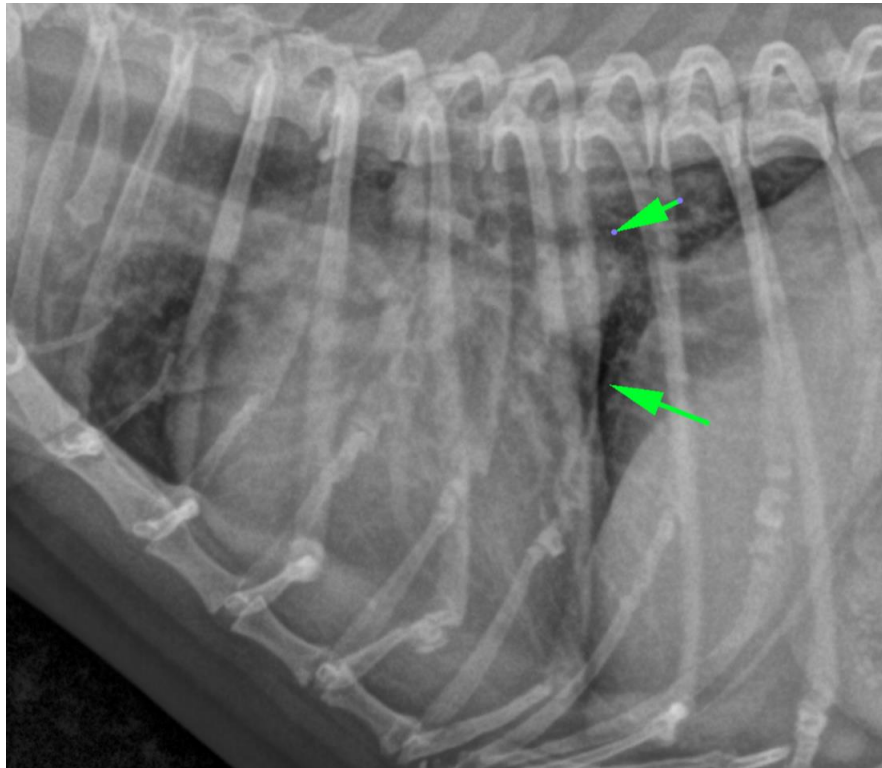
Dr. Feldt

INVOICE

59276

DATE

7-11-23





PATIENT

Aspen Bendana

The information and recommendations provided are based on the images presented by the referring veterinarian/sonographer. No evaluation can be communicated regarding pathology that was not visible in the image/video clips provided.

SPECIES

Canine

Thank you for this referral. If the clinical or image interpretation does not parallel your findings or if I can be of any further assistance, please contact me.

BREED

Bichon Frise

Sebastian Jawinski, German Board Certified Vet Specialist in Diagnostic Imaging
info@sonopath.com

SEX

SF

AGE

9 Years, 4 Months

INTERPRETED BY

Sebastian Jawinski,
German Board
Certified Vet
Specialist in
Diagnostic Imaging

HOSPITAL NAME

DPC Veterinary
Hospital

REFERRING VET

Dr. Feldt

INVOICE

59276

DATE

7-11-23