



PATIENT PRESENTING CLINICAL SIGNS

Maddie Ross History: Acute coughing and discomfort, P was treated initially with prednisone gabapentin and methocarbamol after x-rays on 5/28 for lumbar/cervical pain and possible bronchial inflammation, P has had minimal response to medications follow up radiographs taken 6/8.
Abnormal PE/Chem/CBC/UA Results: cbc/chem pending

SPECIES

Canine

RADIOGRAPHIC STUDY OF THE THORAX, ABDOMEN & SPINE

Thorax

BREED

The surrounding bony structures are within normal age-appropriate limits. The extra-thoracic soft tissues are homogenous without abnormalities.

Dachshund Miniature

The cardiac silhouette is normal without evidence of chamber enlargement. The vertebral heart score equals 9.1.

SEX

Spayed Female

The pulmonary vessels are normal in size and taper appropriately in the periphery. There is no evidence of nodular or focal lesions recognized. The lung density presents subtle and diffuse increase of interstitial density.

AGE

14.4 Pounds

The trachea appears dorsally elevated running parallel to the thoracic spine presenting a marked undulating course cranial and caudal to the thoracic inlet. Transverse diameters alter between 7 and 12 mm. The carina and the bronchial tree are prominent but without relevant collapse in the presented respiratory phases.

INTERPRETED BY

Sebastian Jawinski,
German Board
Certified Vet Specialist
in Diagnostic Imaging

The tracheal wall shows mild calcification.

The mediastinum presents expected soft tissue density, there is no evidence of tracheobronchial, cranial mediastinal or sternal lymphadenopathy. No mediastinal shift is seen. The esophagus is not visible and considered to be normal. The diaphragm is unremarkable, no signs of pleural effusion.

HOSPITAL NAME

Boca Park AH

Abdomen

The liver shows moderate enlargement with rounded but smooth margins extending caudally to the rib cage. The spleen presents as expected and is well defined.

REFERRING VET

Dr. Laura Warren

Stomach and intestine are unremarkable, predominantly empty with some gas filling of stomach and small/large intestine.

Both kidneys are not well visualized but considered to be normal.

INVOICE

15974

No signs of abdominal or retroperitoneal effusion.

The urinary bladder is mildly filled without evidence of radiopaque cystic calculi.

DATE

6/8/22



PATIENT Spine

Maddie Ross

The presented spine shows a harmonic course with inconspicuous vertebral bodies. There are no signs of a lytic or sclerotic process. There is no evidence of a fracture or subluxation. Relevant calcification of the nuclei is not recognized. The intervertebral disc spaces are of even diameter.

SPECIES RADIOGRAPHIC DIAGNOSIS

Canine

- Dorsal elevation and undulating diameter of the trachea
- Hepatomegaly
- Normal findings of the spine

BREED

INTERPRETATION OF THE FINDINGS & FURTHER RECOMMENDATIONS

Dachshund Miniature

Radiographs do reflect the reported patient’s history of coughing. The undulating tracheal diameter is suspicious for a tracheal collapse/tracheal ballooning. The subtle mineralization of the tracheal rings and the mild increase of the interstitial pulmonary density are most likely age-related changes without further relevance. Tracheitis/bronchitis may be concomitant findings of clinical relevance. Signs of a severe inflammatory or even neoplastic process are missing.

SEX

Spayed Female

AGE

14.4 Pounds

Radiographic findings of the liver could speak for a chronic liver disease and are commonly seen with fatty infiltration/chronic hepatitis since there no signs of nodular changes that are suspicious for neoplasia. Infiltrative disease cannot be ruled out. A complementary ultrasound could be performed next.

A normal radiographic appearance of the spine does not rule out lesions of the intervertebral discs/paraspinal tissues/muscles. Compressive lesions of the spinal cord remain a possible differential diagnosis.

INTERPRETED BY

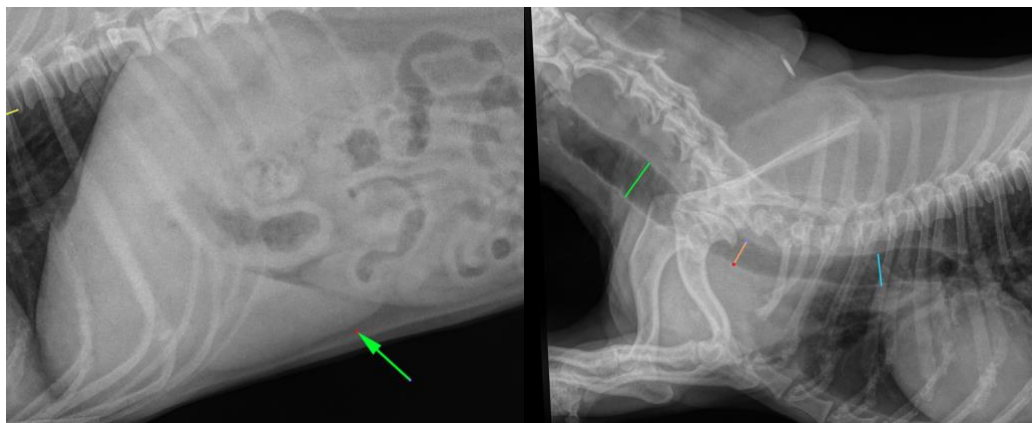
Sebastian Jawinski,
German Board
Certified Vet Specialist
in Diagnostic Imaging

HOSPITAL NAME

Boca Park AH

REFERRING VET

Dr. Laura Warren



INVOICE The information and recommendations provided are based on the images presented by the referring veterinarian/sonographer. No evaluation can be communicated regarding pathology that was not visible in the image/video clips provided.
15974

DATE

6/8/22

Thank you for this referral. If the clinical or image interpretation does not parallel your findings or if



PATIENT I can be of any further assistance please contact me.

Maddie Ross

Sebastian Jawinski, German Board Certified Vet Specialist in Diagnostic Imaging
info@sonopath.com

SPECIES

Canine

BREED

Dachshund Miniature

SEX

Spayed Female

AGE

14.4 Pounds

INTERPRETED BY

Sebastian Jawinski,
German Board
Certified Vet Specialist
in Diagnostic Imaging

HOSPITAL NAME

Boca Park AH

REFERRING VET

Dr. Laura Warren

INVOICE

15974

DATE

6/8/22