

**PATIENT**

Tuke Heska

**SPECIES**

Canine

**BREED**

Border Collie

**SEX**

F

**AGE**

20 Months

**INTERPRETED BY**

Sebastian Jawinski,  
German Board  
Certified Vet  
Specialist in  
Diagnostic Imaging

**HOSPITAL NAME**

Points East West  
Veterinary Services

**REFERRING VET**

David Lane

**INVOICE**

52599

**DATE**

6-26-22

**PRESENTING CLINICAL SIGNS**

Acute onset RHL lameness in April, that occurred while turning sharply at speed. Palpable swelling - a mix of boney, fibrous, and flocculent over the point of the right calcaneus. The calcaneal tendon appears normal on palpation, with no dropped hock or flexed toes, but the SDF tendon appears displaced.

**ULTRASONOGRAPHIC FINDINGS**

Left Achilles:

The left achilles tendon is inconspicuous (superficial flexor tendon, common calcaneal tendon and the gastrocnemius tendon are seen in continuity and appear intact).

Right Achilles:

The right achilles tendon presents mild peritendinous effusion and a prominent calcaneal bursa. The common calcaneal (CC) appears intact and is seen in continuity. At the insertion of the gastrocnemius tendon (G) small spots of mineralization are recognized. The tendon itself and the insertion again appear inconspicuous. The superficial flexor tendon is markedly thickened, surrounded by effusion and subjectively displaced. Distal to the calcaneal tuberosity small hyperechoic spots are detected within the tendon.

**ULTRASONOGRAPHIC DIAGNOSIS**

- Marked thickening of the right SDF tendon with indicated tendinous calcifications and suspected (sub-) luxation
- Mild calcifications at the level of the right gastrocnemius insertion
- Signs of a calcaneal bursitis on the right

**INTERPRETATION OF THE FINDINGS & FURTHER RECOMMENDATIONS**

Sonographic findings likely present a more chronic lesion of the SDF tendon. Chronic and/or dynamic luxation is a possible differential diagnosis. The hyperechoic spots may represent small avulsion fragments due to trauma but could also occur with chronic inflammation as seen with calcifying tendinitis. The prominent bursa and the mild effusion are consistent with an active process (arthritis/tendinitis/bursitis). Findings do match with the reported patient's history.



**PATIENT**

Tuke Heska

**SPECIES**

Canine

**BREED**

Border Collie

**SEX**

F

**AGE**

20 Months

**INTERPRETED BY**

Sebastian Jawinski,  
German Board  
Certified Vet  
Specialist in  
Diagnostic Imaging

**HOSPITAL NAME**

Points East West  
Veterinary Services

**REFERRING VET**

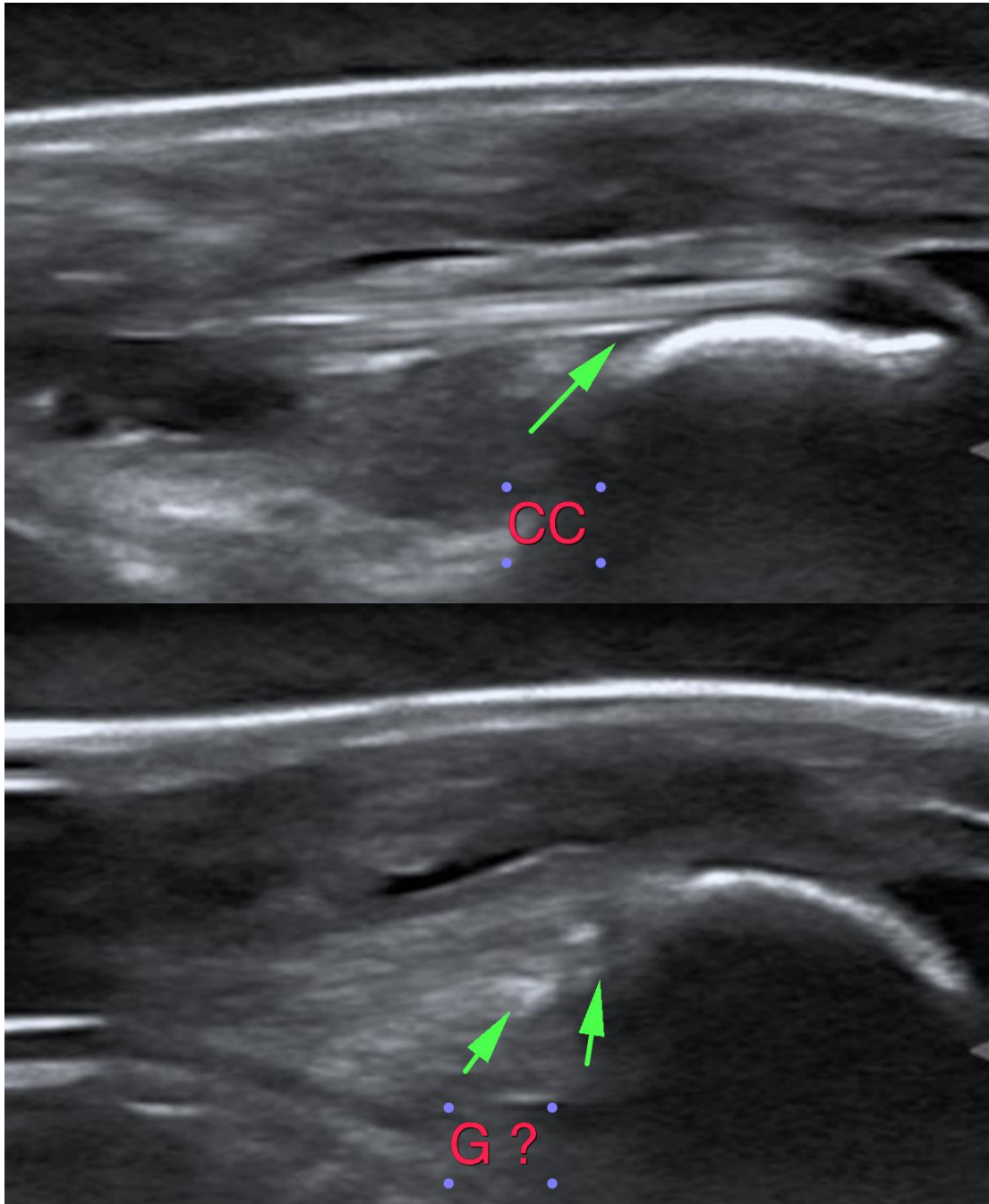
David Lane

**INVOICE**

52599

**DATE**

6-26-22





**PATIENT**

Tuke Heska

**SPECIES**

Canine

**BREED**

Border Collie

**SEX**

F

**AGE**

20 Months

**INTERPRETED BY**

Sebastian Jawinski,  
German Board  
Certified Vet  
Specialist in  
Diagnostic Imaging

**HOSPITAL NAME**

Points East West  
Veterinary Services

**REFERRING VET**

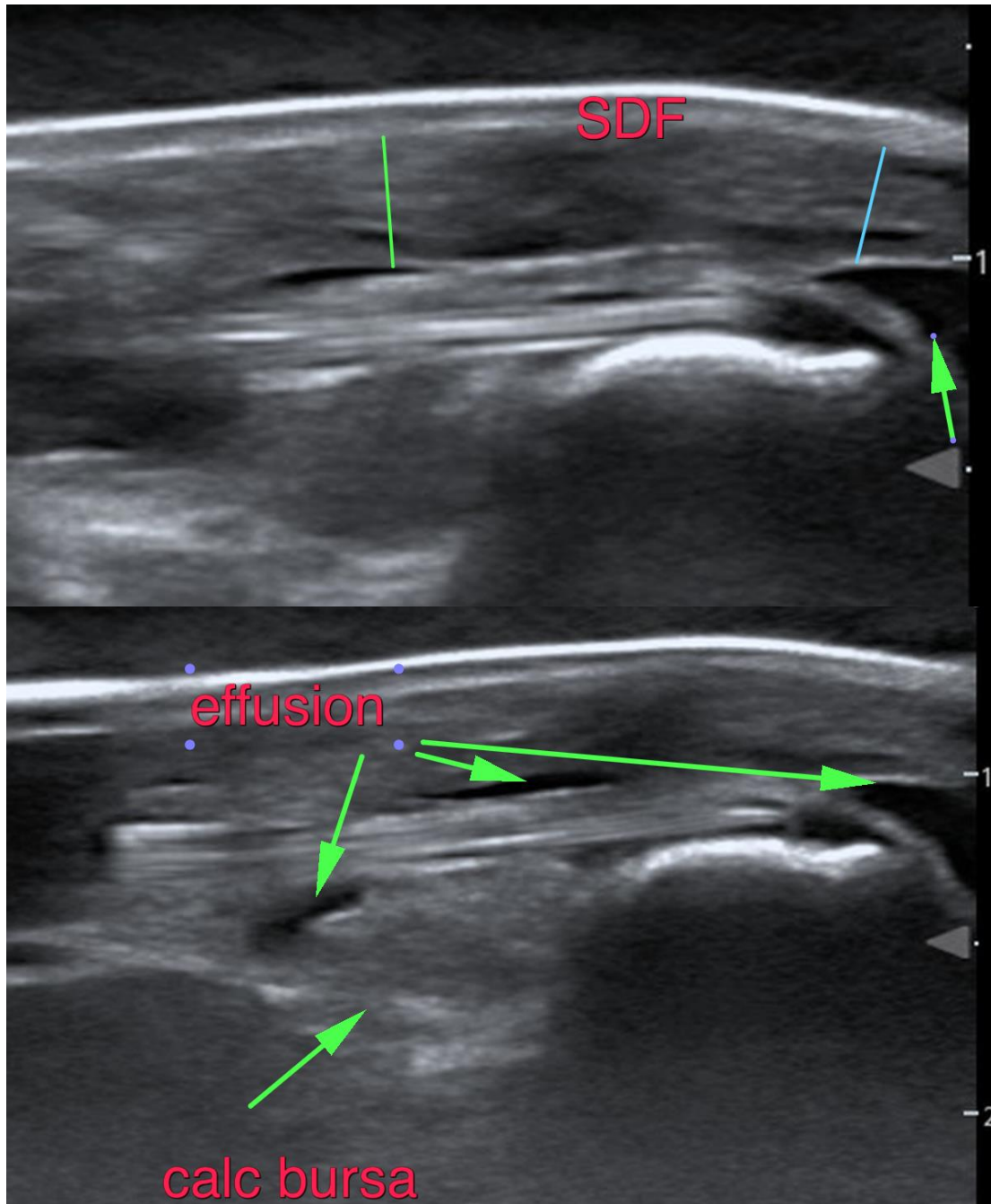
David Lane

**INVOICE**

52599

**DATE**

6-26-22





**PATIENT**

Tuke Heska

**SPECIES**

Canine

**BREED**

Border Collie

**SEX**

F

**AGE**

20 Months

**INTERPRETED BY**

Sebastian Jawinski,  
German Board  
Certified Vet  
Specialist in  
Diagnostic Imaging

**HOSPITAL NAME**

Points East West  
Veterinary Services

**REFERRING VET**

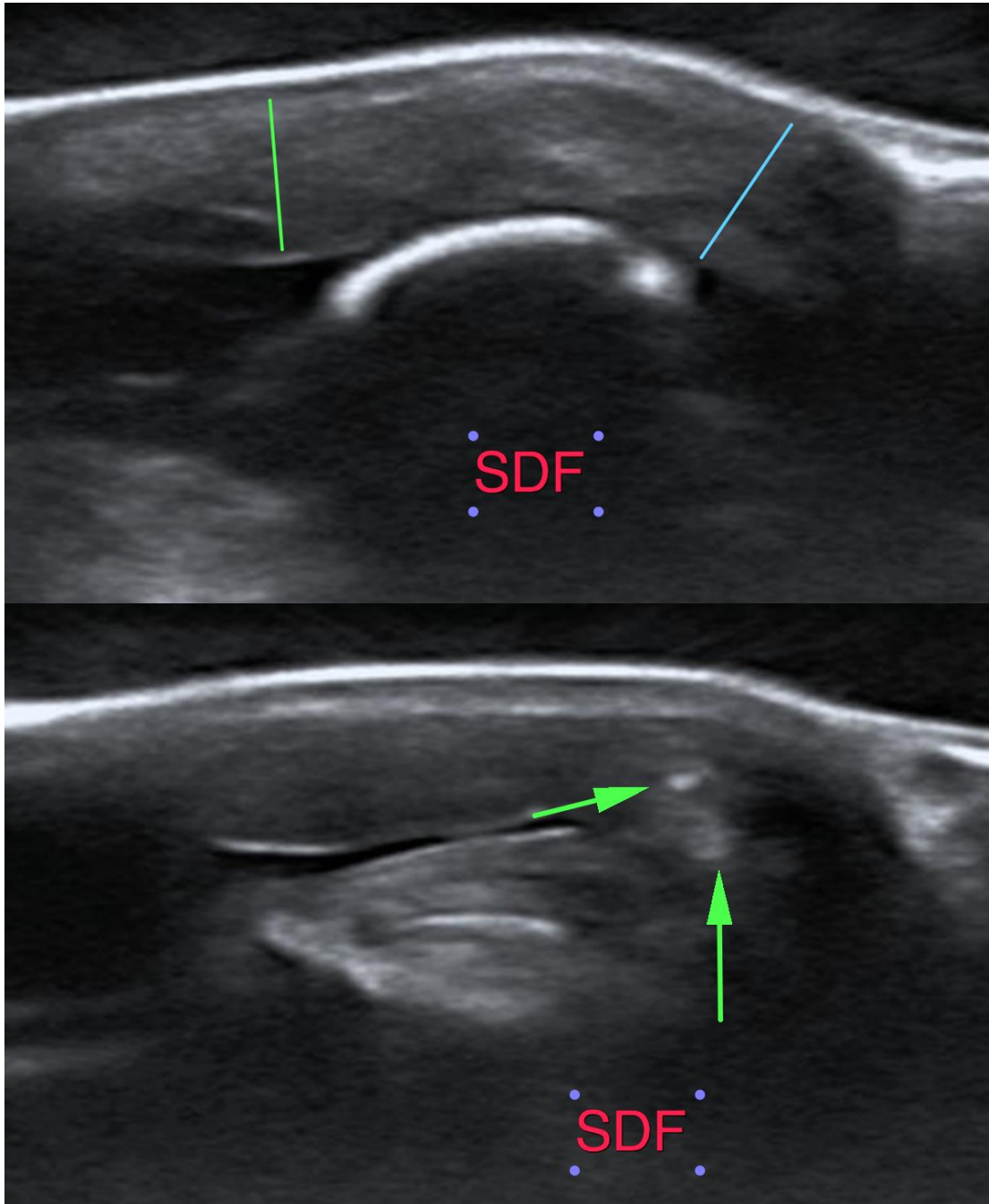
David Lane

**INVOICE**

52599

**DATE**

6-26-22





**PATIENT**

Tuke Heska

The information and recommendations provided are based on the images presented by the referring veterinarian/sonographer. No evaluation can be communicated regarding pathology that was not visible in the image/video clips provided.

Thank you for this referral. If the clinical or image interpretation does not parallel your findings or if I can be of any further assistance, please contact me.

**SPECIES**

Canine

**Sebastian Jawinski, German Board Certified Vet Specialist in Diagnostic Imaging**  
Sebastian.Jawinski@sonopath.com

**BREED**

Border Collie

**SEX**

F

**AGE**

20 Months

**INTERPRETED BY**

Sebastian Jawinski,  
German Board  
Certified Vet  
Specialist in  
Diagnostic Imaging

**HOSPITAL NAME**

Points East West  
Veterinary Services

**REFERRING VET**

David Lane

**INVOICE**

52599

**DATE**

6-26-22