



**PATIENT**

Cooper Fee

**SPECIES**

Canine

**BREED**

Wheaton Terrier

**SEX**

MN

**AGE**

12 Years

**INTERPRETED BY**

Sebastian Jawinski,  
German Board  
Certified Vet  
Specialist in  
Diagnostic Imaging

**HOSPITAL NAME**

Points East West  
Veterinary Services

**REFERRING VET**

David Lane

**INVOICE**

52598

**DATE**

6-24-22

**PRESENTING CLINICAL SIGNS**

Please see prior report #50344. Since that time, the patient has received appropriate rehabilitation and ESWT therapy. There has been a recent recurrence of marked lumbar pain, and mild right iliopsoas pain that I suspect is secondary.

**ULTRASONOGRAPHIC EXAMINATION OF THE LEFT & RIGHT ILIOPSOAS**

Follow up study (first study 2/16/22).

**ULTRASONOGRAPHIC FINDINGS**

Iliopsoas muscles/tendons/insertion left/right:

The displayed iliopsoas muscles still are diffusely hyperechoic. The muscle fibers are indicated and appear intact.

The insertions at the level of the lesser trochanter appear inconspicuous. The described mineralization in the insertion on the left (0,16 cm) is not recognized any more.

The muscle volume subjectively appears normal.

Fluid pooling within the muscle texture on both sides is not detected.

**ULTRASONOGRAPHIC DIAGNOSIS**

- Suspected bilateral, chronic iliopsoas myopathy
- No evidence of a florid lesion

**INTERPRETATION OF THE FINDINGS & FURTHER RECOMMENDATIONS**

In comparison to the first study, findings appear consolidated/regressive on both sides but are still recognizable. The bilateral hyperechoic muscles speak for an iliopsoas-myopathy. Muscle fibrosis could be a long-term consequence of that. Currently, there is no proof of an acute lesion or an active inflammatory process.



**PATIENT**

Cooper Fee

**SPECIES**

Canine

**BREED**

Wheaton Terrier

**SEX**

MN

**AGE**

12 Years

**INTERPRETED BY**

Sebastian Jawinski,  
German Board  
Certified Vet  
Specialist in  
Diagnostic Imaging

**HOSPITAL NAME**

Points East West  
Veterinary Services

**REFERRING VET**

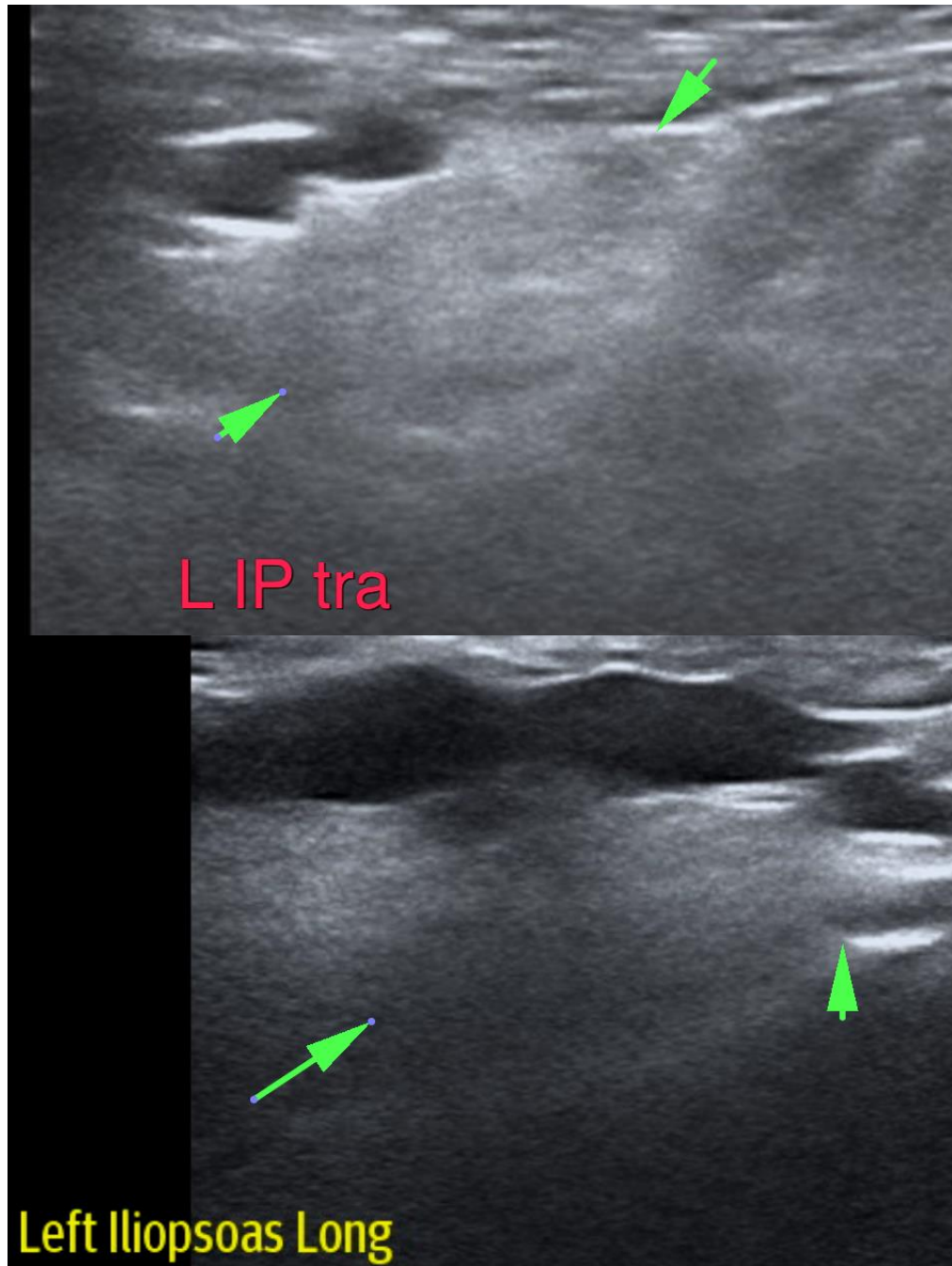
David Lane

**INVOICE**

52598

**DATE**

6-24-22





**PATIENT**

Cooper Fee

**SPECIES**

Canine

**BREED**

Wheaton Terrier

**SEX**

MN

**AGE**

12 Years

**INTERPRETED BY**

Sebastian Jawinski,  
German Board  
Certified Vet  
Specialist in  
Diagnostic Imaging

**HOSPITAL NAME**

Points East West  
Veterinary Services

**REFERRING VET**

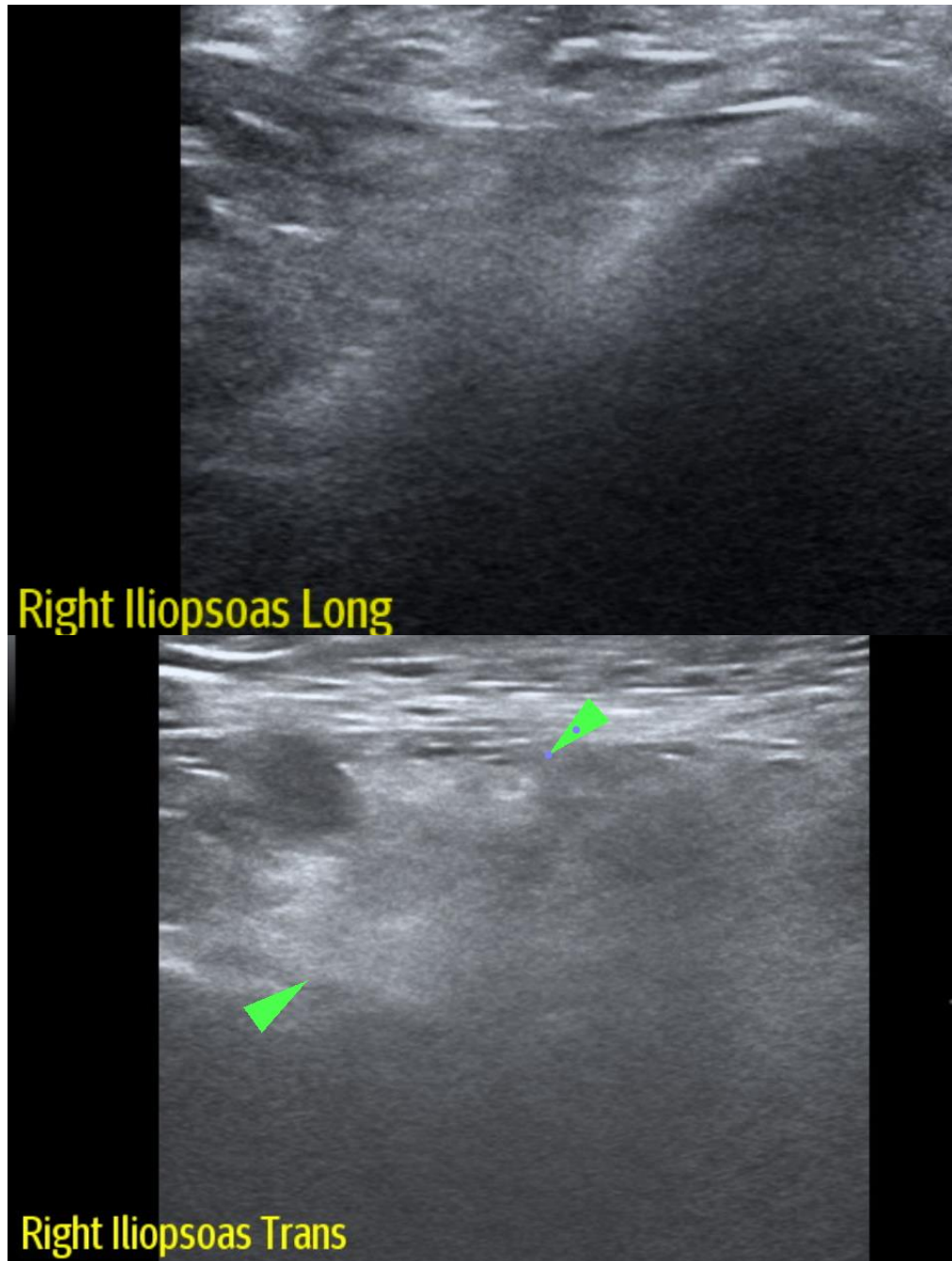
David Lane

**INVOICE**

52598

**DATE**

6-24-22





**PATIENT**

Cooper Fee

The information and recommendations provided are based on the images presented by the referring veterinarian/sonographer. No evaluation can be communicated regarding pathology that was not visible in the image/video clips provided.

**SPECIES**

Canine

Thank you for this referral. If the clinical or image interpretation does not parallel your findings or if I can be of any further assistance, please contact me.

**Sebastian Jawinski, German Board Certified Vet Specialist in Diagnostic Imaging**  
Sebastian.Jawinski@sonopath.com

**BREED**

Wheaton Terrier

**SEX**

MN

**AGE**

12 Years

**INTERPRETED BY**

Sebastian Jawinski,  
German Board  
Certified Vet  
Specialist in  
Diagnostic Imaging

**HOSPITAL NAME**

Points East West  
Veterinary Services

**REFERRING VET**

David Lane

**INVOICE**

52598

**DATE**

6-24-22