

**PATIENT PRESENTING CLINICAL SIGNS**

Bailey Hobbs Follow up from previous CT last year. Pet had enucleation after CT.

SPECIES COMPUTED TOMOGRAPHY OF THE HEAD

Canine Pre/post contrast studies provided for review.

BREED COMPUTED TOMOGRAPHIC FINDINGS

Yorkishon The neurocranium shows normal findings.

SEX

Spayed Female Both tympanic bullae are completely ventilated with a regular tympanic bulla wall.

AGE

12 Years There is no evidence of a retrobulbar lesion. The orbital soft tissues on the right are clearly defined without signs of a reactive/inflammatory or even a neoplastic process. The left eye shows age-appropriate degeneration. Nasal cavities are ventilated regularly.

INTERPRETED BY

Sebastian Jawinski,
German Board
Certified Vet Specialist
in Diagnostic Imaging

Post contrast images show no pathological enhancement.

Soft tissues of the head and neck present a progressive lipoma on the left which leads to mild deviation of the lateral cervical musculature and the jugular vein. The cervical lymph nodes are normal.

HOSPITAL NAME

Mobile Pet Imaging

COMPUTED TOMOGRAPHIC DIAGNOSIS

- Status after enucleation on the right
- Enlargement of the left cervical lipoma

REFERRING VET

Meaux

INTERPRETATION OF THE FINDINGS & FURTHER RECOMMENDATIONS

CT findings show no signs of a neoplastic or an inflammatory process. There are no typical signs of recurrence especially at the level of the right orbit. Local and/or regional metastasis are not detected. The lipoma on the left is larger than before which is considered as a normal temporary evolution. Again, signs of an aggressive lesion are missing. Although CT cannot differentiate between lipoma and liposarcoma, the latter is not suspected.

INVOICE

52532

DATE

6-21-22



PATIENT

Bailey Hobbs

SPECIES

Canine

BREED

Yorkishon

SEX

Spayed Female

AGE

12 Years

INTERPRETED BY

Sebastian Jawinski,
German Board
Certified Vet Specialist
in Diagnostic Imaging

HOSPITAL NAME

Mobile Pet Imaging

REFERRING VET

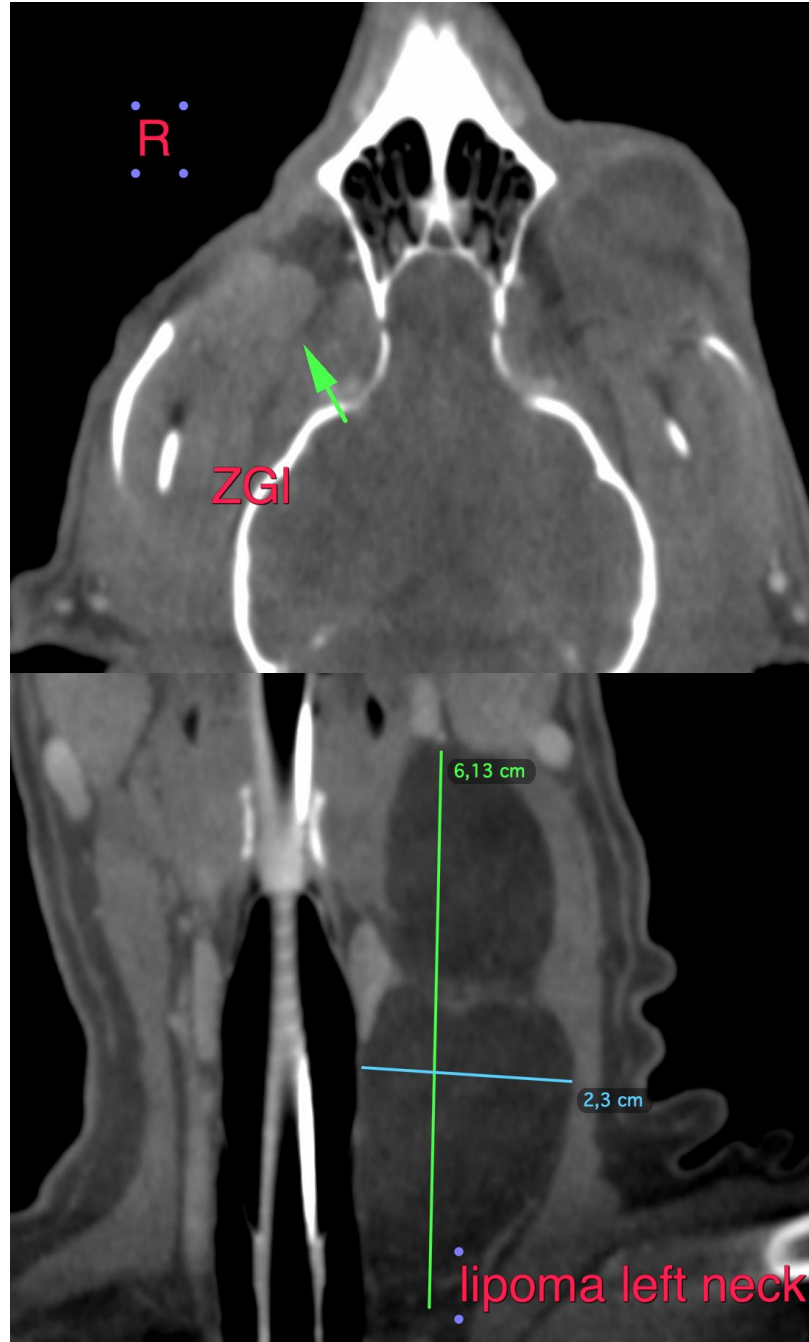
Meaux

INVOICE

52532

DATE

6-21-22





PATIENT

Bailey Hobbs

SPECIES

Canine

BREED

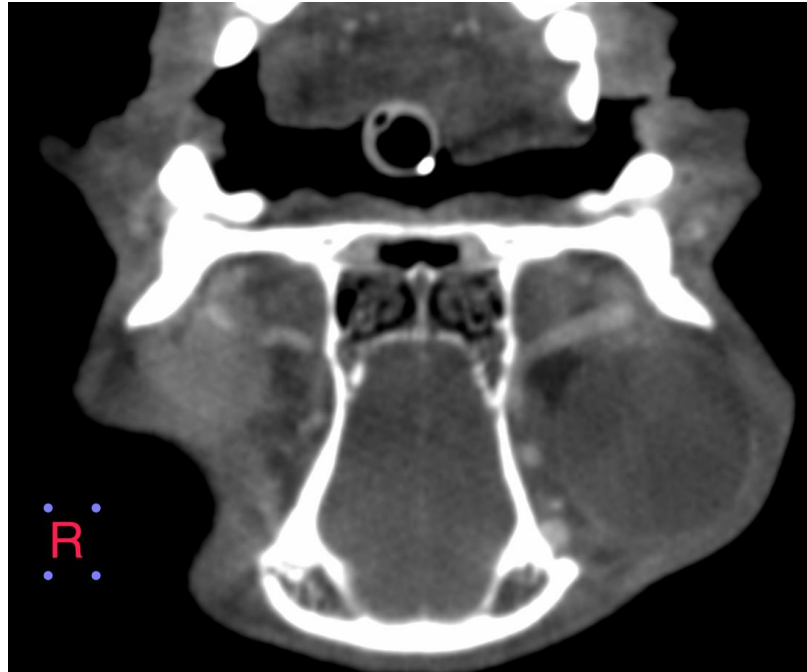
Yorkishon

SEX

Spayed Female

AGE

12 Years



INTERPRETED BY

Sebastian Jawinski,
German Board
Certified Vet Specialist
in Diagnostic Imaging

The information and recommendations provided are based on the images presented by the referring veterinarian/sonographer. No evaluation can be communicated regarding pathology that was not visible in the image/video clips provided.

Thank you for this referral. If the clinical or image interpretation does not parallel your findings or if I can be of any further assistance, please contact me.

HOSPITAL NAME

Mobile Pet Imaging

Sebastian Jawinski, German Board Certified Vet Specialist in Diagnostic Imaging
Sebastian.Jawinski@sonopath.com

REFERRING VET

Meaux

INVOICE

52532

DATE

6-21-22