



PATIENT

Kyla McKenzie

SPECIES

Canine

BREED

German Shepherd Mix

SEX

FS

AGE

11

WEIGHT

71.4

INTERPRETED BY

Sebastian Jawinski,
German Board
Certified Vet Specialist
in Diagnostic Imaging

IMAGING PERFORMED BY

LVT

HOSPITAL NAME

Heartland Pet Hospital

REFERRING VET

Dr. Matt Talbot

INVOICE

75254

DATE

6-2-26

PRESENTING CLINICAL SIGNS

P has been intermittently having hacking episodes. Primarily when P gets excited. No grooming/boarding recently. Physical exam unremarkable. BW pending

RADIOGRAPH OF THE THORAX

Right/left lateral and ventrodorsal views provided for review.

RADIOGRAPHIC FINDINGS

The images present a large, soft-tissue-dense mass, caudal to the thoracic inlet and ventral to the trachea. The trachea does not get deviated or compressed. The lesion measures approximately 13 x 12 cm and sums up with the cardiac silhouette which is ill-defined in its cranial and dorsal aspects. The cranial mediastinum is significantly widened in the DV projection.

The pulmonary structures, as far as displayed, do not show relevant nodular, focal, or diffuse changes. The bronchial and vascular structures are without particular findings. A small amount of free pleural fluid is indicated.

The bony structures of the displayed spine and ribcage are unremarkable.

The diaphragm is intact and inconspicuous.

RADIOGRAPHIC DIAGNOSIS

- Large mass cranial mediastinum

INTERPRETATION OF THE FINDINGS & FURTHER RECOMMENDATIONS

The large soft-tissue dense mass-like lesion in the cranioventral mediastinum is highly suspicious for a neoplastic lesion. Common differentials include but are not limited to lymphoma, thymoma and others like mediastinal cysts, mediastinal hemorrhage and ectopic thyroid tissue. For further differentiation, a sonographic evaluation and sampling of the cranial thorax could be performed next.



PATIENT

Kyla McKenzie

SPECIES

Canine

BREED

German Shepherd Mix

SEX

FS

AGE

11

WEIGHT

71.4

INTERPRETED BY

Sebastian Jawinski,
German Board
Certified Vet Specialist
in Diagnostic Imaging

IMAGING PERFORMED BY

LVT

HOSPITAL NAME

Heartland Pet Hospital

REFERRING VET

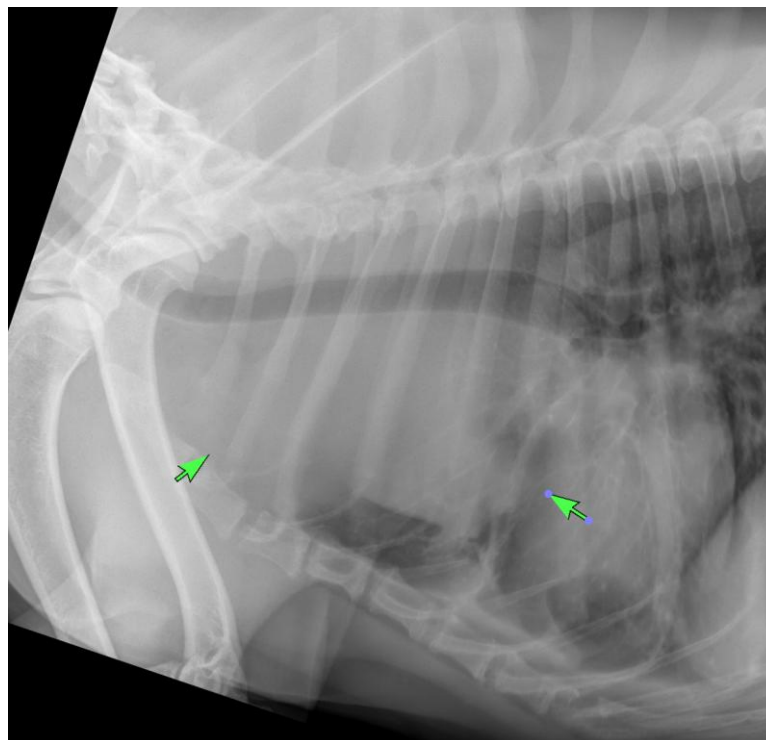
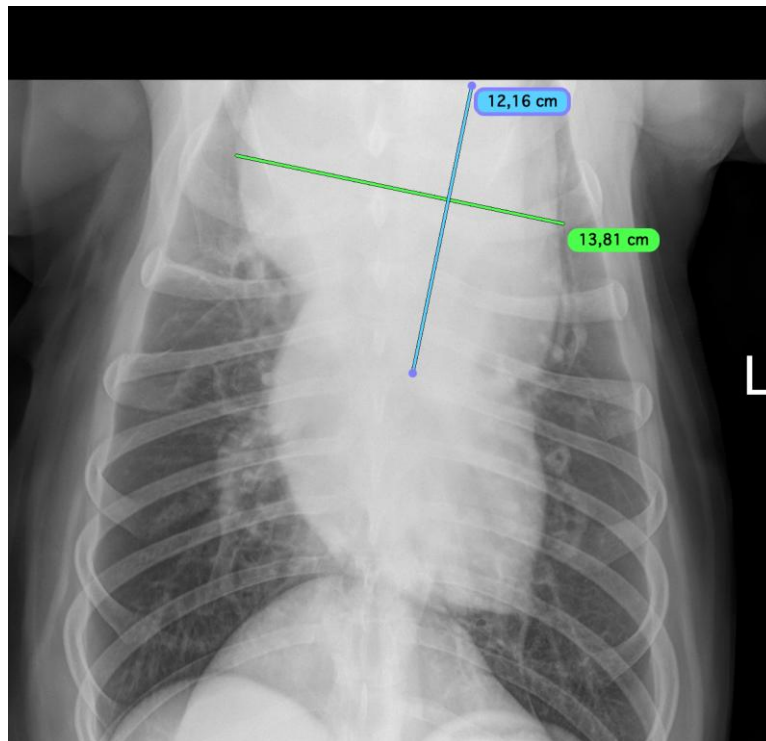
Dr. Matt Talbot

INVOICE

75254

DATE

6-2-26





PATIENT

Kyla McKenzie

SPECIES

Canine

BREED

German Shepherd Mix

SEX

FS

AGE

11

WEIGHT

71.4

INTERPRETED BY

Sebastian Jawinski,
German Board
Certified Vet Specialist
in Diagnostic Imaging

IMAGING PERFORMED BY

LVT

HOSPITAL NAME

Heartland Pet Hospital

REFERRING VET

Dr. Matt Talbot

INVOICE

75254

DATE

6-2-26

The information and recommendations provided are based on the images presented by the referring veterinarian/sonographer. No evaluation can be communicated regarding pathology that was not visible in the image/video clips provided.

Thank you for this referral. If the clinical or image interpretation does not parallel your findings or if I can be of any further assistance, please contact me.

Sebastian Jawinski, German Board Certified Vet Specialist in Diagnostic Imaging
info@sonopath.com