



**PATIENT PRESENTING CLINICAL SIGNS**

Rocky Dork P presented with cough. O claimed that cough has been present for 2 years but gradually getting worse over the last 3 days. Unable to elicit cough with tracheal palp in exam room.

**SPECIES RADIOGRAPH OF THE THORAX**

CA Right lateral and ventrodorsal views provided for review.

**RADIOGRAPHIC FINDINGS**

**BREED** The surrounding bony structures are within normal limits.

Chihuahua The extra-thoracic soft tissues are homogenous without abnormalities.

**SEX** The cardiac silhouette is normal without evidence of chamber enlargement. The vertebral heart score equals 10.0. The pulmonary vessels are normal in size and taper appropriately in the periphery.

MN The lung density appears normal throughout. There is no evidence of nodular or focal lesions recognized.

**AGE** 8 The trachea shows a moderately alternating diameter cranial to the thoracic inlet presenting transverse diameters of 1.42 to 1.30 cm and a suspected dorsal flattening of the cervical part with estimated residual transverse diameters of 0.52 cm. The tracheal course is unremarkable.

**INTERPRETED BY**

Sebastian Jawinski, German Board Certified Vet Specialist in Diagnostic Imaging The mediastinum presents expected soft tissue density, there is no evidence of tracheobronchial, cranial mediastinal or sternal lymphadenopathy. No mediastinal shift is seen.

The esophagus is not visible and considered to be normal.

**HOSPITAL NAME** The diaphragm is unremarkable without signs of pleural effusion.

Torch Lake Veterinary Clinic

**RADIOGRAPHIC DIAGNOSIS**

- Suspected moderate and long stretched tracheal collapse

**REFERRING VET INTERPRETATION OF THE FINDINGS & FURTHER RECOMMENDATIONS**

Adrienne Waffle Radiographs are suspicious for a long stretched and at least moderate tracheal collapse. Presence and grade need to be confirmed with endoscopy (r/o redundant tracheal membrane, summation effects). The latter could be used to get a BAL for cytology and microbiologic testing. Involvement of the carina and the main stem bronchi cannot be ruled out since they are depending on the respiratory phase. Currently there is no secondary pneumonia recognized.

**INVOICE**

58075

**DATE**

5-2-23



**PATIENT**

Rocky Dork

**SPECIES**

CA

**BREED**

Chihuahua

**SEX**

MN

**AGE**

8

**INTERPRETED BY**

Sebastian Jawinski,  
German Board  
Certified Vet  
Specialist in  
Diagnostic Imaging

**HOSPITAL NAME**

Torch Lake  
Veterinary Clinic

**REFERRING VET**

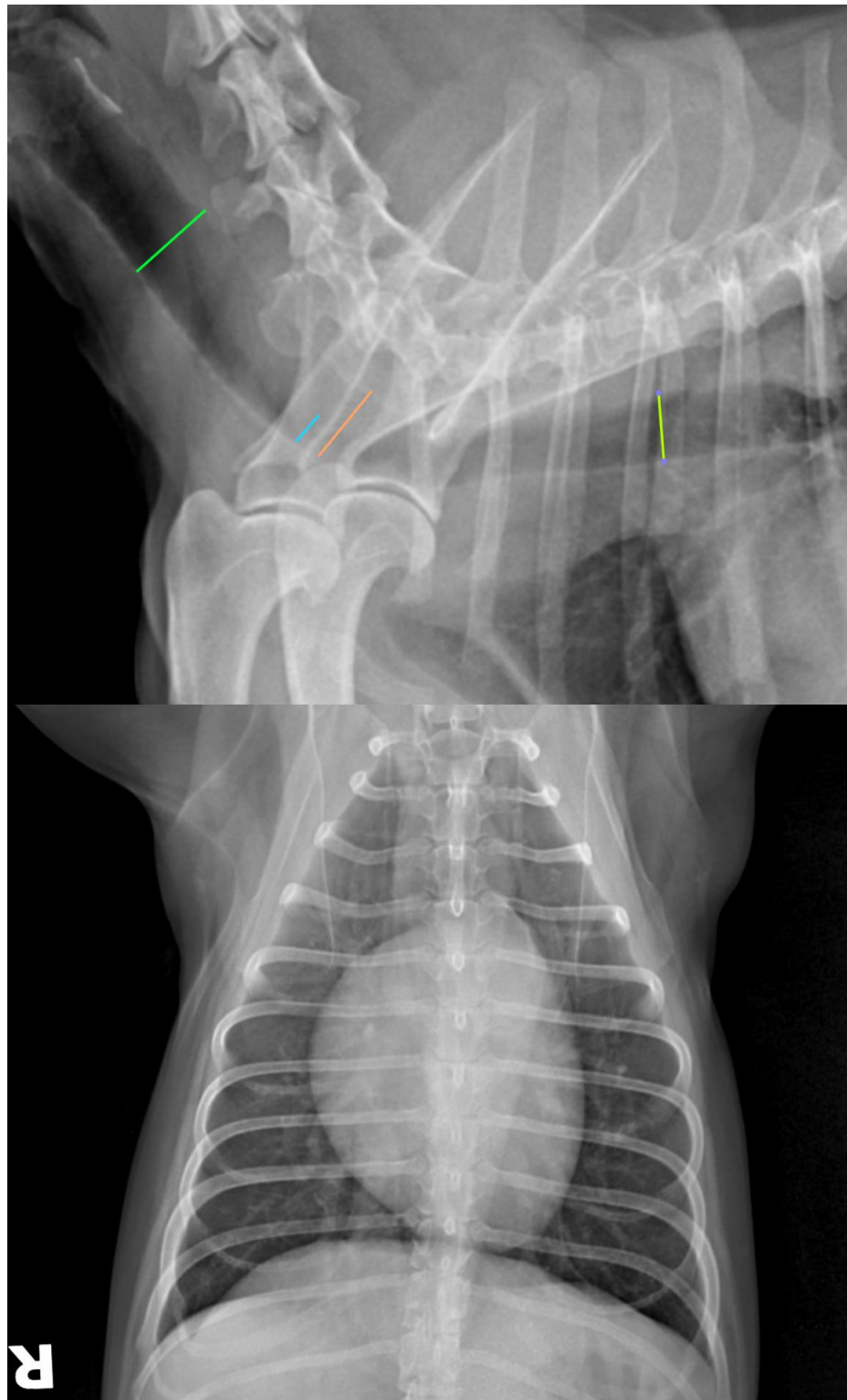
Adrienne Waffle

**INVOICE**

58075

**DATE**

5-2-23





**PATIENT**

Rocky Dork

**SPECIES**

CA

**BREED**

Chihuahua

The information and recommendations provided are based on the images presented by the referring veterinarian/sonographer. No evaluation can be communicated regarding pathology that was not visible in the image/video clips provided.

**SEX**

MN

Thank you for this referral. If the clinical or image interpretation does not parallel your findings or if I can be of any further assistance, please contact me.

**AGE**

8

**Sebastian Jawinski, German Board Certified Vet Specialist in Diagnostic Imaging**  
Sebastian.Jawinski@sonopath.com

**INTERPRETED BY**

Sebastian Jawinski,  
German Board  
Certified Vet  
Specialist in  
Diagnostic Imaging

**HOSPITAL NAME**

Torch Lake  
Veterinary Clinic

**REFERRING VET**

Adrienne Waffle

**INVOICE**

58075

**DATE**

5-2-23