

**PATIENT PRESENTING CLINICAL SIGNS**

Kota Cox P presented with R hind lameness. P has HX of pin placed due to break when young.

SPECIES RADIOGRAPHIC FINDINGS**Stifle Joints**

CA

The left patellar is luxated medially. The left stifle is breed- and age-appropriate apart from that.

BREED

Chihuahua Mix

The right stifle impresses with a severe periarticular/articular soft tissue dense swelling with elevation of the patella and cranial subluxation of the tibial plateau. Cerclage material is recognized in the cranial tibia without signs of a lytic/aggressive process. Osteolysis or relevant new bone formation is not recognized.

SEX

Displayed bony structures of both hind limbs are inconspicuous.

FS

RADIOGRAPHIC DIAGNOSIS**AGE**

16

- Severe joint effusion and periarticular swelling right stifle
- Suspected cranial subluxation of the right tibia
- Medial luxation of the left patella

INTERPRETED BY

Sebastian Jawinski,
German Board
Certified Vet
Specialist in
Diagnostic Imaging

INTERPRETATION OF THE FINDINGS & FURTHER RECOMMENDATIONS

The described changes of the right stifle indicate an active/reactive process such synovitis/osteoarthritis. Chronic synovial hyperplasia is possible due to a chronic joint instability. The findings could be secondary to an intraarticular lesion as commonly seen with a rupture of the CCL. Other soft tissue injuries (meniscus, other ligaments, etc.) and a neoplastic lesion cannot be completely excluded. The latter is not suspected since lytic changes are not obvious. Aspiration of synovia to evaluate characteristics of the joint effusion and reduce pressure could be performed next.

HOSPITAL NAME

Torch Lake
Veterinary Clinic

The clinical relevance of the medially luxated left patella is questionable.

REFERRING VET

Adrienne Waffle

INVOICE

58073

DATE

5-2-23



PATIENT

Kota Cox

SPECIES

CA

BREED

Chihuahua Mix

SEX

FS

AGE

16

INTERPRETED BY

Sebastian Jawinski,
German Board
Certified Vet
Specialist in
Diagnostic Imaging

HOSPITAL NAME

Torch Lake
Veterinary Clinic

REFERRING VET

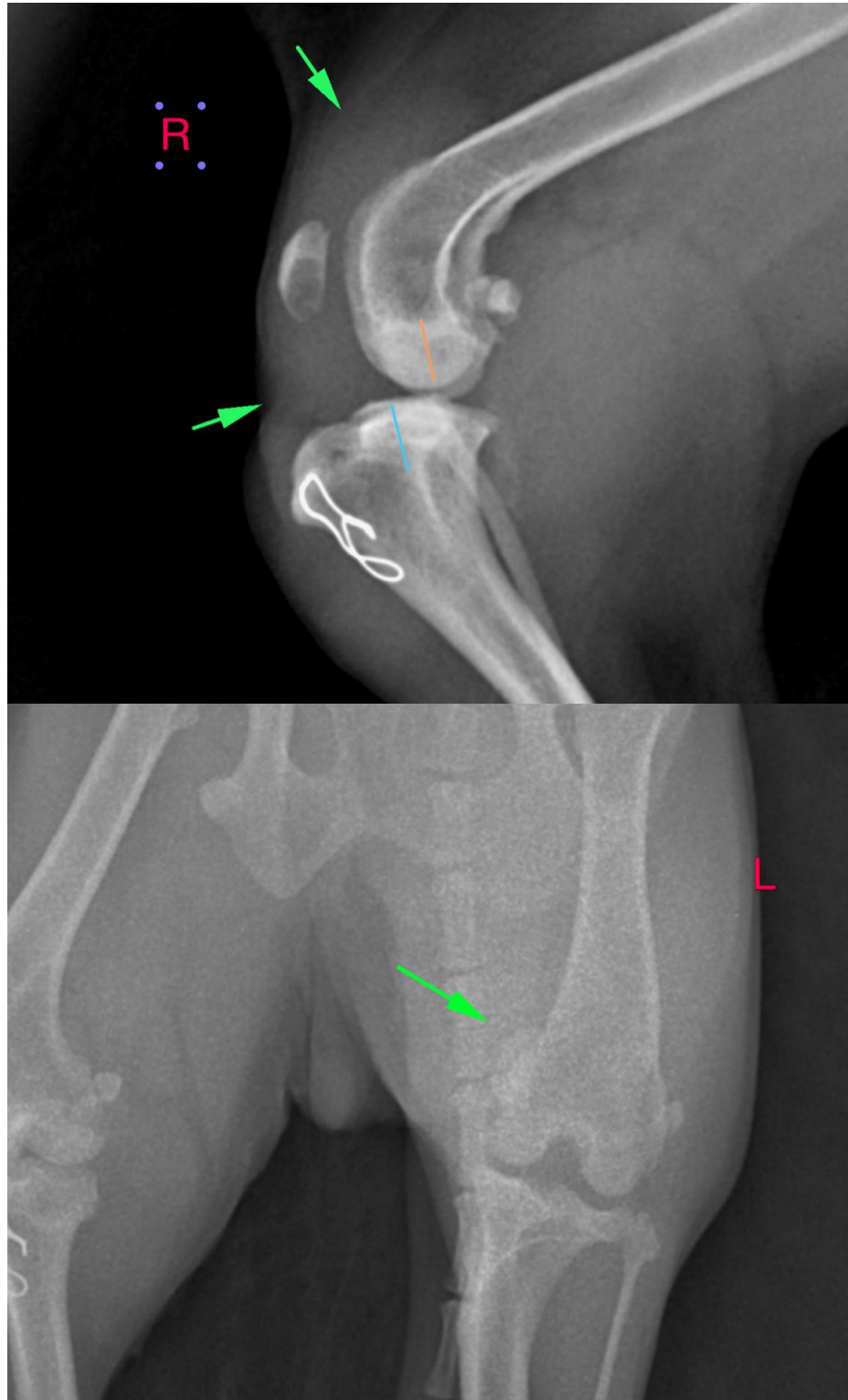
Adrienne Waffle

INVOICE

58073

DATE

5-2-23





PATIENT

Kota Cox

The information and recommendations provided are based on the images presented by the referring veterinarian/sonographer. No evaluation can be communicated regarding pathology that was not visible in the image/video clips provided.

SPECIES

CA

Thank you for this referral. If the clinical or image interpretation does not parallel your findings or if I can be of any further assistance, please contact me.

BREED

Chihuahua Mix

Sebastian Jawinski, German Board Certified Vet Specialist in Diagnostic Imaging
Sebastian.Jawinski@sonopath.com

SEX

FS

AGE

16

INTERPRETED BY

Sebastian Jawinski,
German Board
Certified Vet
Specialist in
Diagnostic Imaging

HOSPITAL NAME

Torch Lake
Veterinary Clinic

REFERRING VET

Adrienne Waffle

INVOICE

58073

DATE

5-2-23