



PATIENT

Simba Maldonado
#01091

SPECIES

Canine

BREED

Shih Tzu Mix

SEX

M

AGE

11Y

WEIGHT

21lbs

INTERPRETED BY

Sebastian Jawinski,
German Board
Certified Vet Specialist
in Diagnostic Imaging

IMAGING PERFORMED BY

Alondra Aviles Lopez
VT

HOSPITAL NAME

Veterinary Image
Center

REFERRING VET

Dr. Martinez

INVOICE

74795

DATE

4-28-26

PRESENTING CLINICAL SIGNS

Patient presents with hind limbs ataxia. Deep pain sensation is present. Marked conscious proprioceptive (CP) deficits noted.

Abnormal PE/Chem/CBC/UA Results: Chem: ALT: 240 (10-125) AMYL: 389 (500-1500)

COMPUTED TOMOGRAPHY OF THE THORACIC & LUMBAR SPINE

CT-myelogram provided for review.

COMPUTED TOMOGRAPHIC FINDINGS

The presented spine shows moderate degenerative changes of multiple discs with mild to moderate protrusions in the course of the lumbar spine, see for example L4-5 with a moderate, broad-based and medial disc protrusion and moderate compression of the spinal cord.

The protrusions at least include the levels TH13-L1, L2-3, L3-4, L5-6, L6-7, and L7-S1, each being mildly compressive to the spinal cord and the cauda fibers.

An aggressive lesion of the bony structures is not noted. A fracture or subluxation are not present.

The display parts of the chest and abdomen show an incidental moderate enlargement of the prostate, which appears bilobulated and shows multiple cysts.

COMPUTED TOMOGRAPHIC DIAGNOSIS

- Multiple disc protrusions with mild to moderate compression of the spinal cord and cauda fibers
- Multifocal degenerative changes intervertebral discs
- Moderate benign hyperplasia prostate with multiple cysts

INTERPRETATION OF THE FINDINGS & FURTHER RECOMMENDATIONS

The CT shows multiple disc protrusions that are mildly to moderately compressive to the spinal cord. The level L4-5 needs to be highlighted. However, the CT-morphologic compression of the spinal cord does not compellingly correlate with the clinical severity. With that, and with regard to the multiple findings, a clear indication for surgery is not given. Additional intramedullary lesions as seen with FCE and HNPE lesions are difficult to find or cannot be detected with CT. These are still potential differentials.



PATIENT

Simba Maldonado
#01091

SPECIES

Canine

BREED

Shih Tzu Mix

SEX

M

AGE

11Y

WEIGHT

21lbs

INTERPRETED BY

Sebastian Jawinski,
German Board
Certified Vet Specialist
in Diagnostic Imaging

IMAGING PERFORMED BY

Alondra Aviles Lopez
VT

HOSPITAL NAME

Veterinary Image
Center

REFERRING VET

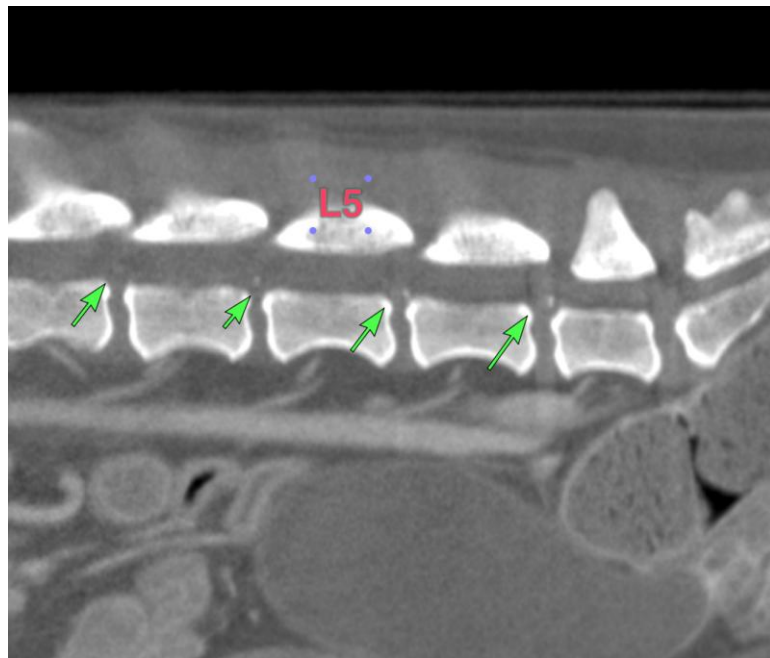
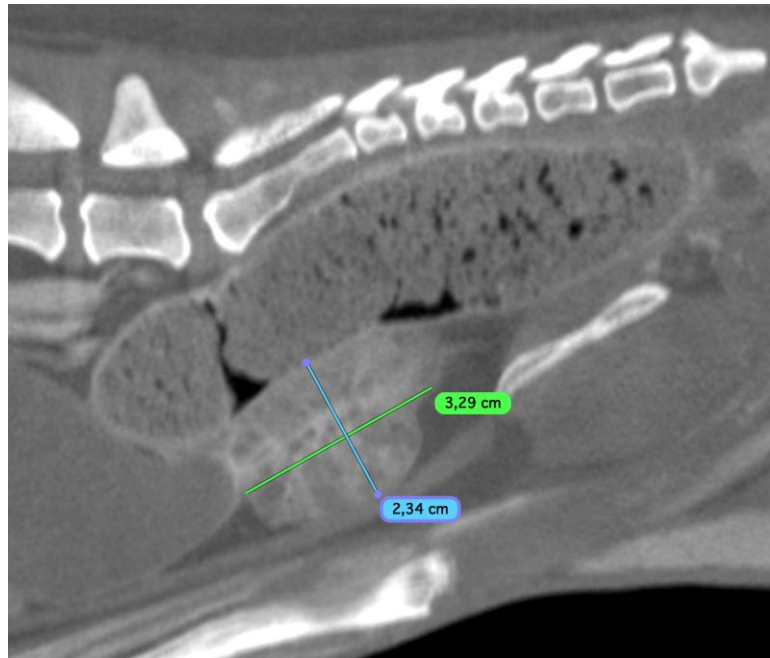
Dr. Martinez

INVOICE

74795

DATE

4-28-26





PATIENT

Simba Maldonado
#01091

SPECIES

Canine

BREED

Shih Tzu Mix

SEX

M

AGE

11Y

WEIGHT

21lbs

INTERPRETED BY

Sebastian Jawinski,
German Board
Certified Vet Specialist
in Diagnostic Imaging

IMAGING PERFORMED BY

Alondra Aviles Lopez
VT

HOSPITAL NAME

Veterinary Image
Center

REFERRING VET

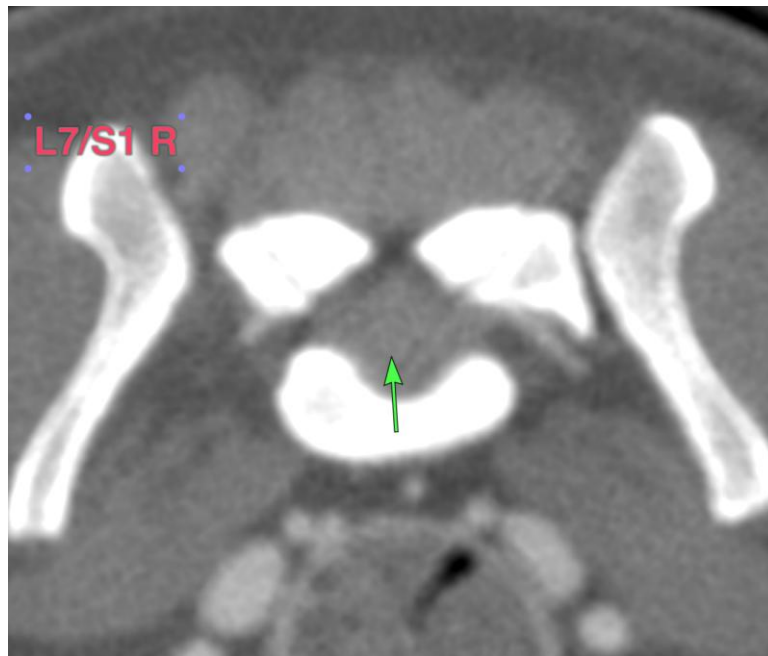
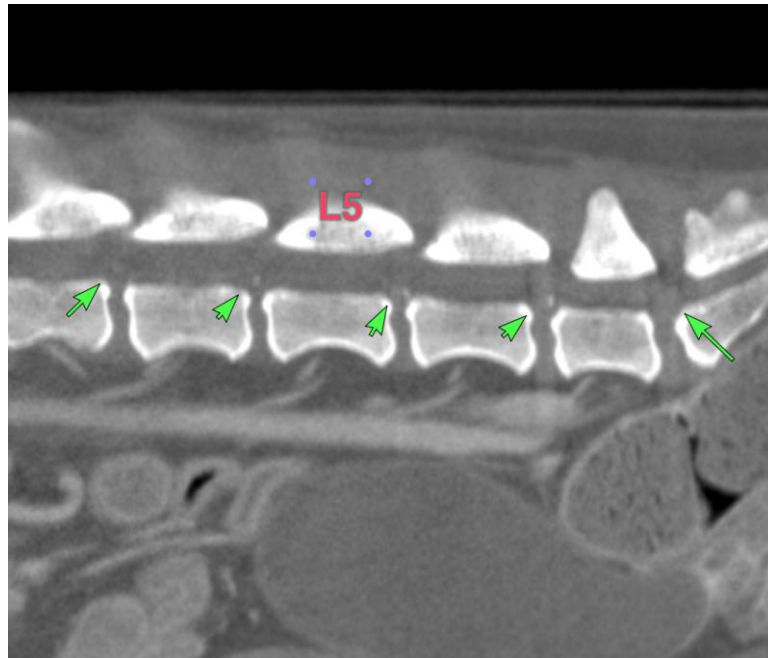
Dr. Martinez

INVOICE

74795

DATE

4-28-26





PATIENT

Simba Maldonado
#01091

SPECIES

Canine

BREED

Shih Tzu Mix

SEX

M

AGE

11Y

WEIGHT

21lbs

INTERPRETED BY

Sebastian Jawinski,
German Board
Certified Vet Specialist
in Diagnostic Imaging

IMAGING PERFORMED BY

Alondra Aviles Lopez
VT

HOSPITAL NAME

Veterinary Image
Center

REFERRING VET

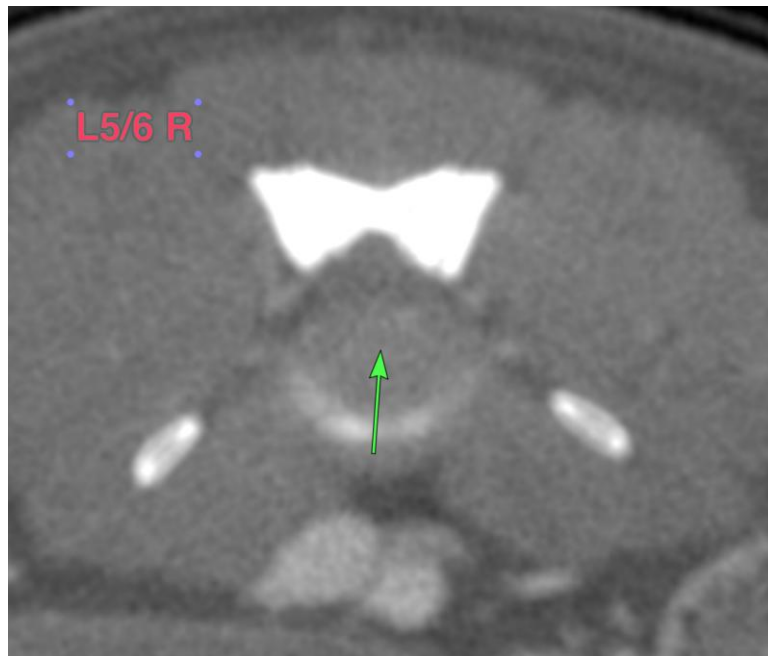
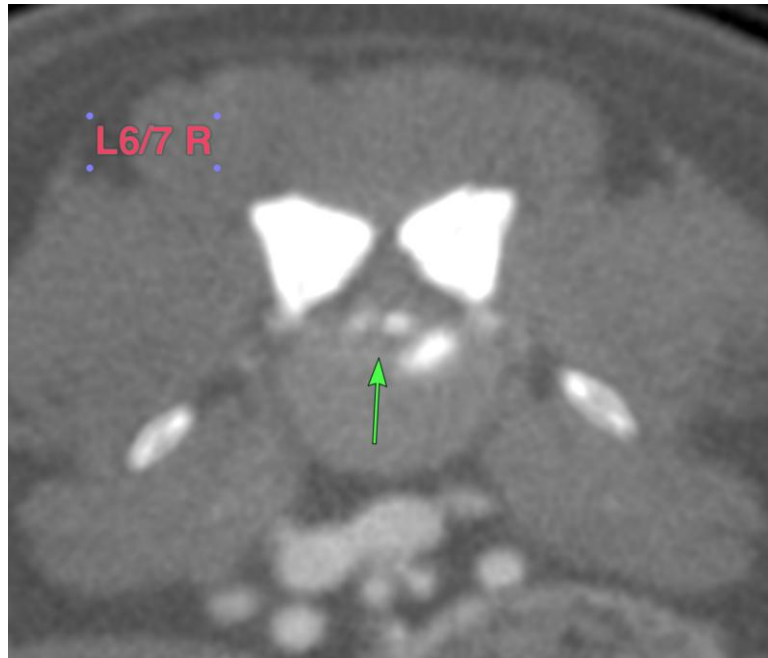
Dr. Martinez

INVOICE

74795

DATE

4-28-26





PATIENT

Simba Maldonado
#01091

SPECIES

Canine

BREED

Shih Tzu Mix

SEX

M

AGE

11Y

WEIGHT

21lbs

INTERPRETED BY

Sebastian Jawinski,
German Board
Certified Vet Specialist
in Diagnostic Imaging

IMAGING PERFORMED BY

Alondra Aviles Lopez
VT

HOSPITAL NAME

Veterinary Image
Center

REFERRING VET

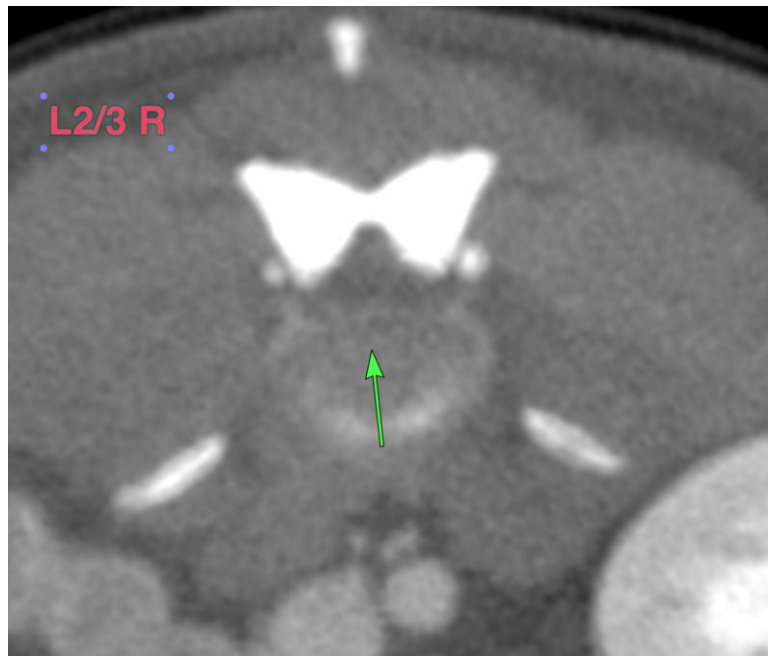
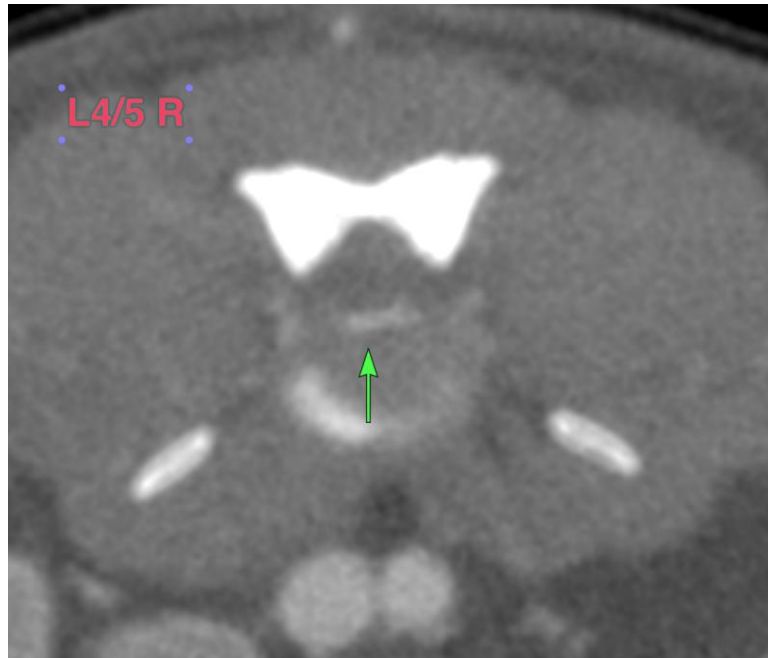
Dr. Martinez

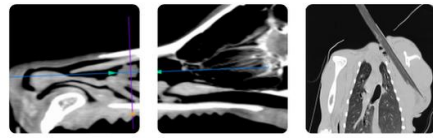
INVOICE

74795

DATE

4-28-26





PATIENT

Simba Maldonado
#01091

SPECIES

Canine

BREED

Shih Tzu Mix

SEX

M

AGE

11Y

WEIGHT

21lbs

INTERPRETED BY

Sebastian Jawinski,
German Board
Certified Vet Specialist
in Diagnostic Imaging

IMAGING PERFORMED BY

Alondra Aviles Lopez
VT

HOSPITAL NAME

Veterinary Image
Center

REFERRING VET

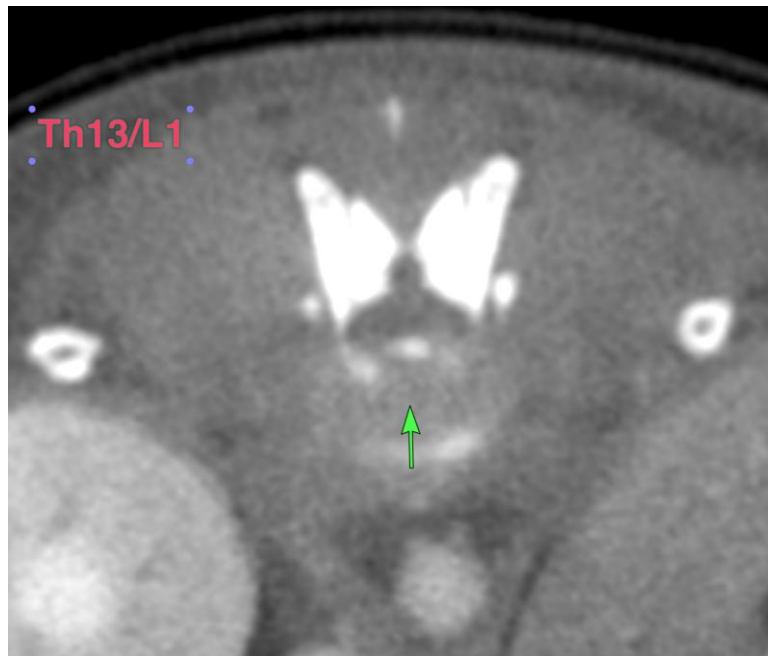
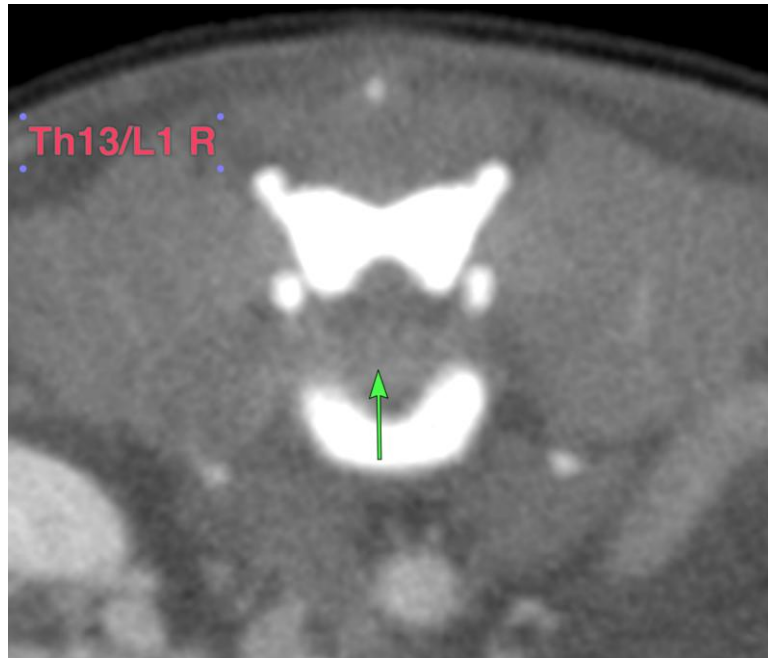
Dr. Martinez

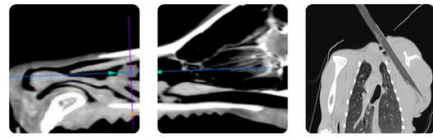
INVOICE

74795

DATE

4-28-26





PATIENT

Simba Maldonado
#01091

SPECIES

Canine

BREED

Shih Tzu Mix

SEX

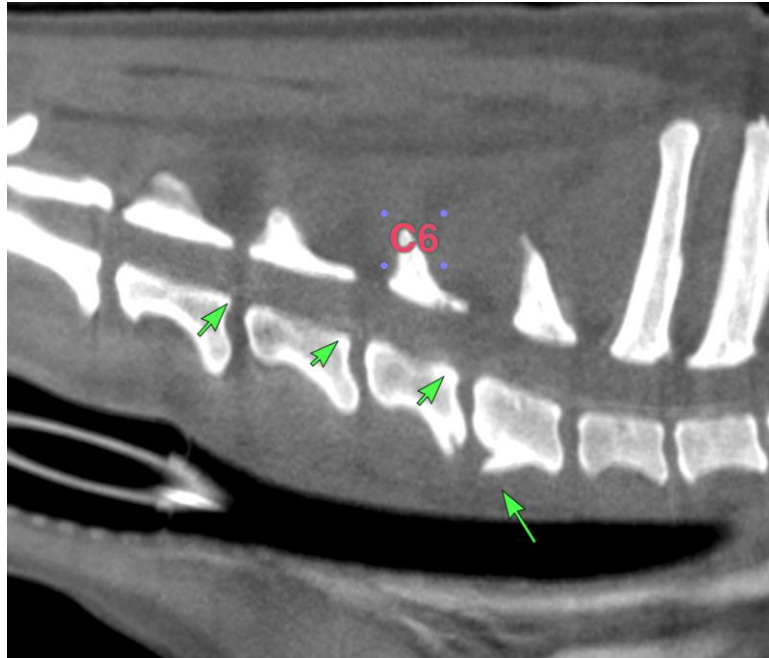M

AGE

11Y

WEIGHT

21lbs



INTERPRETED BY

Sebastian Jawinski,
German Board
Certified Vet Specialist
in Diagnostic Imaging

IMAGING PERFORMED BY

Alondra Aviles Lopez
VT

HOSPITAL NAME

Veterinary Image
Center

REFERRING VET

Dr. Martinez

INVOICE

74795

DATE

4-28-26

The information and recommendations provided are based on the images presented by the referring veterinarian/sonographer. No evaluation can be communicated regarding pathology that was not visible in the image/video clips provided.

Thank you for this referral. If the clinical or image interpretation does not parallel your findings or if I can be of any further assistance, please contact me.

Sebastian Jawinski, German Board Certified Vet Specialist in Diagnostic Imaging
info@sonopath.com