



PATIENT PRESENTING CLINICAL SIGNS

Suzie Weisz History: clinical signs of Horner's since 4/19/2023

COMPUTED TOMOGRAPHIC STUDY OF THE HEAD AND NECK

SPECIES

Canine

The neurocranium shows normal findings. Pituitary gland is within normal limits. Bony structures of the skull and the skull foramina of the cranial nerves are laterally symmetrical and inconspicuous. Both tympanic bullae are completely ventilated with a regular tympanic bulla wall. External ear canals are ventilated in all sections, walls of the external ear canals, the adjacent temporomandibular joints and the nasopharyngeal meatus have no particular findings.

BREED

Mixed Breed

Frontal sinuses and the orbital contents are laterally symmetrical without evidence of a retrobulbar lesion. Nasal cavities are ventilated regularly. Conches and the maxillary/mandibular teeth appear regular.

SEX

Neutered Male

Post contrast images show no pathological enhancement. Soft tissues of the head and neck are symmetrical and of homogeneous density, especially the medial retropharyngeal lymph nodes. Both thyroid glands are within normal limits.

COMPUTED TOMOGRAPHIC DIAGNOSIS

AGE

9

- Normal CT findings of the head and neck

INTERPRETATION OF THE FINDINGS & FURTHER RECOMMENDATIONS

INTERPRETED BY

Sebastian Jawinski,
German Board
Certified Vet Specialist
in Diagnostic Imaging

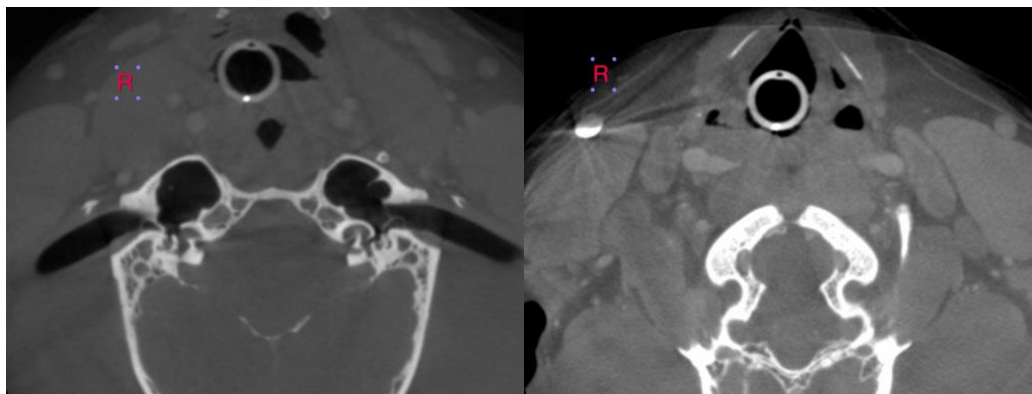
CT findings show no signs of a neoplastic or an inflammatory process. Intra-axial lesions such as infarcts, small edema or low-grade neoplasia are difficult to recognize in CT and therefore not ruled out completely.

HOSPITAL NAME

Advanced Animal
Imaging

REFERRING VET

Blair Hollowell



INVOICE

22146

The information and recommendations provided are based on the images presented by the referring veterinarian. No evaluation can be communicated regarding pathology that was not visible in the image/video clips provided.

DATE

4/21/23



PATIENT Thank you for this referral. If the clinical or image interpretation does not parallel your findings or if I can be of any further assistance please contact me.

Suzie Weisz

SPECIES

Sebastian Jawinski, German Board Certified Vet Specialist in Diagnostic Imaging
info@sonopath.com

Canine

BREED

Mixed Breed

SEX

Neutered Male

AGE

9

INTERPRETED BY

Sebastian Jawinski,
German Board
Certified Vet Specialist
in Diagnostic Imaging

HOSPITAL NAME

Advanced Animal
Imaging

REFERRING VET

Blair Hollowell

INVOICE

22146

DATE

4/21/23