



PATIENT PRESENTING CLINICAL SIGNS

Rigby Falls presented to TAHP Sx Service on April 18 2023 for evaluation of elbow dysplasia. Per medical record, owner mentioned that when patient was 5 months old he had a lameness on 1 of the front limbs after an injury. Radiographs performed by RDVM: Mild sclerosis of ulnar notch bilaterally. No obvious evidence of osteophytosis. The presence of fragmented coronoid process remains unclear radiographically.

SPECIES

Canine

COMPUTED TOMOGRAPHY OF THE FORELIMBS

Plain study provided for review.

BREED

Labrador Retriever

COMPUTED TOMOGRAPHIC FINDINGS

SEX

M

Paws, metacarpal and carpal joints and bones are unremarkable on the right. On the left side mild osteophytic new bone formation is noted at the level of the distal Mc V with small calcifications and soft tissue swelling in its periphery.

AGE

10 Months

The left proximal ulna presents a moderate and locally limited increase of medullary density. Cortical structures are unremarkable.

The left elbow shows a mild incongruity of the radioulnar joint space with alternations of density of the medial coronoid process. Compelling signs of a fissure or fragmentation are not recognized.

INTERPRETED BY

Sebastian Jawinski,
German Board
Certified Vet
Specialist in
Diagnostic Imaging

The right elbow is unremarkable.

Both humeri and shoulder joints have no particular findings. Soft tissues are bilaterally symmetrical including both brachial plexuses.

COMPUTED TOMOGRAPHIC DIAGNOSIS

HOSPITAL NAME

Animal Health
Partners

- Moderate increase of the medullary bone density of the left proximal ulna
- Lesion/osteoarthritis of the left distal Mc V
- Suspected lesion of the left medial coronoid process with alternations of bone density and radioulnar incongruity

REFERRING VET

Dr. Kim Murphy

INTERPRETATION OF THE FINDINGS & FURTHER RECOMMENDATIONS

Findings of the left ulna likely represent an inflammatory process as seen with panosteitis/osteomyelitis. Common differentials are hematogenous infectious disease and bone infarcts after trauma (systemic disease? CRP/hyperthermia? if so, consider antibiotics).

INVOICE

57871

Another cause of lameness is presented by the lesion of the distal Mc V. This likely is an osteophytic reaction after trauma. The mild periarticular swelling indicates a reactive/active inflammation (local pain?).

DATE

4-18-23

Restriction of activity and pain therapy with follow up radiographs of the left forearm in 4 weeks are recommended.



PATIENT Rigby Falls
CT findings of the left elbow joint also can be of clinical relevance, especially this being an asymmetric finding. Currently compelling signs of a fissure, fragmentation or relevant secondary arthrosis are not noted.

SPECIES

Canine

BREED

Labrador Retriever

SEX

M

AGE

10 Months

INTERPRETED BY

Sebastian Jawinski,
German Board
Certified Vet
Specialist in
Diagnostic Imaging

HOSPITAL NAME

Animal Health
Partners

REFERRING VET

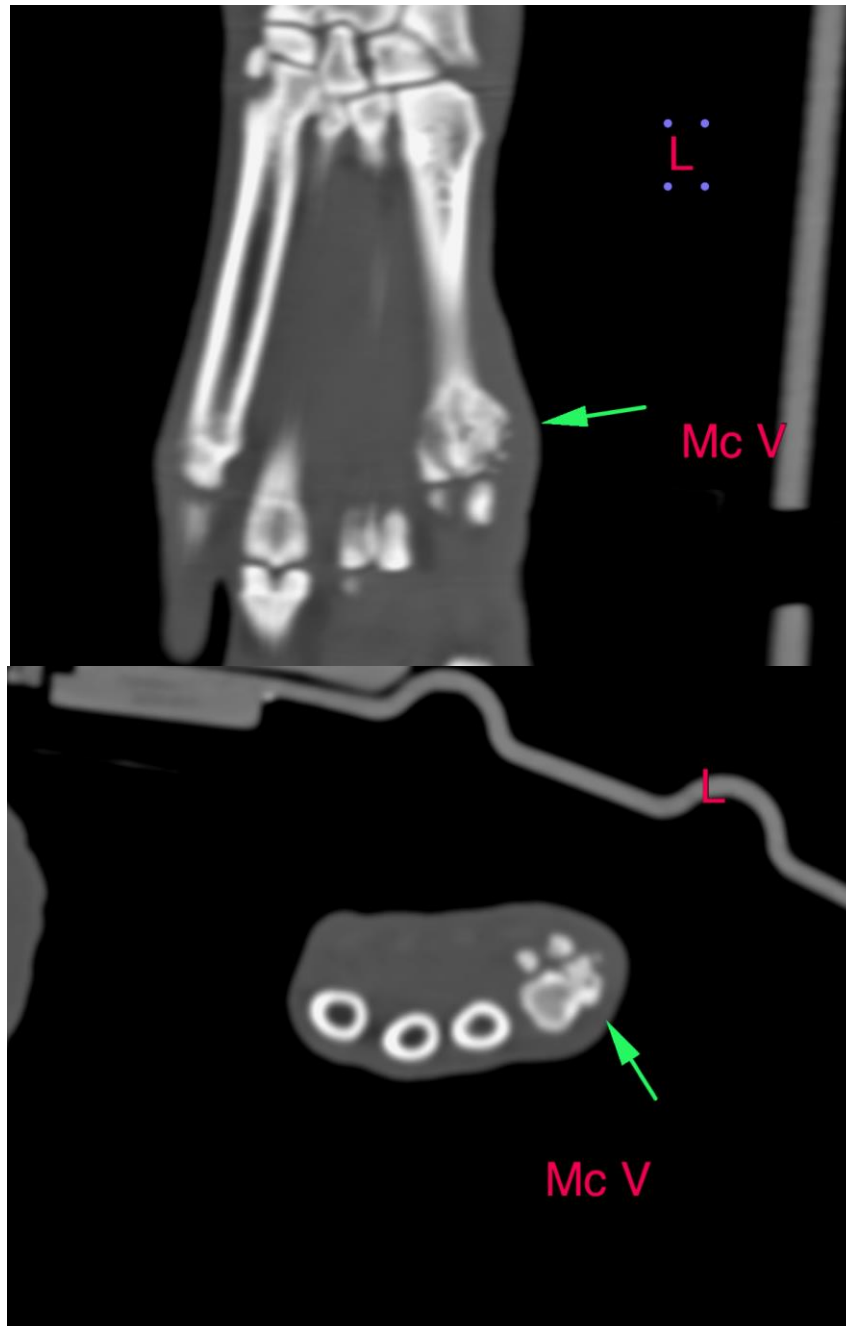
Dr. Kim Murphy

INVOICE

57871

DATE

4-18-23





PATIENT

Rigby Falls

SPECIES

Canine

BREED

Labrador Retriever

SEX

M

AGE

10 Months

INTERPRETED BY

Sebastian Jawinski,
German Board
Certified Vet
Specialist in
Diagnostic Imaging

HOSPITAL NAME

Animal Health
Partners

REFERRING VET

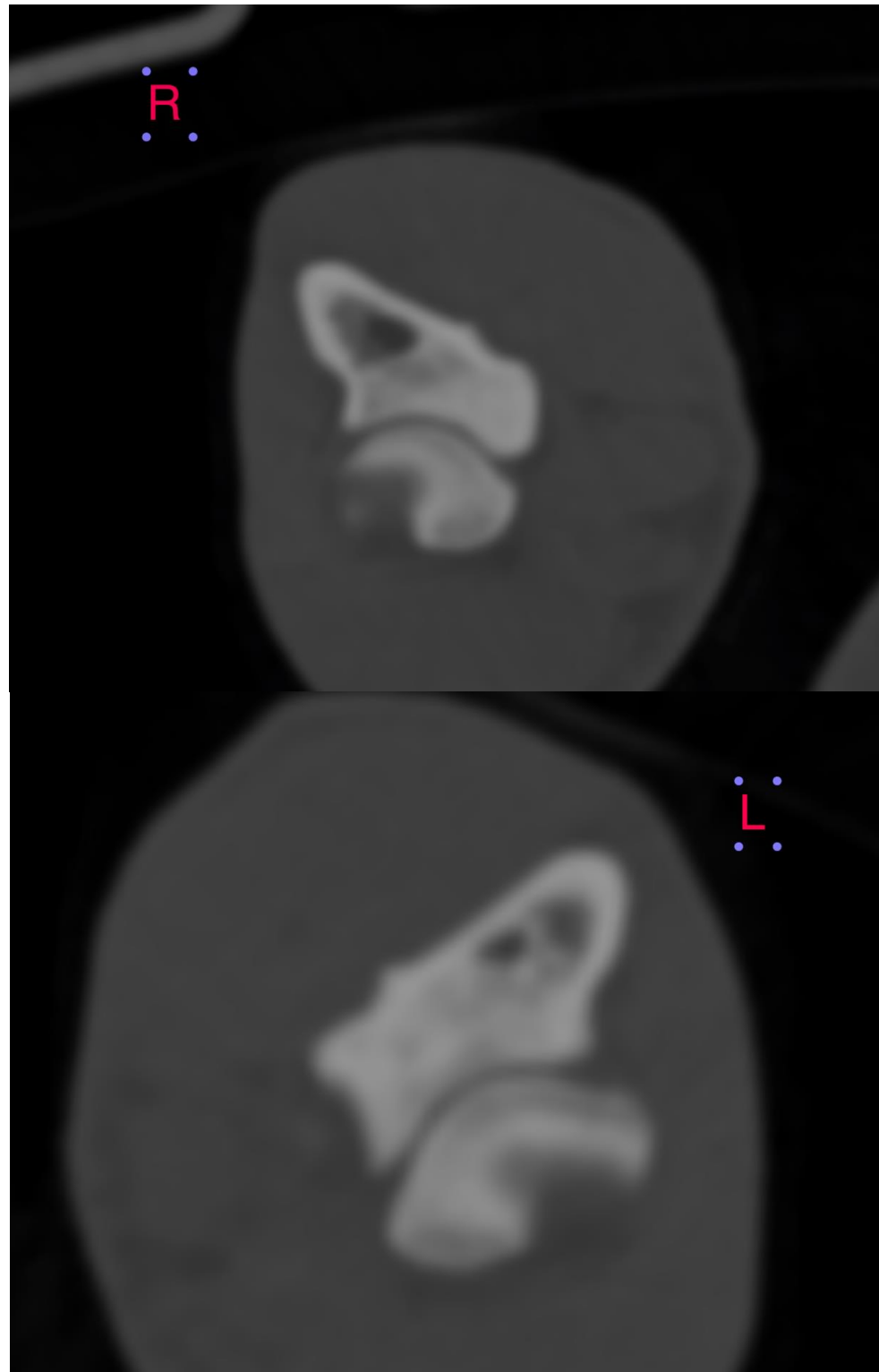
Dr. Kim Murphy

INVOICE

57871

DATE

4-18-23





PATIENT

Rigby Falls

SPECIES

Canine

BREED

Labrador Retriever

SEX

M

AGE

10 Months

INTERPRETED BY

Sebastian Jawinski,
German Board
Certified Vet
Specialist in
Diagnostic Imaging

HOSPITAL NAME

Animal Health
Partners

REFERRING VET

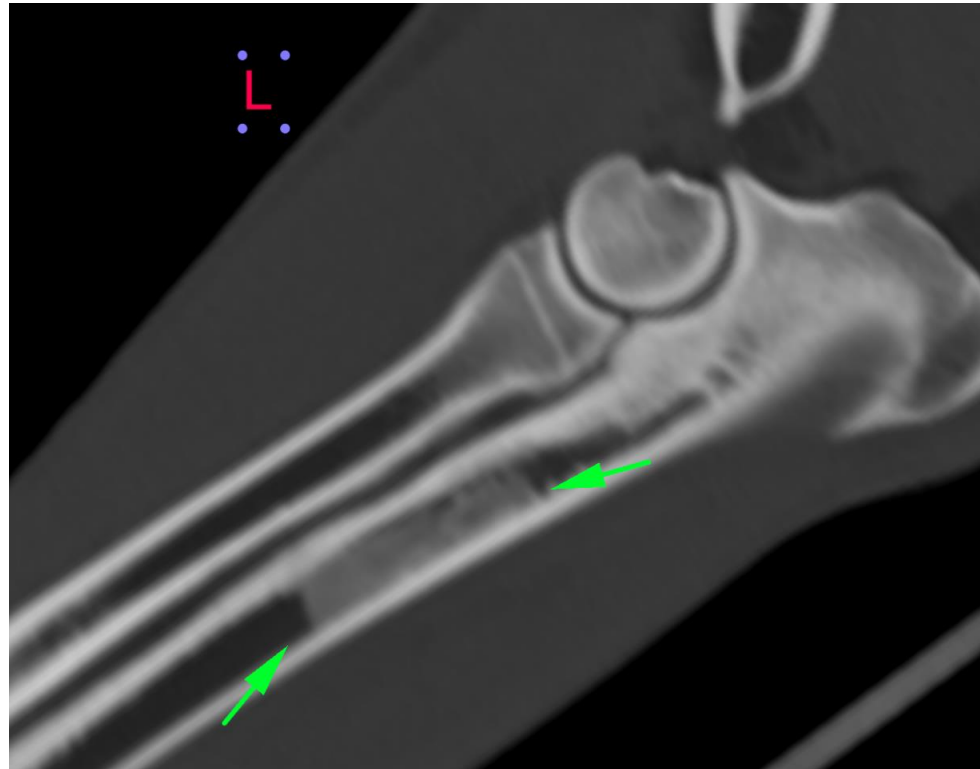
Dr. Kim Murphy

INVOICE

57871

DATE

4-18-23



The information and recommendations provided are based on the images presented by the referring veterinarian/sonographer. No evaluation can be communicated regarding pathology that was not visible in the image/video clips provided.

Thank you for this referral. If the clinical or image interpretation does not parallel your findings or if I can be of any further assistance, please contact me.

Sebastian Jawinski, German Board Certified Vet Specialist in Diagnostic Imaging
Sebastian.Jawinski@sonopath.com