



PATIENT PRESENTING CLINICAL SIGNS

Maxine Segal Liver mass evaluation to see if resectable.

COMPUTED TOMOGRAPHY OF THE ABDOMEN

SPECIES Pre/post contrast studies provided for review.

Canine **COMPUTED TOMOGRAPHIC FINDINGS**

BREED The liver shows two mass-like lesions. The first presents a lobar mass of the caudate lobe with an irregular surface and heterogeneous texture deviating the right kidney caudally and having broad-based contact to the portal vein and the caudal vena cava. The latter are inconspicuous without signs of an invasive issue. Maximum diameters measure approximately 7.8 x 6.6 cm. Vascular supply is liver-like and diffuse with multiple small vessels. Margins especially to the right medial lobe and the gallbladder are clearly defined. The gallbladder presents a small amount of hyperdense sludge without signs of cholestasis.

SEX Spayed Female The second lesion is found in the left lateral lobe being predominantly hypodense to the normal liver with a central accumulation of fluid. The lesion is located intra-lobar presenting sharp margins with an indicated ring-enhancement and multiple small vessels in the periphery. Maximum diameters measure 8.1 x 6.2 cm. This mass causes a marked caudo-dorsal deviation of the gastric axis.

AGE 11 Years, 11 Months The pancreas and spleen show normal findings in terms of size, surface, shape and contrast behavior.

INTERPRETED BY Unremarkable presentation of the bilaterally symmetrical kidneys.

Sebastian Jawinski, German Board Certified Vet Specialist in Diagnostic Imaging Adrenal glands are in normal limits.

As far as can be assessed, the stomach and all parts of intestine are regularly presented without any indication of a wall thickening or a mass.

HOSPITAL NAME Abdominal lymph nodes and abdominal vessels have no particular findings. Signs of peritoneal/retroperitoneal effusion or free gas are not recognized.
Mobile Pet Imaging

COMPUTED TOMOGRAPHIC DIAGNOSIS

- REFERRING VET**
- 1. Lobar liver mass right caudate lobe 7.8 x 6.6 cm
 - 2. Liver mass of the left lateral liver lobe 8.1 x 6.2 cm
- Meaux

INTERPRETATION OF THE FINDINGS & FURTHER RECOMMENDATIONS

INVOICE The mass of the right caudate lobe is an unspecific finding. Differentials include malignant neoplasia such as hepatocellular carcinoma and benign lesions as seen with hepatic adenomas and nodular hyperplasia. FNA/Biopsy are needed for further evaluation. As far as can be assessed margins to the adjacent structures and the other liver parts are clearly defined, surgical lobectomy therefore may be an option.

DATE
4-18-23



PATIENT

Maxine Segal

The lesion of the left lateral lobe could represent a more reactive/an inflammatory process due to its ring enhancing contrast uptake and the central fluid accumulation (central abscess/necrosis). Again, this cannot be finally assessed by CT. Malignant neoplasia is possible as well. Biopsy and aspiration of the fluid for further evaluation are recommended. Resection of both lesions could lead to a significant loss of functional liver tissue.

SPECIES

Canine

BREED

Goldendoodle

SEX

Spayed Female

AGE

11 Years, 11 Months

INTERPRETED BY

Sebastian Jawinski,
German Board
Certified Vet Specialist
in Diagnostic Imaging

HOSPITAL NAME

Mobile Pet Imaging

REFERRING VET

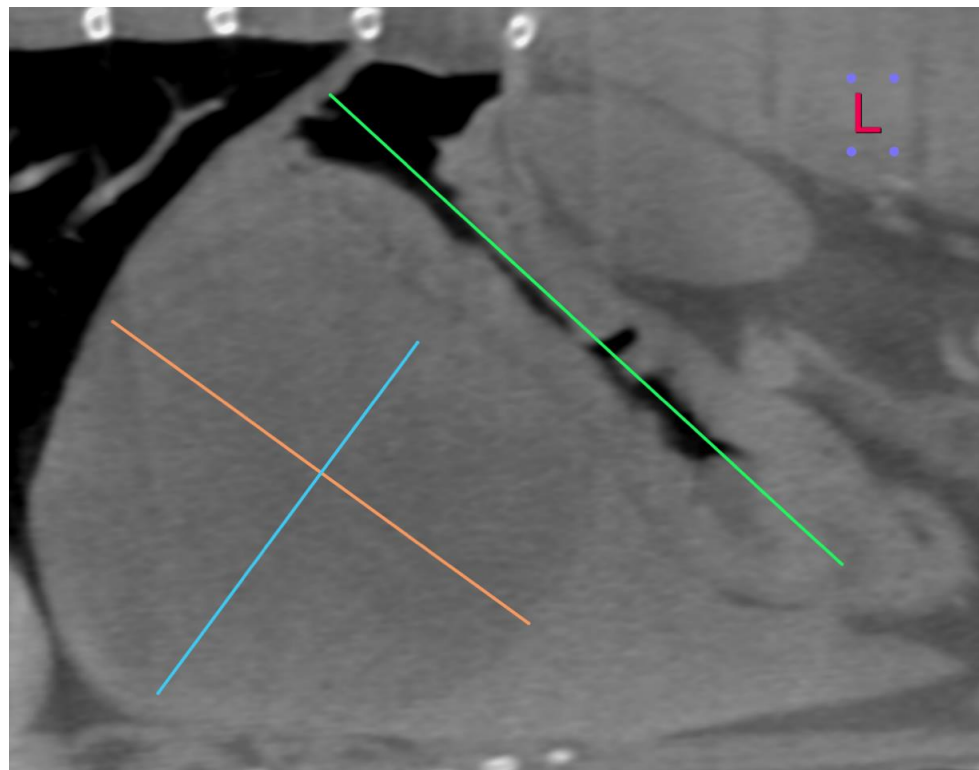
Meaux

INVOICE

57869

DATE

4-18-23





PATIENT

Maxine Segal

SPECIES

Canine

BREED

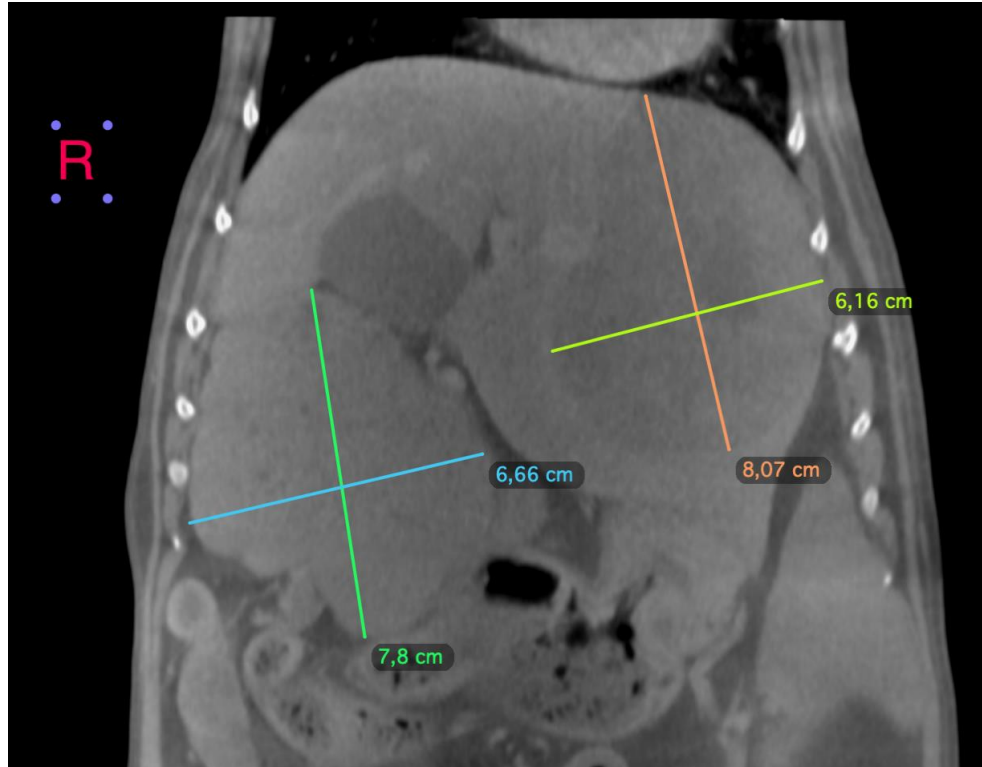
Goldendoodle

SEX

Spayed Female

AGE

11 Years, 11 Months



INTERPRETED BY

Sebastian Jawinski,
German Board
Certified Vet Specialist
in Diagnostic Imaging

HOSPITAL NAME

Mobile Pet Imaging

REFERRING VET

Meaux

INVOICE

57869

DATE

4-18-23

The information and recommendations provided are based on the images presented by the referring veterinarian/sonographer. No evaluation can be communicated regarding pathology that was not visible in the image/video clips provided.

Thank you for this referral. If the clinical or image interpretation does not parallel your findings or if I can be of any further assistance, please contact me.

Sebastian Jawinski, German Board Certified Vet Specialist in Diagnostic Imaging
Sebastian.Jawinski@sonopath.com