



PATIENT PRESENTING CLINICAL SIGNS

Ollie Gray
SPECIES Canine
 History: Ollie presented for 2-week history of yelping in pain when head/jaw being touched. Initially thought was due to ear infection, was treated at referring vet for otitis externa with topical ear medications and oral prednisolone. He then was presented to an emergency vet and the referring vet again for the same clinical signs. He is currently on Codeine and Paracetamol for pain relief but owner feel it is not helping. He was yelping in pain when owner tried to medicate him this morning. Repeated physical examination revealed no obvious pain response. CT of head and cervical spine performed.

COMPUTED TOMOGRAPHIC STUDY OF THE HEAD & CERVICAL SPINE

BREED Head

Cavoodle
 The neurocranium shows normal findings. Bony structures of the skull and the skull foramina of the cranial nerves are laterally symmetrical and inconspicuous. Both tympanic bullae are completely ventilated with a regular tympanic bulla wall.

SEX

Neutered Male
 External ear canals are ventilated in all sections, walls of the external ear canals, the adjacent temporomandibular joints and the nasopharyngeal meatus have no particular findings.

AGE

4

Frontal sinuses and the orbital contents are laterally symmetrical without evidence of a retrobulbar lesion. Nasal cavities are ventilated regularly. Conches look normal as well as the maxillary/mandibular teeth.

INTERPRETED BY

Sebastian Jawinski,
 German Board-Certified Vet Specialist
 in Diagnostic Imaging

Post contrast images show no pathological enhancement. Soft tissues of the head and neck are symmetrical and of homogeneous density, especially the medial retropharyngeal lymph nodes.

Cervical Spine

HOSPITAL NAME

Colyton VH

There are calcified nuclei of the intervertebral discs noted at the level of C4/5 and C5/6 without relevant signs of a compressive lesion. The intervertebral disc space C2/3 appears reduced with a moderate calcified disc extrusion which lies medial to left lateral to left foraminal and leads to a left sided and moderate compression of the spinal cord.

REFERRING VET

Daisy Fung

Presented bony structures of the spine are unremarkable with an inconspicuous harmonic course. The vertebral bodies are of regular density without signs of a lytic process. There is no evidence of a fracture and/or sub-/luxation. Paravertebral soft tissues are bilaterally symmetrical and inconspicuous.

INVOICE

21788

DATE

3/24/23

COMPUTED TOMOGRAPHIC DIAGNOSIS

- Moderate, calcified disc herniation C2/3 with moderate left sided compression of the spinal cord
- Degenerative changes C4/5 and C5/6
- Normal findings of the head



PATIENT

Ollie Gray

SPECIES

Canine

BREED

Cavoodle

SEX

Neutered Male

AGE

4

INTERPRETED BY

Sebastian Jawinski,
German Board-Certified Vet Specialist
in Diagnostic Imaging

HOSPITAL NAME

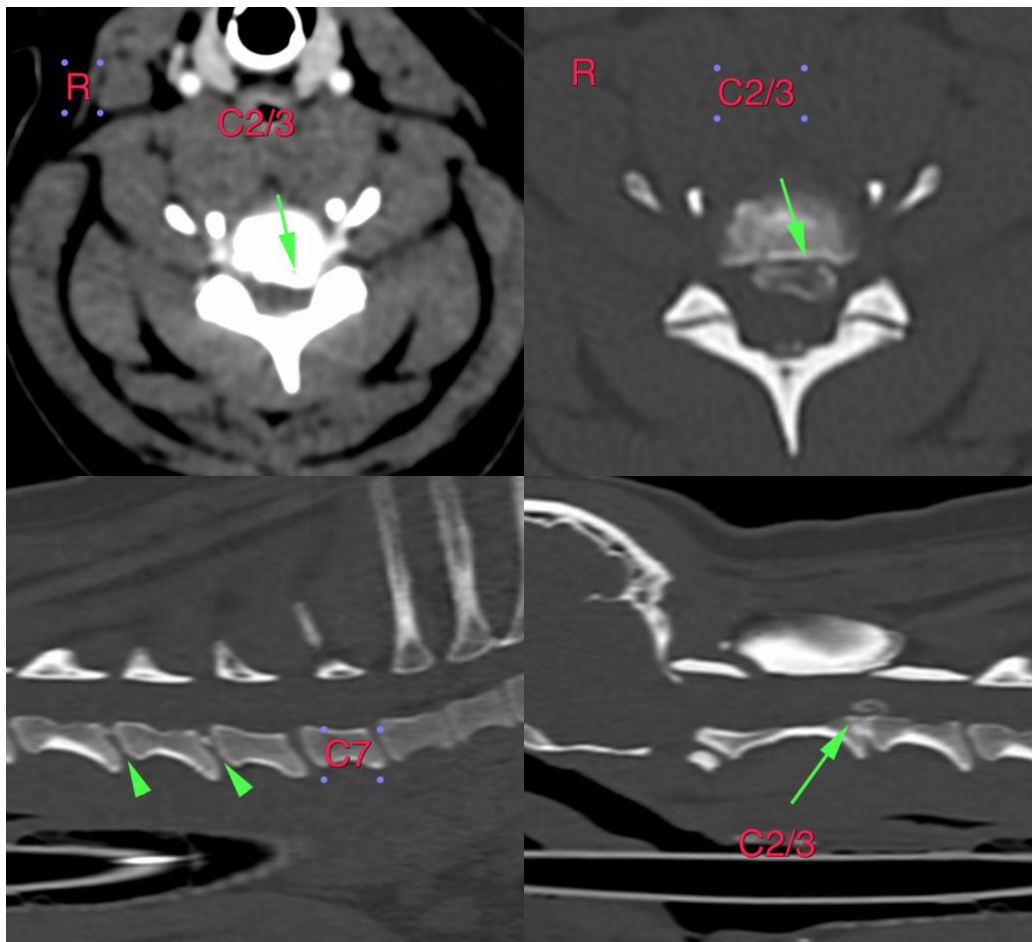
Colyton VH

REFERRING VET

Daisy Fung

INTERPRETATION OF THE FINDINGS & FURTHER RECOMMENDATIONS

The CT findings fully explain the reported patient's history. The herniated disc material is located medially to left laterally and at the level of the disc space of C2/3. Additional compression of the left nerve C2/3 root is possible. Decompressive surgery (ventral slot C2/3) should be considered if conservative therapy does not improve the clinical symptoms.



The information and recommendations provided are based on the images presented by the referring veterinarian. No evaluation can be communicated regarding pathology that was not visible in the image/video clips provided.

INVOICE

21788

DATE

3/24/23

Thank you for this referral. If the clinical or image interpretation does not parallel your findings or if I can be of any further assistance please contact me.



PATIENT Sebastian Jawinski, German Board Certified Vet Specialist in Diagnostic Imaging
info@sonopath.com

Ollie Gray

SPECIES

Canine

BREED

Cavoodle

SEX

Neutered Male

AGE

4

INTERPRETED BY

Sebastian Jawinski,
German Board-
Certified Vet Specialist
in Diagnostic Imaging

HOSPITAL NAME

Colyton VH

REFERRING VET

Daisy Fung

INVOICE

21788

DATE

3/24/23