



PATIENT PRESENTING CLINICAL SIGNS

Fifi Naidoo Owner report stiffness RHL and occasionally skips PE: Mild pain in LD otherwise all palpated normal previous TPLO in jan 2023
Abnormal PE/Chem/CBC/UA Results: elevated liver function tests

SPECIES RADIOGRAPHIC FINDINGS

Canine Caudal lumbar spine:

The presented spine shows a harmonic course with inconspicuous vertebral bodies and a regular lumbosacral transition without signs of relevant degenerative changes. There are no signs of a lytic or sclerotic process.

BREED

American Staffordshire Terrier

Pelvis/coxofemoral joints:

The bony structures of the pelvis are unremarkable. There is no evidence of a lytic process noted. The coxofemoral joints on both sides reveal prominent remodeling of the femoral head/neck with smooth and even new bone formation. The acetabular rim presents increased and uneven sclerosis. There are no signs of a lytic process. There is no evidence of a fracture or subluxation.

SEX

Female

Stifles:

The right stifle presents a status after previous TPLO in January 2023. The osteotomy gap is still prominent with mildly rounded edges and initial bony closure of the proximal parts of the osteotomy. The metallic implants (screws and plate) appear inconspicuous without signs of a reactive process. Lysis and/or relevant periosteal reactions are not identified.

AGE

9

INTERPRETED BY

Sebastian Jawinski,
German Board Certified Vet Specialist in Diagnostic Imaging

The right stifle presents osteophytes at all joint levels including the tip of the patella, the femoral condyles and the fabellae as well as the tibial plateau. The patella has a normal position. No other osseous abnormalities are detected.

HOSPITAL NAME

Animal Surgical Center

The left stifle shows mild osteophytic changes at the level of the medial femoral condyle and appears unremarkable apart from that.

RADIOGRAPHIC DIAGNOSIS

- Moderate, bilateral osteoarthritis of the coxofemoral joints
- Moderate osteoarthritis of the right stifle
- Mild osteoarthritis of the left stifle

REFERRING VET

North Shore Animal Hospital

INTERPRETATION OF THE FINDINGS & FURTHER RECOMMENDATIONS

The changes detected at the level of the coxofemoral joints, and the right stifle can explain the described hind lameness/stiffness. However, these changes are chronic and degenerative issues. Signs of an aggressive bone lesion and/or a florid inflammatory process are not detected. The present osteotomy gap of the proximal tibia is still within normal limits. A radiographic follow up should be performed in 4 weeks to exclude a delayed healing.

INVOICE

57334

DATE

3-21-23



PATIENT

Fifi Naidoo

SPECIES

Canine

BREED

American
Staffordshire Terrier

SEX

Female

AGE

9

INTERPRETED BY

Sebastian Jawinski,
German Board
Certified Vet
Specialist in
Diagnostic Imaging

HOSPITAL NAME

Animal Surgical
Center

REFERRING VET

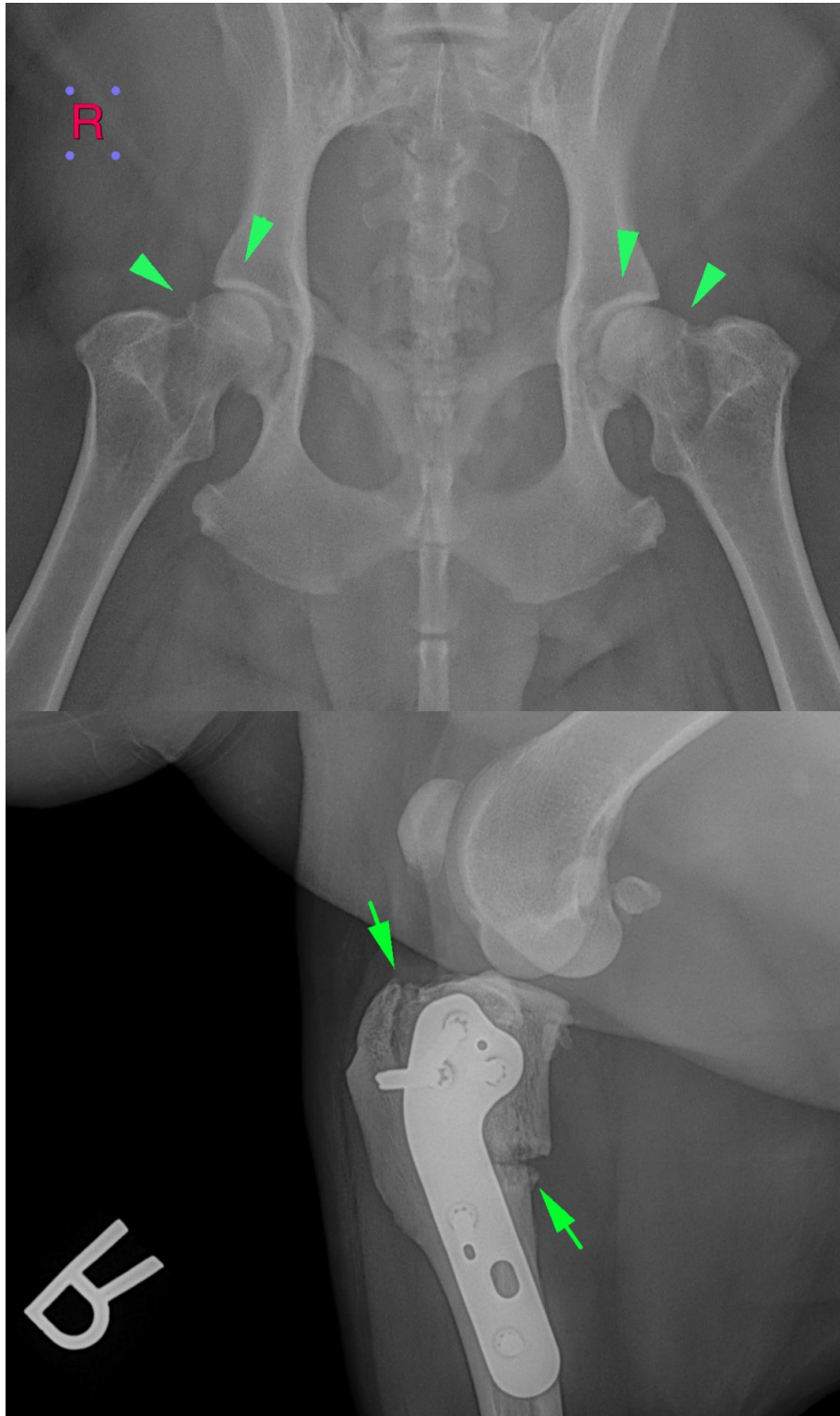
North Shore Animal
Hospital

INVOICE

57334

DATE

3-21-23





PATIENT

Fifi Naidoo

SPECIES

Canine

BREED

American
Staffordshire Terrier

SEX

Female

AGE

9

INTERPRETED BY

Sebastian Jawinski,
German Board
Certified Vet
Specialist in
Diagnostic Imaging

HOSPITAL NAME

Animal Surgical
Center

REFERRING VET

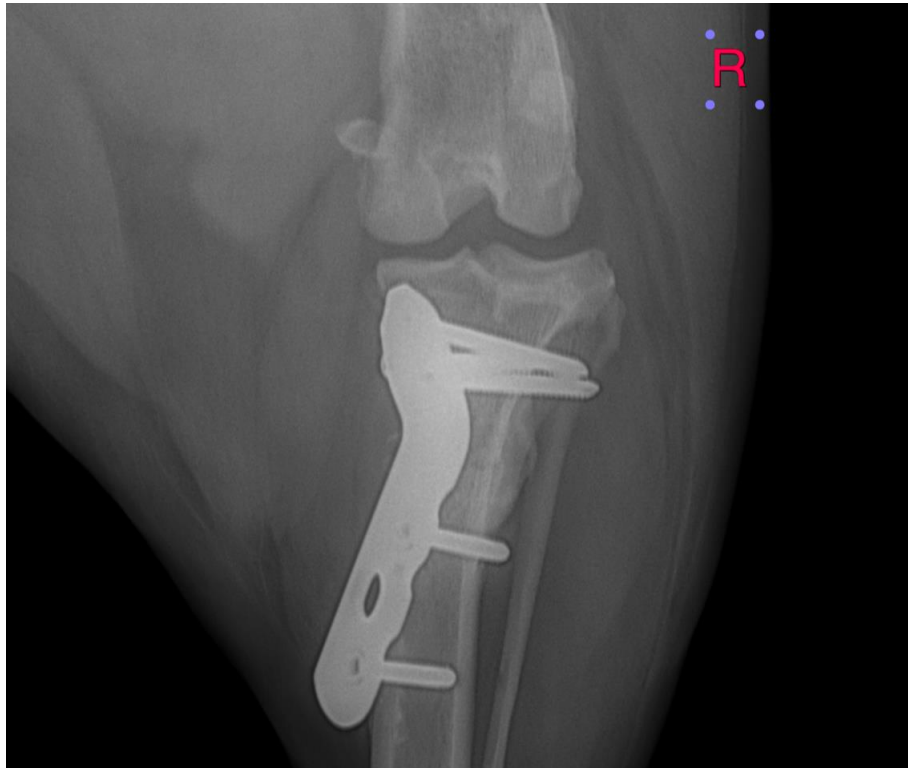North Shore Animal
Hospital

INVOICE

57334

DATE

3-21-23



The information and recommendations provided are based on the images presented by the referring veterinarian/sonographer. No evaluation can be communicated regarding pathology that was not visible in the image/video clips provided.

Thank you for this referral. If the clinical or image interpretation does not parallel your findings or if I can be of any further assistance, please contact me.

Sebastian Jawinski, German Board Certified Vet Specialist in Diagnostic Imaging
Sebastian.Jawinski@sonopath.com