



PATIENT

Gaia Belarbi

SPECIES

Feline

BREED

Scottish Fold

SEX

FS

AGE

8M

WEIGHT

6.2lbs

INTERPRETED BY

Sebastian Jawinski,
German Board
Certified Vet Specialist
in Diagnostic Imaging

IMAGING PERFORMED BY

Sara Hansen

HOSPITAL NAME

VCA Vitality

REFERRING VET

Dr Burgt

INVOICE

74254

DATE

3-18-26

PRESENTING CLINICAL SIGNS

- Radiographic Findings
- from AIS report:
- There are individual lateral and craniocaudal views of each of the forelimbs, the hind limbs, and a VD view of the pelvis available for interpretation. 7 images.
- Right forelimb: There are no osseous or soft tissue abnormalities noted on this study.
- Left forelimb: There are no osseous or soft tissue abnormalities noted on this study.
- The cervical, thoracic, and visible lumbar spine are normal. The visible thorax is normal. The serosal detail, gastric axis, gastrointestinal tract, liver, spleen, kidneys, and urinary bladder are normal.
- Right hindlimb: There are gas lucencies in the caudal axial proximal hindlimb musculature. The distal tibial physis is partially visible. The long bones, stifle and tarsal joints are otherwise normal. The digits visible are normal.
- Left hindlimb: The distal tibial and fibular are poorly visible; and similar in appearance to the contralateral limb. On the craniocaudal view, there is superimposition of the distal fibula. The long bones, stifle, remainder of the tarsus and digits are normal. The soft tissues are normal.
- Assessment:
- 1. Gas lucencies proximal axial right hindlimb: Trauma, including bite wounds or abscessation from migrating foreign bodies or parasites, is possible. Recommend an ultrasound by an experienced sonographer for further evaluation, especially if the draining tract is evident.
- 2. Normal musculoskeletal study: Consistent with normal.

Abnormal PE/Chem/CBC/UA Results: Clinical Exam Findings: Current medication's none

ULTRASONOGRAPHIC FINDINGS

Right Hindlimb

The displayed bony surfaces are inconspicuous. Signs of an aggressive lesion and/or relevant periosteal changes are not noted.

The presented musculature is clearly defined with a normal fibrillar pattern. There is one muscle belly showing mild diffuse, hyperechoic changes.

Relevant fluid accumulations and/or gas artifacts are not noted. The parts of the abdominal wall are inconspicuous including the presented parts of the abdominal organs (urinary bladder and intestinal loops).

ULTRASONOGRAPHIC DIAGNOSIS

- Mild diffuse, hyperechoic changes muscle belly
- No evidence of an active inflammatory lesion



PATIENT

Gaia Belarbi

SPECIES

Feline

BREED

Scottish Fold

SEX

FS

AGE

8M

WEIGHT

6.2lbs

INTERPRETED BY

Sebastian Jawinski,
German Board
Certified Vet Specialist
in Diagnostic Imaging

IMAGING PERFORMED BY

Sara Hansen

HOSPITAL NAME

VCA Vitality

REFERRING VET

Dr Burgt

INVOICE

74254

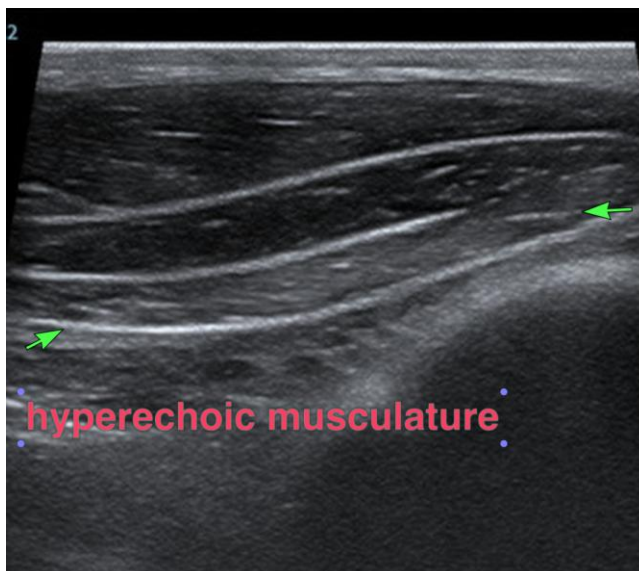
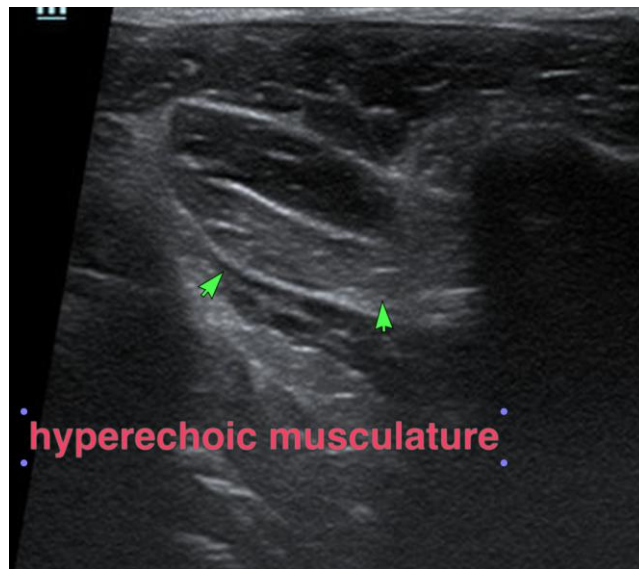
DATE

3-18-26

INTERPRETATION OF THE FINDINGS & FURTHER RECOMMENDATIONS

The sonographic study shows normal findings of the presented musculature, the abdominal wall and the presented abdominal organs except for mild hyperechoic changes in one muscle belly. These could be artificial due to sound beam angulation, and reverberation effects. Differentials include fibrous, posttraumatic changes with scar tissue formation and post-inflammatory changes as seen with residual hematoma/myositis.

Signs of an abscess formation or relevant phlegmon are not noted. Foreign material is not detected.





PATIENT

Gaia Belarbi

SPECIES

Feline

BREED

Scottish Fold

SEX

FS

AGE

8M

WEIGHT

6.2lbs

INTERPRETED BY

Sebastian Jawinski,
German Board
Certified Vet Specialist
in Diagnostic Imaging

IMAGING PERFORMED BY

Sara Hansen

HOSPITAL NAME

VCA Vitality

REFERRING VET

Dr Burgt

INVOICE

74254

DATE

3-18-26

The information and recommendations provided are based on the images presented by the referring veterinarian/sonographer. No evaluation can be communicated regarding pathology that was not visible in the image/video clips provided.

Thank you for this referral. If the clinical or image interpretation does not parallel your findings or if I can be of any further assistance, please contact me.

Sebastian Jawinski, German Board Certified Vet Specialist in Diagnostic Imaging
info@sonopath.com