



PATIENT

Frankie Horvarth

SPECIES

Feline

BREED

DSH

SEX

MN

AGE

6

WEIGHT

7

INTERPRETED BY

Sebastian Jawinski,
German Board
Certified Vet Specialist
in Diagnostic Imaging

IMAGING PERFORMED BY

Eamon

HOSPITAL NAME

Belconnen Veterinary
Centre

REFERRING VET

Eamon

INVOICE

74227

DATE

3-16-26

PRESENTING CLINICAL SIGNS

- coughing blood

Abnormal PE/Chem/CBC/UA Results: cbc chem t4 bal/culture pending

COMPUTED TOMOGRAPHY OF THE HEAD, THORAX, & ABDOMEN

Pre/post contrast studies are provided for review.

COMPUTED TOMOGRAPHIC FINDINGS

Head:

The neurocranium shows normal findings. The bony structures of the skull and the skull foramina of the cranial nerves are laterally symmetrical and inconspicuous. Both tympanic bullae are completely ventilated with a regular tympanic bulla wall. The external ear canals are ventilated in all sections with inconspicuous walls. The temporomandibular joints and the nasopharyngeal meatus have no particular findings.

Both frontal sinuses and the orbital contents are laterally symmetrical without evidence of a retro-/bulbar lesion.

The nasal cavities are ventilated regularly. Conches appear normal. The maxillary/mandibular teeth present marked degenerative and resorptive changes at multiple levels (s. for example residual root 104, resorptive root 404).

Post contrast images show no pathological enhancement. The soft tissues of the head and neck are symmetrical and inconspicuous, especially the mandibular and medial retropharyngeal lymph nodes are unremarkable.

Thorax:

The trachea and bronchi do not show specific findings. The pulmonary structures are inconspicuous with mild atelectasis in the cranial parts of both sides. There is a subtle increase in the broncho-interstitial density throughout all lung parts. Nodular, focal or relevant diffuse pulmonary changes are not noted.

Free pleural fluid is not recognized. The mediastinal organs, especially the mediastinal lymph nodes, do not show particular findings. The thoracic borders are intact, including the diaphragm.

Abdomen:

Both kidneys show mild calcifications in the renal pelvis and the collateral recesses. The abdominal organs are inconspicuous apart from that. Preperitoneal fluid is not noted. The abdominal vessels and lymph nodes are within normal limits.



PATIENT

Frankie Horvarth

SPECIES

Feline

BREED

DSH

SEX

MN

AGE

6

WEIGHT

7

INTERPRETED BY

Sebastian Jawinski,
German Board
Certified Vet Specialist
in Diagnostic Imaging

IMAGING PERFORMED BY

Eamon

HOSPITAL NAME

Belconnen Veterinary
Centre

REFERRING VET

Eamon

INVOICE

74227

DATE

3-16-26

COMPUTED TOMOGRAPHIC DIAGNOSIS

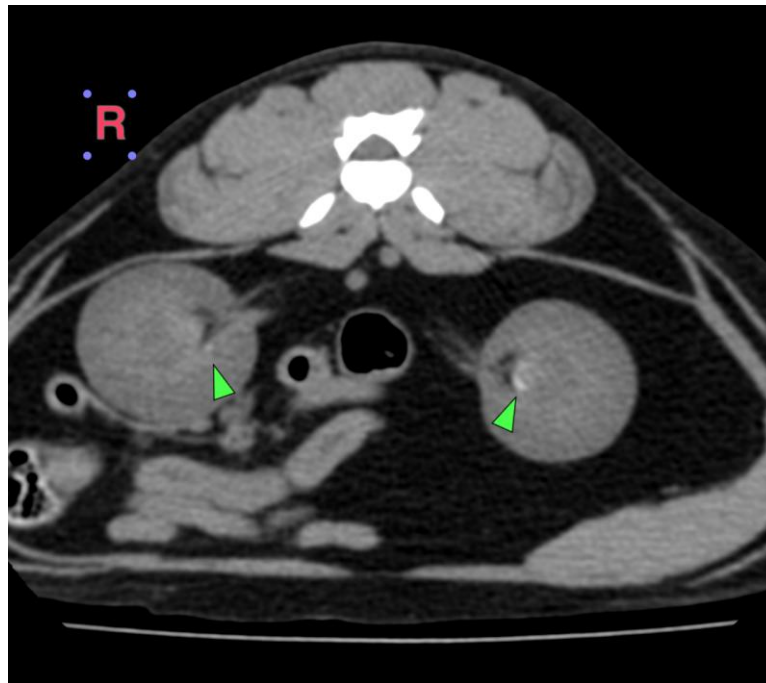
- Resorptive lesion maxillary and mandibular teeth
- Subtle broncho-interstitial lung pattern

Incidental findings:

- Bilateral nephrocalcinosis

INTERPRETATION OF THE FINDINGS & FURTHER RECOMMENDATIONS

In the absence of other inflammatory signs, the presented changes of the teeth may explain the reported patient's history. With exception of the teeth, there are no signs of relevant inflammation or even neoplasia within the presented airways. This does not fully exclude inflammatory issues. The subtle broncho-interstitial pattern is an indirect sign for more chronic and subtle inflammation. Endoscopic evaluation and sampling could be performed next for further assessment. Resection of all teeth could be discussed.





PATIENT

Frankie Horvarth

SPECIES

Feline

BREED

DSH

SEX

MN

AGE

6

WEIGHT

7

INTERPRETED BY

Sebastian Jawinski,
German Board
Certified Vet Specialist
in Diagnostic Imaging

IMAGING PERFORMED BY

Eamon

HOSPITAL NAME

Belconnen Veterinary
Centre

REFERRING VET

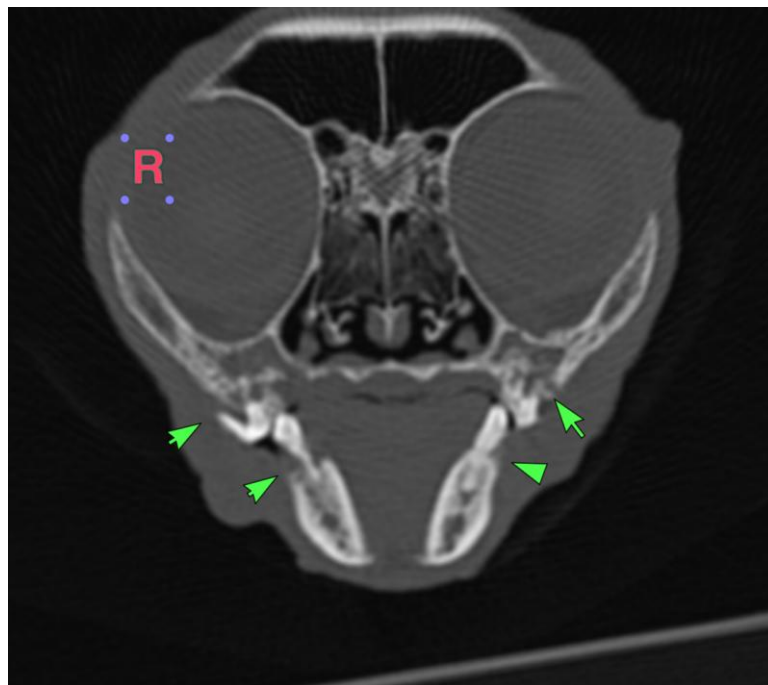
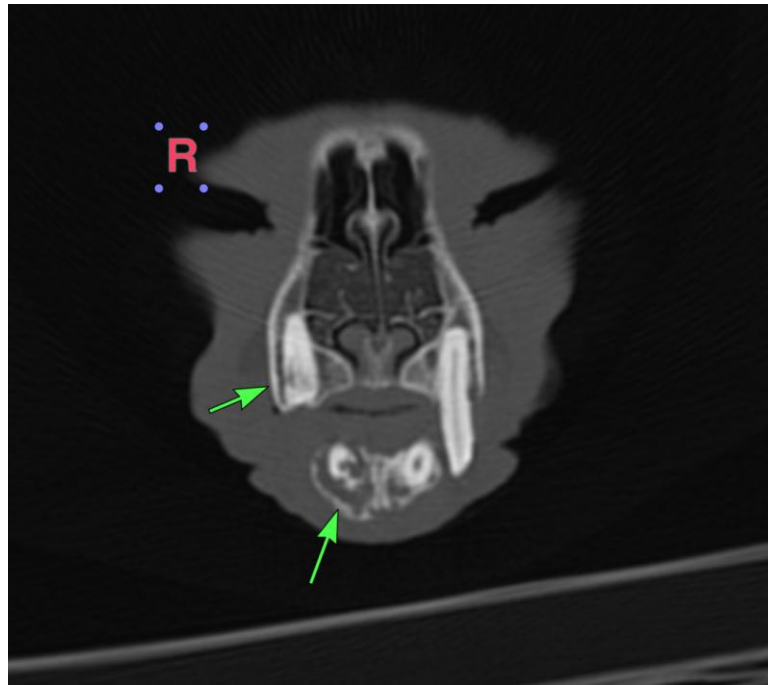
Eamon

INVOICE

74227

DATE

3-16-26





PATIENT

Frankie Horvarth

SPECIES

Feline

BREED

DSH

SEX

MN

AGE

6

WEIGHT

7

INTERPRETED BY

Sebastian Jawinski,
German Board
Certified Vet Specialist
in Diagnostic Imaging

IMAGING PERFORMED BY

Eamon

HOSPITAL NAME

Belconnen Veterinary
Centre

REFERRING VET

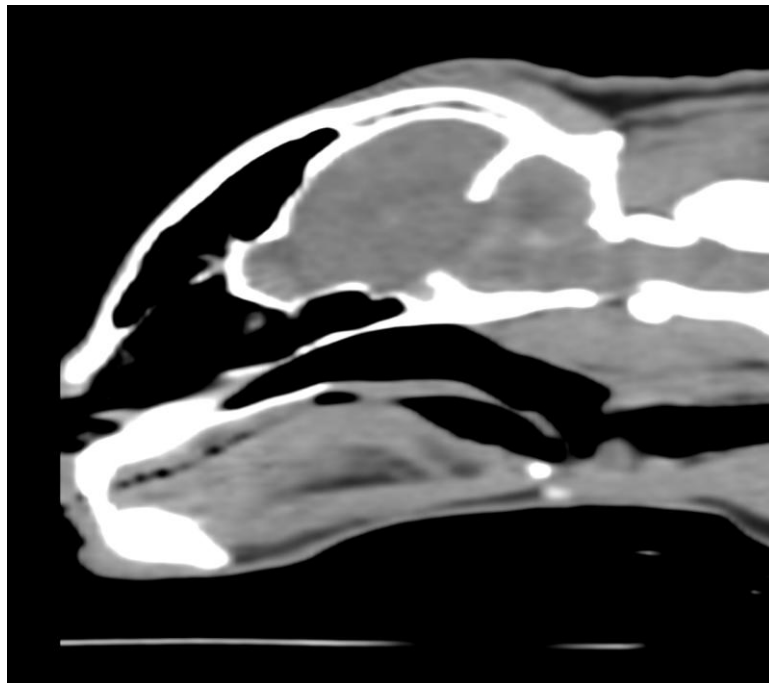
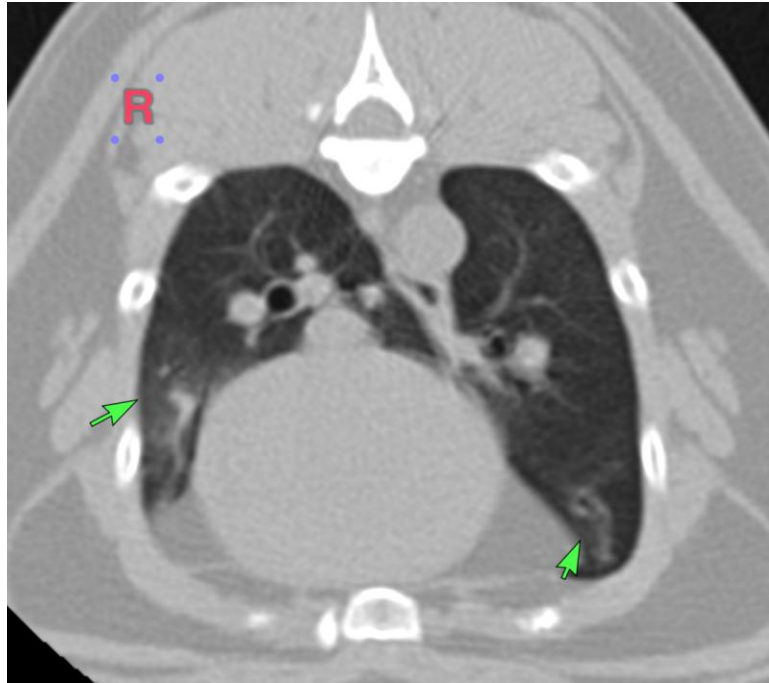
Eamon

INVOICE

74227

DATE

3-16-26





PATIENT

Frankie Horvarth

SPECIES

Feline

BREED

DSH

SEX

MN

AGE

6

WEIGHT

7

INTERPRETED BY

Sebastian Jawinski,
German Board
Certified Vet Specialist
in Diagnostic Imaging

IMAGING PERFORMED BY

Eamon

HOSPITAL NAME

Belconnen Veterinary
Centre

REFERRING VET

Eamon

INVOICE

74227

DATE

3-16-26

The information and recommendations provided are based on the images presented by the referring veterinarian/sonographer. No evaluation can be communicated regarding pathology that was not visible in the image/video clips provided.

Thank you for this referral. If the clinical or image interpretation does not parallel your findings or if I can be of any further assistance, please contact me.

Sebastian Jawinski, German Board Certified Vet Specialist in Diagnostic Imaging
info@sonopath.com