



PATIENT

Ellie Mount

SPECIES

Canine

BREED

Mixed

SEX

Female Spayed

AGE

8Y

WEIGHT

54.6

INTERPRETED BY

Sebastian Jawinski,
German Board
Certified Vet Specialist
in Diagnostic Imaging

IMAGING PERFORMED BY

Bill McGee, DVM,
DABVP

HOSPITAL NAME

Bridgeport Animal
Hospital PLLC

REFERRING VET

Chisholm Ridge Pet
Hospital

INVOICE

74219

DATE

3-16-26

PRESENTING CLINICAL SIGNS

- history of left sided epistaxis
- growth over the left frontal sinus

COMPUTED TOMOGRAPHY OF THE HEAD

Pre/post contrast studies are provided for review.

COMPUTED TOMOGRAPHIC FINDINGS

There is a soft tissue dense mass noted originating in the caudal and dorsal parts of the left nasal cavity, expanding into the left frontal sinus and crossing the midline to the right frontal sinus. There are osteolytic changes noted at multiple levels with irregular/unstructured periosteal reactions and calcifications, including the frontal bone with an expansion of the lesion into the subcutaneous region, the maxillary bone with changes in the left orbit and the cribriform plate with the mass entering the cranial vault. There are an increased meningeal enhancement and compression of the olfactory bulb on the left side noted.

The neurocranium is inconspicuous apart from that. The soft tissues of the head and neck present normal findings with regular mandibular and retropharyngeal lymph nodes.

COMPUTED TOMOGRAPHIC DIAGNOSIS

- Suspected aggressive and invasive lesion left nasal cavity/frontal sinus

INTERPRETATION OF THE FINDINGS & FURTHER RECOMMENDATIONS

The mass-like margination on the left, the osteolysis of the bony structures and the inhomogeneous contrast uptake speak for an aggressive lesion that matches criteria for a malignant neoplasia. I would rule out advanced inflammatory issues. Biopsy/swap sampling are needed for further differentiation.

Differentials include but are not limited to nasal carcinoma, squamous cell carcinoma and lymphoma. The destruction of the cribriform plate and the invasion of the cranial vault are thought to be of bad prognosis.



PATIENT

Ellie Mount

SPECIES

Canine

BREED

Mixed

SEX

Female Spayed

AGE

8Y

WEIGHT

54.6

INTERPRETED BY

Sebastian Jawinski,
German Board
Certified Vet Specialist
in Diagnostic Imaging

IMAGING PERFORMED BY

Bill McGee, DVM,
DABVP

HOSPITAL NAME

Bridgeport Animal
Hospital PLLC

REFERRING VET

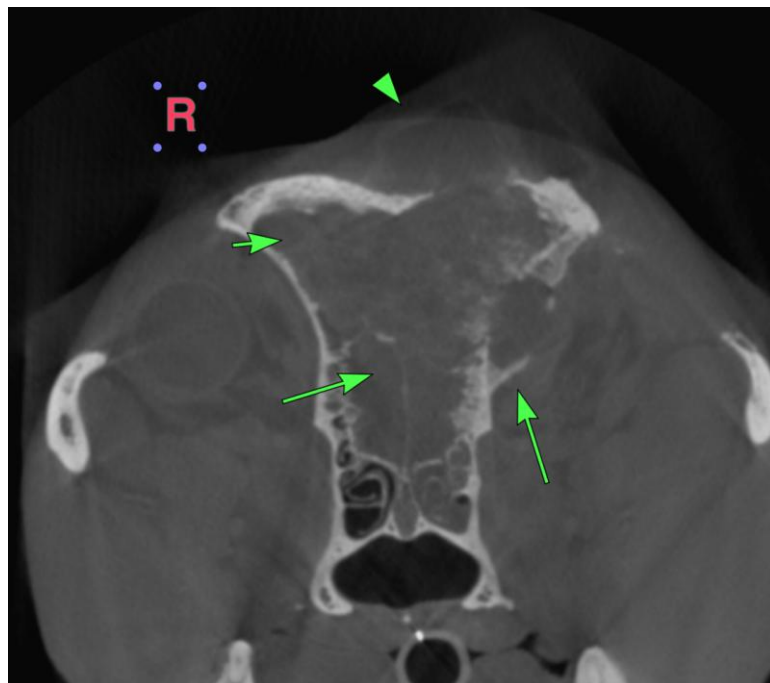
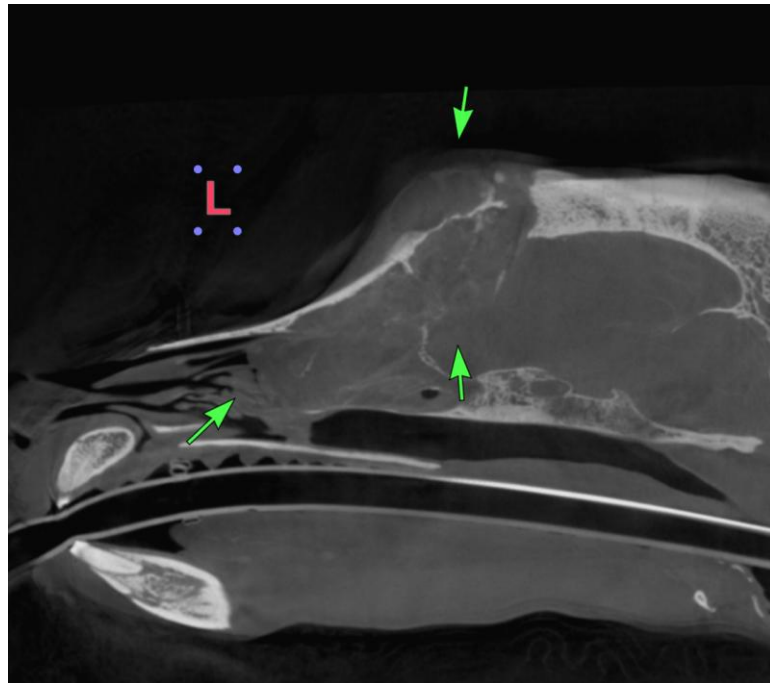
Chisholm Ridge Pet
Hospital

INVOICE

74219

DATE

3-16-26





PATIENT

Ellie Mount

SPECIES

Canine

BREED

Mixed

SEX

Female Spayed

AGE

8Y

WEIGHT

54.6

INTERPRETED BY

Sebastian Jawinski,
German Board
Certified Vet Specialist
in Diagnostic Imaging

IMAGING PERFORMED BY

Bill McGee, DVM,
DABVP

HOSPITAL NAME

Bridgeport Animal
Hospital PLLC

REFERRING VET

Chisholm Ridge Pet
Hospital

INVOICE

74219

DATE

3-16-26

The information and recommendations provided are based on the images presented by the referring veterinarian/sonographer. No evaluation can be communicated regarding pathology that was not visible in the image/video clips provided.

Thank you for this referral. If the clinical or image interpretation does not parallel your findings or if I can be of any further assistance, please contact me.

Sebastian Jawinski, German Board Certified Vet Specialist in Diagnostic Imaging
info@sonopath.com