

PATIENT

Brody 11th Hour

SPECIES

Canine

BREED

Collie

SEX

Neutered Male

AGE

6 Years

WEIGHT

61 pounds

INTERPRETED BY

Sebastian Jawinski,
German Board
Certified Vet Specialist
in Diagnostic Imaging

IMAGING PERFORMED BY

Kerri Becker

HOSPITAL NAME

All Creatures Great &
Small Denville

REFERRING VET

Dr. Silas Ashmore

INVOICE

14334

DATE

03/13/26

PRESENTING CLINICAL SIGNS

- Limping R back leg, so painful right knee, cranial draw test partial rupture ACL

ULTRASONOGRAPHIC EXAMINATION OF THE RIGHT & LEFT STIFLE

ULTRASONOGRAPHIC FINDINGS

Both stifles present mild osteophytic reactions at the level of the distal patella. The suprapatellar region and the infrapatellar views are inconspicuous without signs of relevant joint effusion and/or changes of the echogenicity of the infrapatellar fat body.

The course and thickness of the anterior cruciate ligament is inconspicuous on the left side.

In comparison to the left, the right one appears thickened and mildly irregular. A significant halo is not noted. A hyperechoic stump is not recognized. The bony surfaces of the femur and tibia are inconspicuous, especially in the medial and lateral aspects.

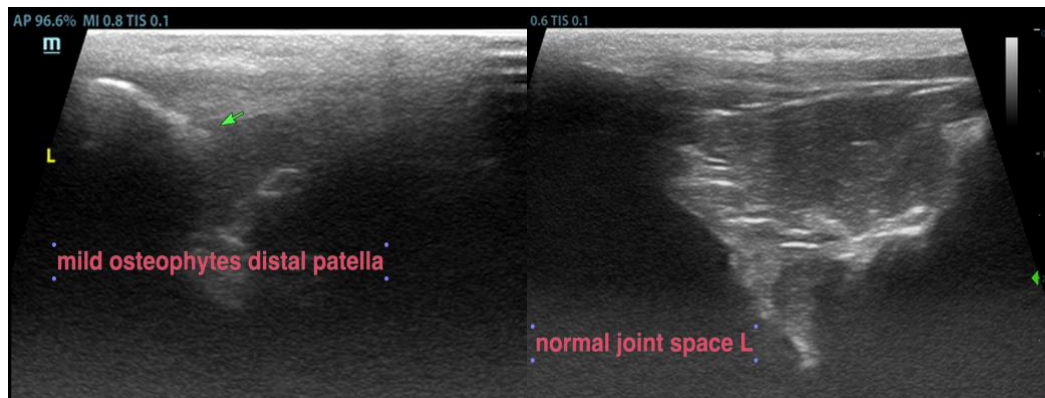
The displayed parts of the menisci are inconspicuous.

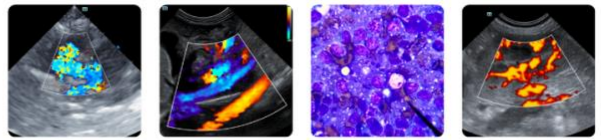
ULTRASONOGRAPHIC DIAGNOSIS

- Mild thickening of the right ACL
- Bilateral, subtle to mild degenerative changes distal patella

INTERPRETATION OF THE FINDINGS & FURTHER RECOMMENDATIONS

The assumed mild thickening of the right ACL could represent edema in the course of the ligament and/or partial rupture. Typical degenerative findings, joint effusion and the hyperechoic stump, which would be expected with complete rupture, are not identified. With that, the findings of the right stifle are of questionable clinical relevance.





PATIENT

Brody 11th Hour

SPECIES

Canine

BREED

Collie

SEX

Neutered Male

AGE

6 Years

WEIGHT

61 pounds

INTERPRETED BY

Sebastian Jawinski,
German Board
Certified Vet Specialist
in Diagnostic Imaging

**IMAGING
PERFORMED BY**

Kerri Becker

HOSPITAL NAME

All Creatures Great &
Small Denville

REFERRING VET

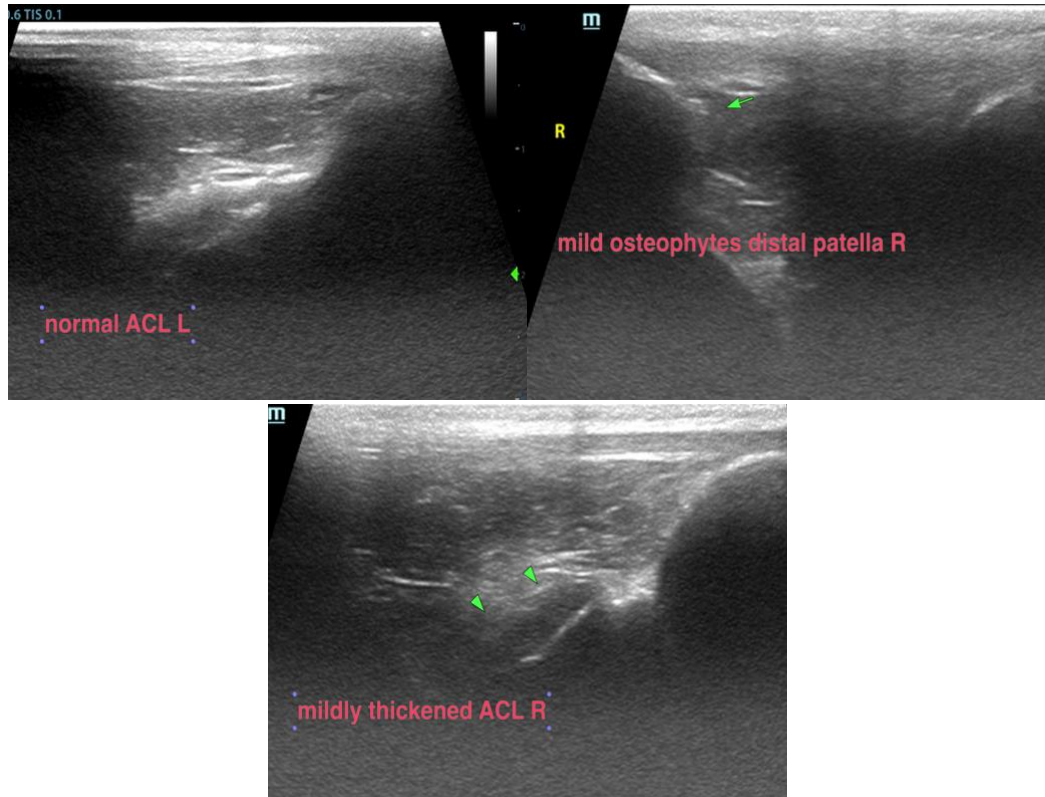
Dr. Silas Ashmore

INVOICE

14334

DATE

03/13/26



The information and recommendations provided are based on the images presented by the referring veterinarian/sonographer. No evaluation can be communicated regarding pathology that was not visible in the image/video clips provided.

Thank you for this referral. If the clinical or image interpretation does not parallel your findings or if I can be of any further assistance, please contact me.

Sebastian Jawinski, German Board-Certified Vet Specialist in Diagnostic Imaging
info@sonopath.com