



## PATIENT

Stitch Avison

## SPECIES

Canine

## BREED

French Bulldog

## SEX

F

## AGE

9

## WEIGHT

13

## INTERPRETED BY

Sebastian Jawinski,  
German Board  
Certified Vet Specialist  
in Diagnostic Imaging

## IMAGING PERFORMED BY

Brandan Costas

## HOSPITAL NAME

Animal Trust - Bolton

## REFERRING VET

Brandan Costas

## INVOICE

74118

## DATE

3-10-26

## PRESENTING CLINICAL SIGNS

- Ongoing LHL lameness, osteolytic lesion in rads visible on distal femur.
- Possible neoplasia?

## COMPUTED TOMOGRAPHY OF THE PELVIS & STIFLES

Pre/post contrast studies are provided for review.

## COMPUTED TOMOGRAPHIC FINDINGS

The display parts of the right hindlimb are inconspicuous with regular bone densities and an unremarkable coxofemoral joint. The right stifle indicates a lateral patella luxation with mild osteophytic reactions at all joint levels.

The left side presents a mixed pattern of osteolytic and osteoproliferative changes at the level of the distal femur with soft tissue swelling and contrast enhancement in the area of the lateral gastrocnemius muscle insertion. The sesamoid bone show marked new bone formation. Relevant joint effusion is not noted.

The intra-pelvic soft tissues are inconspicuous, especially the medial inguinal lymph nodes. The display parts of the lumbar spine and lumbosacral transitions show a moderate disc protrusion of L7 (L8?) -S1 with mild compression of the cauda fibers.

There are breed-expected malformations of the sacral bone and tail recognized.

## COMPUTED TOMOGRAPHIC DIAGNOSIS

- Suspected mildly aggressive bone lesion distal left femur
- Mild osteoarthritis right stifle with indicated lateral patella luxation
- Degenerative changes lumbosacral transition with mild compression of the equine cauda L7-S1

## INTERPRETATION OF THE FINDINGS & FURTHER RECOMMENDATIONS

The CT findings of the left distal femur are suspicious for a mildly aggressive bone lesion as seen with post-traumatic changes (bone-bruise, microfractures), osteomyelitis and bone neoplasia. However, this is a typical localization for osteosarcoma/chondrosarcoma, which I would favor as a differential diagnosis. Final assessment is not possible with CT. As far as can be assessed, there are no signs of regional metastases.

For further assessment, biopsy and histopathology are needed. Thoracic screening is recommended.

The other findings (right stifle and lumbosacral transition) must be correlated with the clinical presentation and are consistent with chronic degenerative changes.



## PATIENT

Stitch Avison

## SPECIES

Canine

## BREED

French Bulldog

## SEX

F

## AGE

9

## WEIGHT

13

## INTERPRETED BY

Sebastian Jawinski,  
German Board  
Certified Vet Specialist  
in Diagnostic Imaging

## IMAGING PERFORMED BY

Brandan Costas

## HOSPITAL NAME

Animal Trust - Bolton

## REFERRING VET

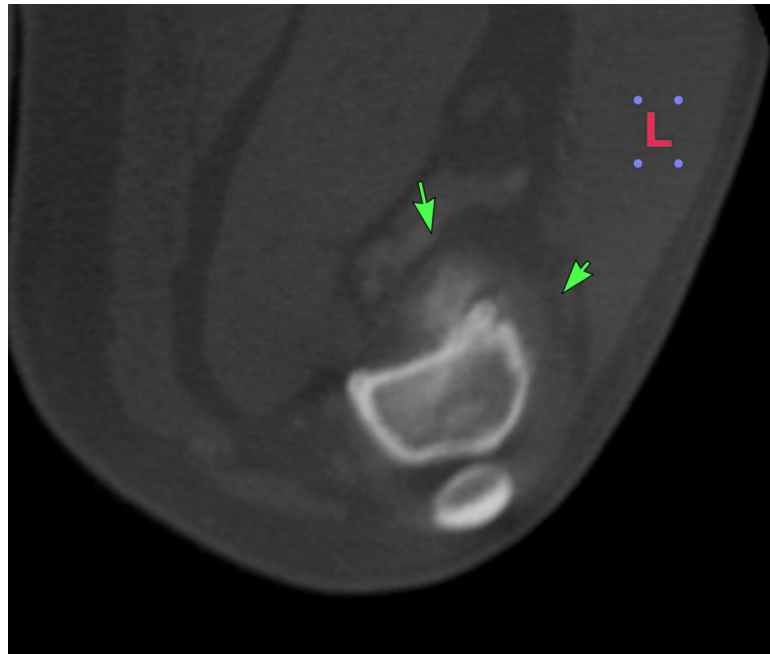
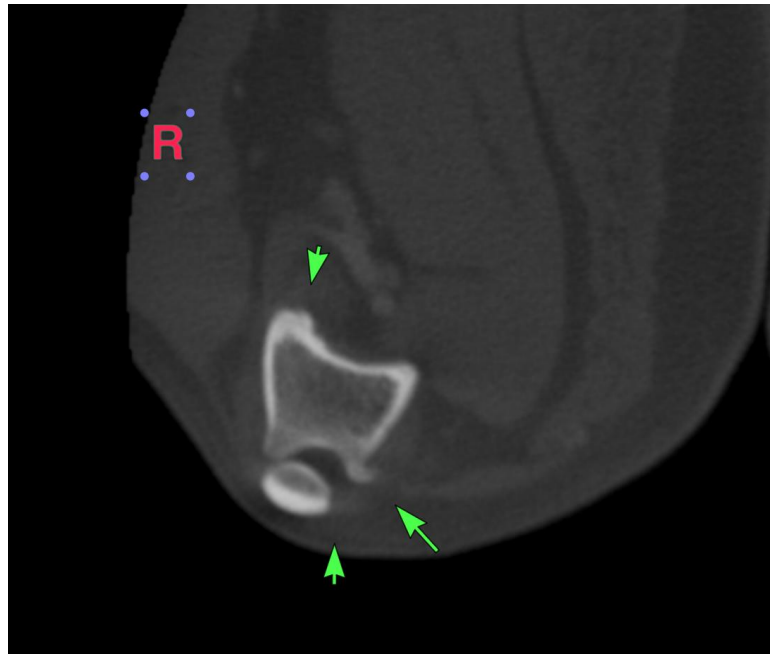
Brandan Costas

## INVOICE

74118

## DATE

3-10-26





## PATIENT

Stitch Avison

## SPECIES

Canine

## BREED

French Bulldog

## SEX

F

## AGE

9

## WEIGHT

13

## INTERPRETED BY

Sebastian Jawinski,  
German Board  
Certified Vet Specialist  
in Diagnostic Imaging

## IMAGING PERFORMED BY

Brandan Costas

## HOSPITAL NAME

Animal Trust - Bolton

## REFERRING VET

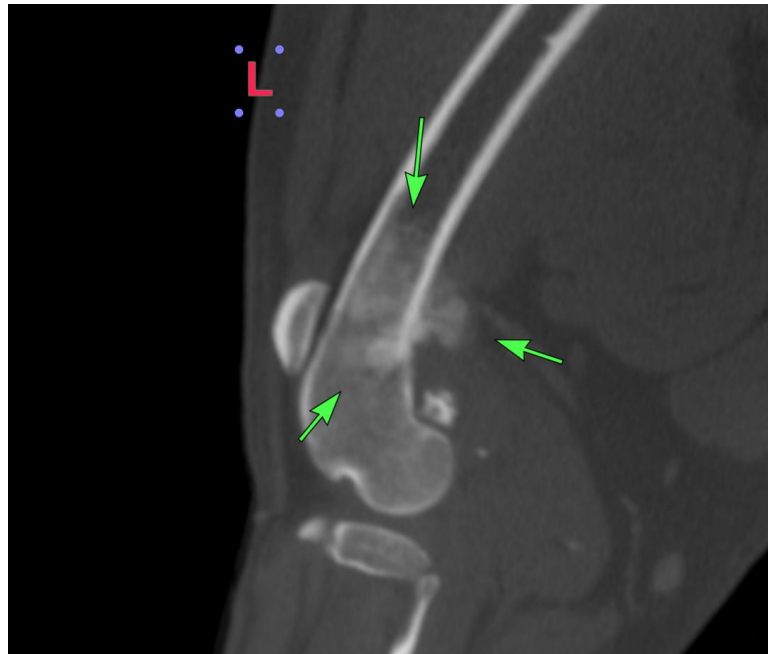
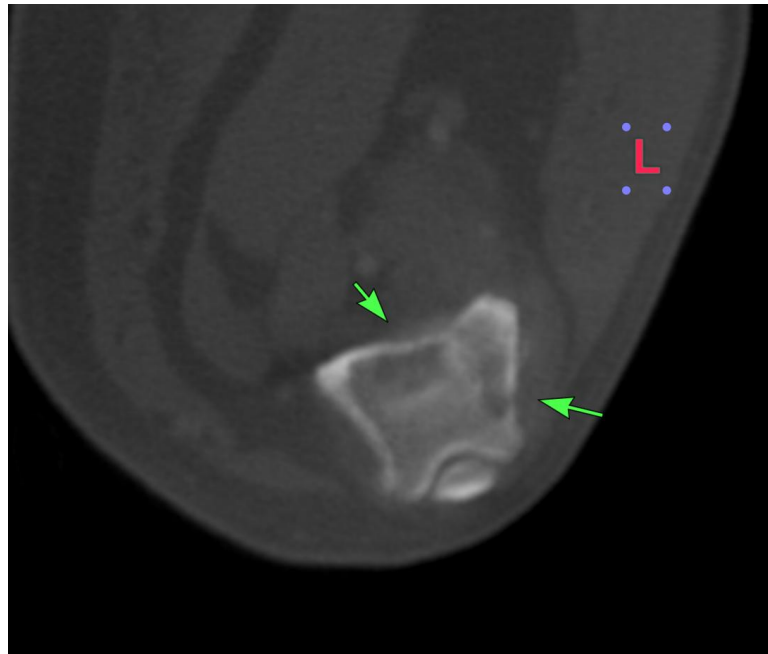
Brandan Costas

## INVOICE

74118

## DATE

3-10-26





## PATIENT

Stitch Avison

## SPECIES

Canine

## BREED

French Bulldog

## SEX

F

## AGE

9

## WEIGHT

13

## INTERPRETED BY

Sebastian Jawinski,  
German Board  
Certified Vet Specialist  
in Diagnostic Imaging

## IMAGING PERFORMED BY

Brandan Costas

## HOSPITAL NAME

Animal Trust - Bolton

## REFERRING VET

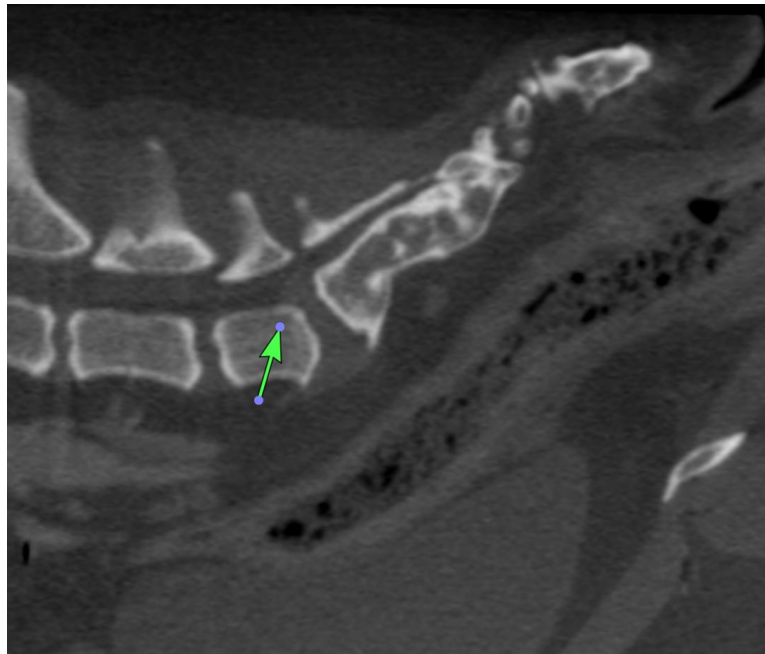
Brandan Costas

## INVOICE

74118

## DATE

3-10-26



The information and recommendations provided are based on the images presented by the referring veterinarian/sonographer. No evaluation can be communicated regarding pathology that was not visible in the image/video clips provided.

Thank you for this referral. If the clinical or image interpretation does not parallel your findings or if I can be of any further assistance, please contact me.

**Sebastian Jawinski, German Board Certified Vet Specialist in Diagnostic Imaging**  
[info@sonopath.com](mailto:info@sonopath.com)