



**PATIENT**

Oreo Kodl

**PRESENTING CLINICAL SIGNS**

Carpal Laxity

**SPECIES**

Canine

**COMPUTED TOMOGRAPHIC FINDINGS**

**Right Carpus**

There is ventral luxation of the carpal joint recognized with the distal radius only partially articulating with the radial carpal bone. Overt evidence of a fracture is not present. The metacarpal structures and right paw appear regular. Signs of an osteolytic process are missing.

**BREED**

Toy Poodle

**COMPUTED TOMOGRAPHIC DIAGNOSIS**

**SEX**

Neutered Male

- Ventral luxation at the level of the antebrachiocarpal joint (radius-radial carpal bone)

**INTERPRETATION OF THE FINDINGS & FURTHER RECOMMENDATIONS**

**AGE**

7 Years

CT findings match with the reported carpal laxity. The luxation may be due to former trauma with injury/lesion/rupture of the intracarpal ligaments, synovia/joint capsule and the periarticular entheses. Temporary extra-articular fixation (fixateur), conservative stabilization or arthrodesis could be performed next.

**INTERPRETED BY**

Sebastian Jawinski,  
German Board  
Certified Vet  
Specialist in  
Diagnostic Imaging

**HOSPITAL NAME**

Aloha Pet & Bird  
Hospital

**REFERRING VET**

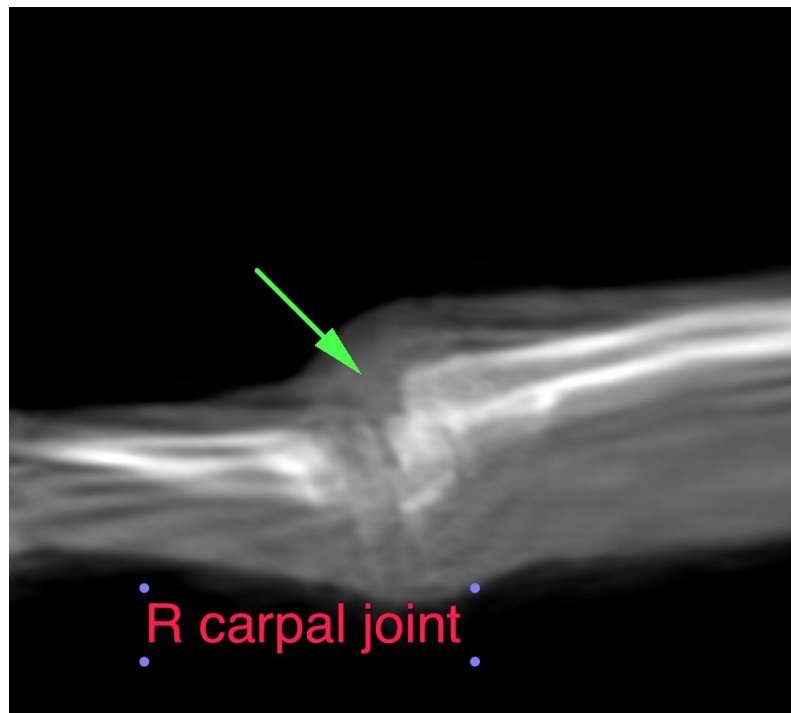
Dr. J. Pepen

**INVOICE**

50165

**DATE**

2-8-22





**PATIENT**

Oreo Kodl

**SPECIES**

Canine

**BREED**

Toy Poodle

**SEX**

Neutered Male

**AGE**

7 Years

**INTERPRETED BY**

Sebastian Jawinski,  
German Board  
Certified Vet  
Specialist in  
Diagnostic Imaging

**HOSPITAL NAME**

Aloha Pet & Bird  
Hospital

**REFERRING VET**

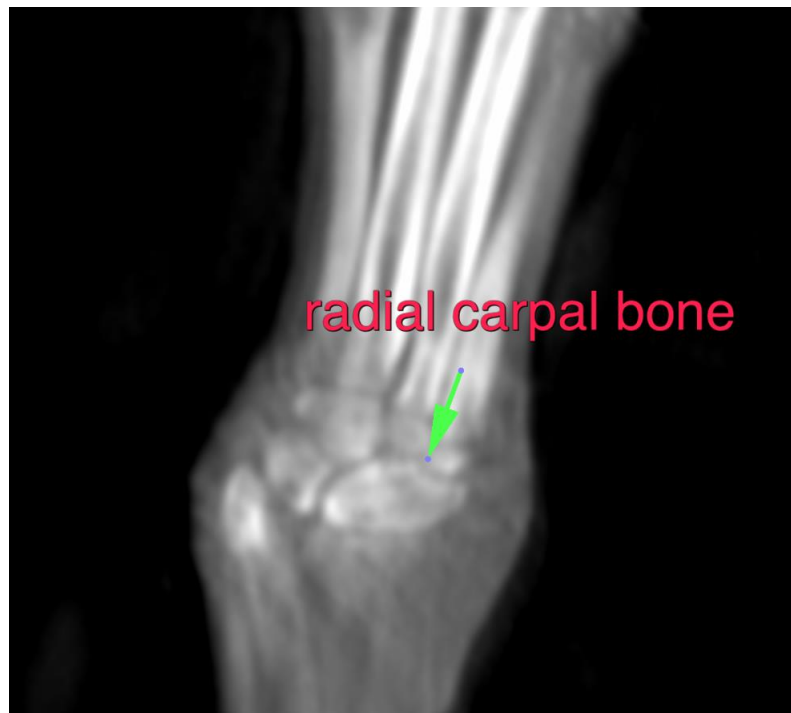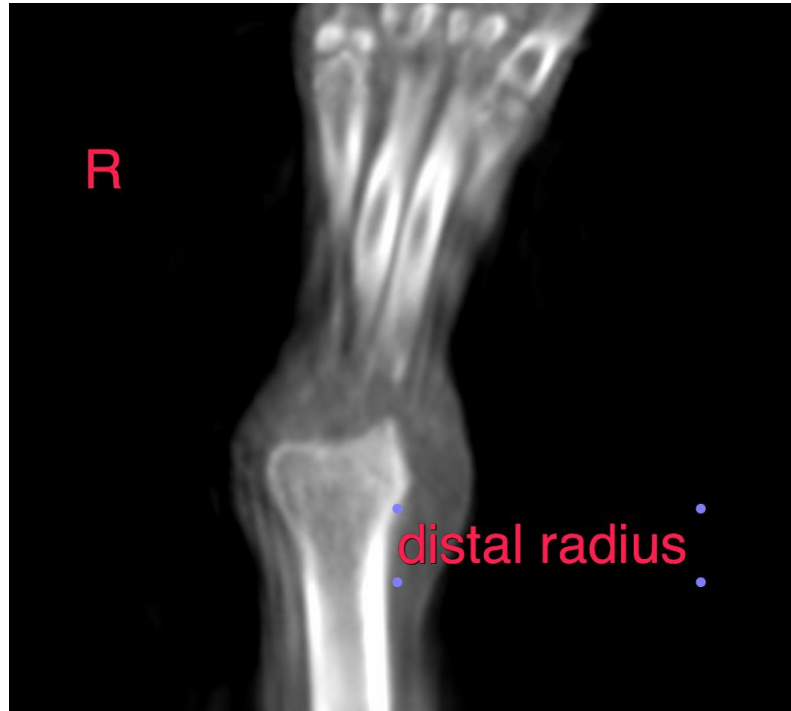Dr. J. Pepen

**INVOICE**

50165

**DATE**

2-8-22





**PATIENT**

Oreo Kodl

The information and recommendations provided are based on the images presented by the referring veterinarian/sonographer. No evaluation can be communicated regarding pathology that was not visible in the image/video clips provided.

**SPECIES**

Canine

Thank you for this referral. If the clinical or image interpretation does not parallel your findings or if I can be of any further assistance, please contact me.

**Sebastian Jawinski, German Board Certified Vet Specialist in Diagnostic Imaging**  
Sebastian.Jawinski@sonopath.com

**BREED**

Toy Poodle

**SEX**

Neutered Male

**AGE**

7 Years

**INTERPRETED BY**

Sebastian Jawinski,  
German Board  
Certified Vet  
Specialist in  
Diagnostic Imaging

**HOSPITAL NAME**

Aloha Pet & Bird  
Hospital

**REFERRING VET**

Dr. J. Pepen

**INVOICE**

50165

**DATE**

2-8-22