



PATIENT

Pablo Bowman

SPECIES

Canine

BREED

French Bulldog

SEX

MN

AGE

5

WEIGHT

18

INTERPRETED BY

Sebastian Jawinski,
German Board
Certified Vet Specialist
in Diagnostic Imaging

IMAGING PERFORMED BY

Henry Xue

HOSPITAL NAME

Belconnen Veterinary
Centre

REFERRING VET

Henry Xue

INVOICE

73650

DATE

2-6-26

PRESENTING CLINICAL SIGNS

- acute onset of the neck pain
- suspect C3-4 disc extrusion
- please comment on thyroid gland

Abnormal PE/Chem/CBC/UA Results: bloods normal no proprioception deficit

COMPUTED TOMOGRAPHY OF THE CERVICAL SPINE

Pre/post contrast studies are provided for review.

COMPUTED TOMOGRAPHIC FINDINGS

The spine presents breed expected malformations in the course of the thoracic and lumbar spine.

There is a calcified disc protrusion noted at the level of C3-4 with dorsal elevation and right pronounced moderate compression of the spinal cord. The protrusion is broad based with maximum compression at the level of the disc. Herniated disc material is not recognized. The intervertebral disc space C4-5 appears narrowed without signs of herniation. The spinal cord is inconspicuous apart from C3-4, shows regular density and can be traced in continuity. A pathologic enhancement is not noted. The paraspinal soft tissues are symmetrical and unremarkable.

COMPUTED TOMOGRAPHIC DIAGNOSIS

- Calcified disc protrusion C3-4 with moderate spinal cord compression
- Breed-expected malformations thoracic/lumbar spine

INTERPRETATION OF THE FINDINGS & FURTHER RECOMMENDATIONS

The CT findings present a moderate compression of the spinal cord due to disc protrusion C3-4. This finding must be correlated with the clinical presentation. Surgical decompression via ventral slot could be discussed. Another compressive lesion of the spinal cord and or the cauda fibers is not recognized. Signs of an active/reactive inflammatory process are not noted. Please note that intramedullary lesions as seen with FCE/ANNPE- or HNPE- lesions are difficult to find or cannot be identified with CT.



PATIENT

Pablo Bowman

SPECIES

Canine

BREED

French Bulldog

SEX

MN

AGE

5

WEIGHT

18

INTERPRETED BY

Sebastian Jawinski,
German Board
Certified Vet Specialist
in Diagnostic Imaging

IMAGING PERFORMED BY

Henry Xue

HOSPITAL NAME

Belconnen Veterinary
Centre

REFERRING VET

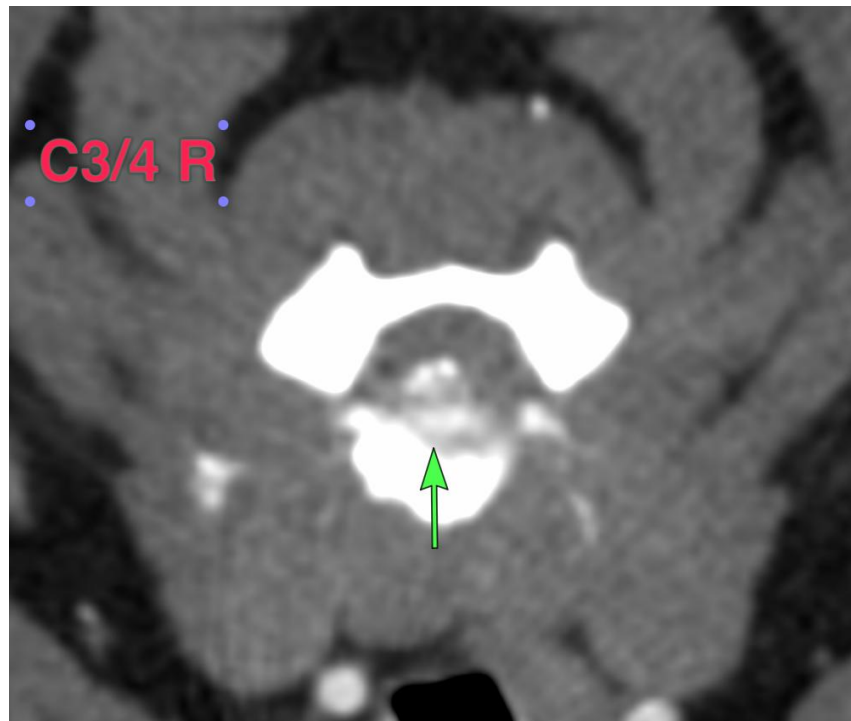
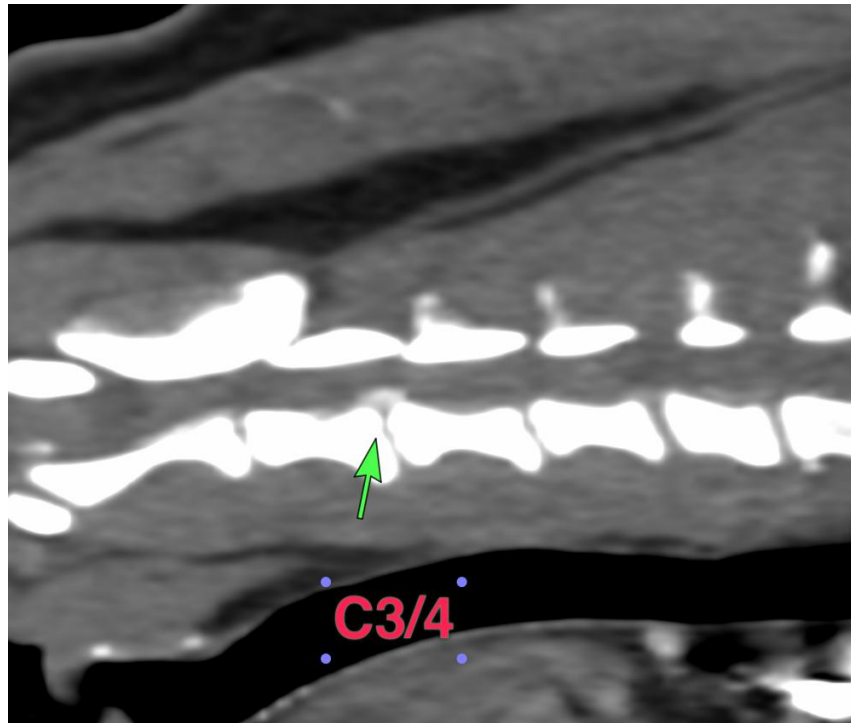
Henry Xue

INVOICE

73650

DATE

2-6-26





PATIENT

Pablo Bowman

SPECIES

Canine

BREED

French Bulldog

SEX

MN

AGE

5

WEIGHT

18

INTERPRETED BY

Sebastian Jawinski,
German Board
Certified Vet Specialist
in Diagnostic Imaging

IMAGING PERFORMED BY

Henry Xue

HOSPITAL NAME

Belconnen Veterinary
Centre

REFERRING VET

Henry Xue

INVOICE

73650

DATE

2-6-26

The information and recommendations provided are based on the images presented by the referring veterinarian/sonographer. No evaluation can be communicated regarding pathology that was not visible in the image/video clips provided.

Thank you for this referral. If the clinical or image interpretation does not parallel your findings or if I can be of any further assistance, please contact me.

Sebastian Jawinski, German Board Certified Vet Specialist in Diagnostic Imaging
info@sonopath.com