

**PATIENT**

Ralphie Keller

**PRESENTING CLINICAL SIGNS**

severe tartar, abscessing

**SPECIES**

Canine

**COMPUTED TOMOGRAPHIC FINDINGS****Head**

The frontal sinuses and the orbital contents are laterally symmetrical without evidence of a retrobulbar lesion and/or an oro-nasal fistula. Nasal cavities bilaterally show swelling of the mucous membranes especially of the ventral nasal section and the nasal exits. Conches and septum are intact without relevant lysis/atrophy. There is generalized horizontal loss of alveolar bone recognized including almost all maxillary and mandibular teeth. Mild erosions of dentin are noted throughout. At the level of 203 mild vertical bone lysis is detected. 308 is missing.

**BREED**

Vizsla

**SEX**

MC

The soft tissues of the head are inconspicuous as far as can be assessed.

**AGE**

11 Years

**COMPUTED TOMOGRAPHIC DIAGNOSIS**

- Signs of a mild root abscess/infection 203
- Generalized horizontal loss of alveolar bone with mild degenerative changes of multiple teeth
- Mild, bilateral and unspecific signs of rhinitis

**INTERPRETED BY**

Sebastian Jawinski,  
German Board  
Certified Vet  
Specialist in  
Diagnostic Imaging

**INTERPRETATION OF THE FINDINGS & FURTHER RECOMMENDATIONS**

CT finding must be correlated with the clinical presentation. Changes are consistent with chronic/degenerative disease as commonly seen with chronic infection/periodontal disease. Signs of an oro-nasal fistula/subcutaneous fistula/abscess formation or relevant osteolysis are not noted.

**HOSPITAL NAME**

Cranberry Holistic  
Pet Care

**REFERRING VET**

Cynthia Maro

**INVOICE**

50275

**DATE**

2-14-22



**PATIENT**

Ralphie Keller

**SPECIES**

Canine

**BREED**

Vizsla

**SEX**

MC

**AGE**

11 Years

**INTERPRETED BY**

Sebastian Jawinski,  
German Board  
Certified Vet  
Specialist in  
Diagnostic Imaging

**HOSPITAL NAME**

Cranberry Holistic  
Pet Care

**REFERRING VET**

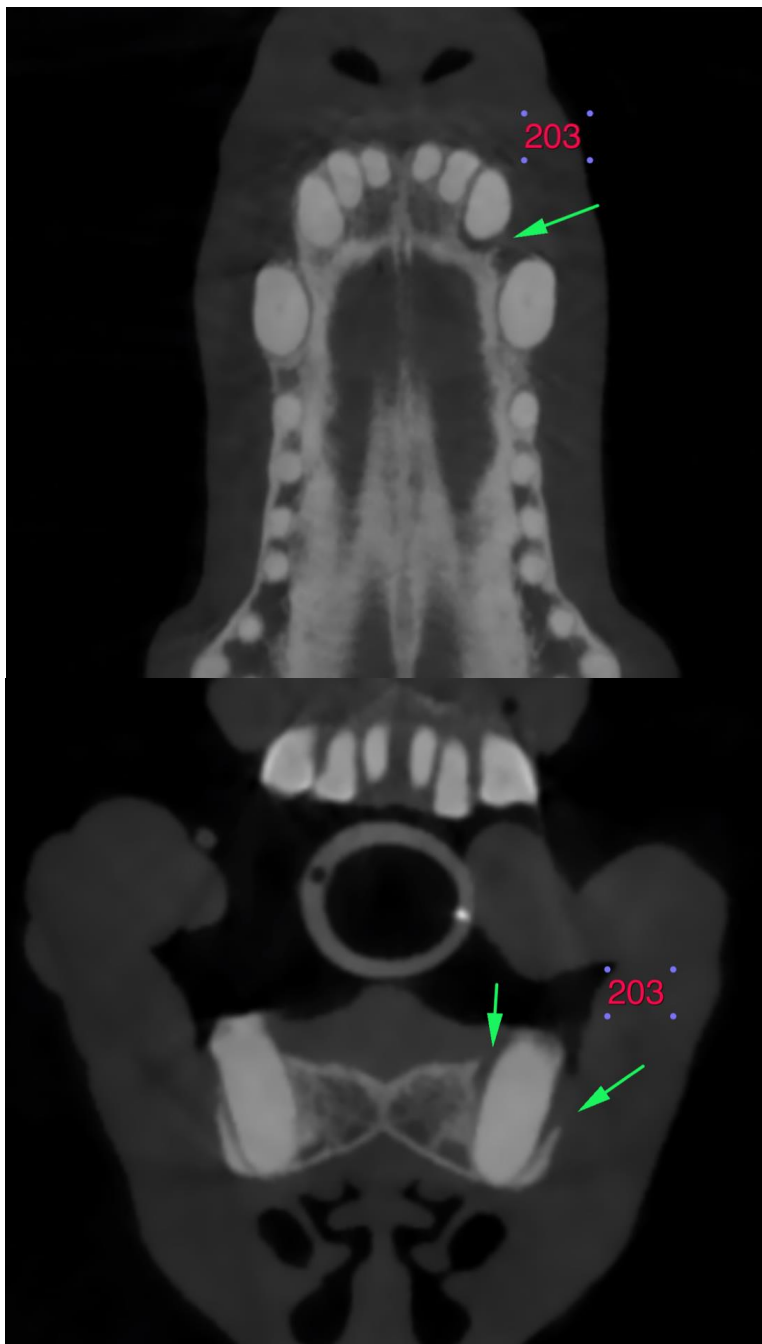
Cynthia Maro

**INVOICE**

50275

**DATE**

2-14-22





**PATIENT**

Ralphie Keller

**SPECIES**

Canine

**BREED**

Vizsla

**SEX**

MC

**AGE**

11 Years

**INTERPRETED BY**

Sebastian Jawinski,  
German Board  
Certified Vet  
Specialist in  
Diagnostic Imaging

**HOSPITAL NAME**

Cranberry Holistic  
Pet Care

**REFERRING VET**

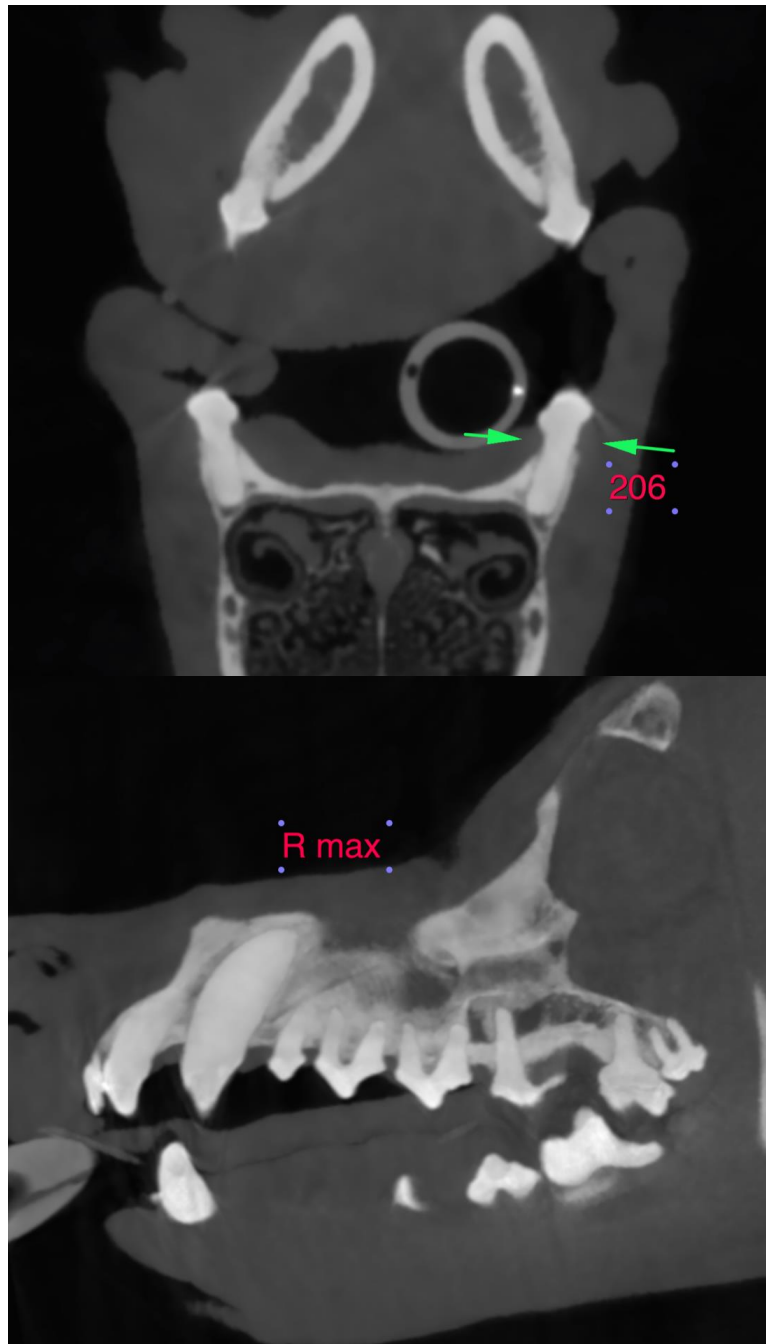
Cynthia Maro

**INVOICE**

50275

**DATE**

2-14-22





**PATIENT**

Ralphie Keller

**SPECIES**

Canine

**BREED**

Vizsla

**SEX**

MC

**AGE**

11 Years

**INTERPRETED BY**

Sebastian Jawinski,  
German Board  
Certified Vet  
Specialist in  
Diagnostic Imaging

**HOSPITAL NAME**

Cranberry Holistic  
Pet Care

**REFERRING VET**

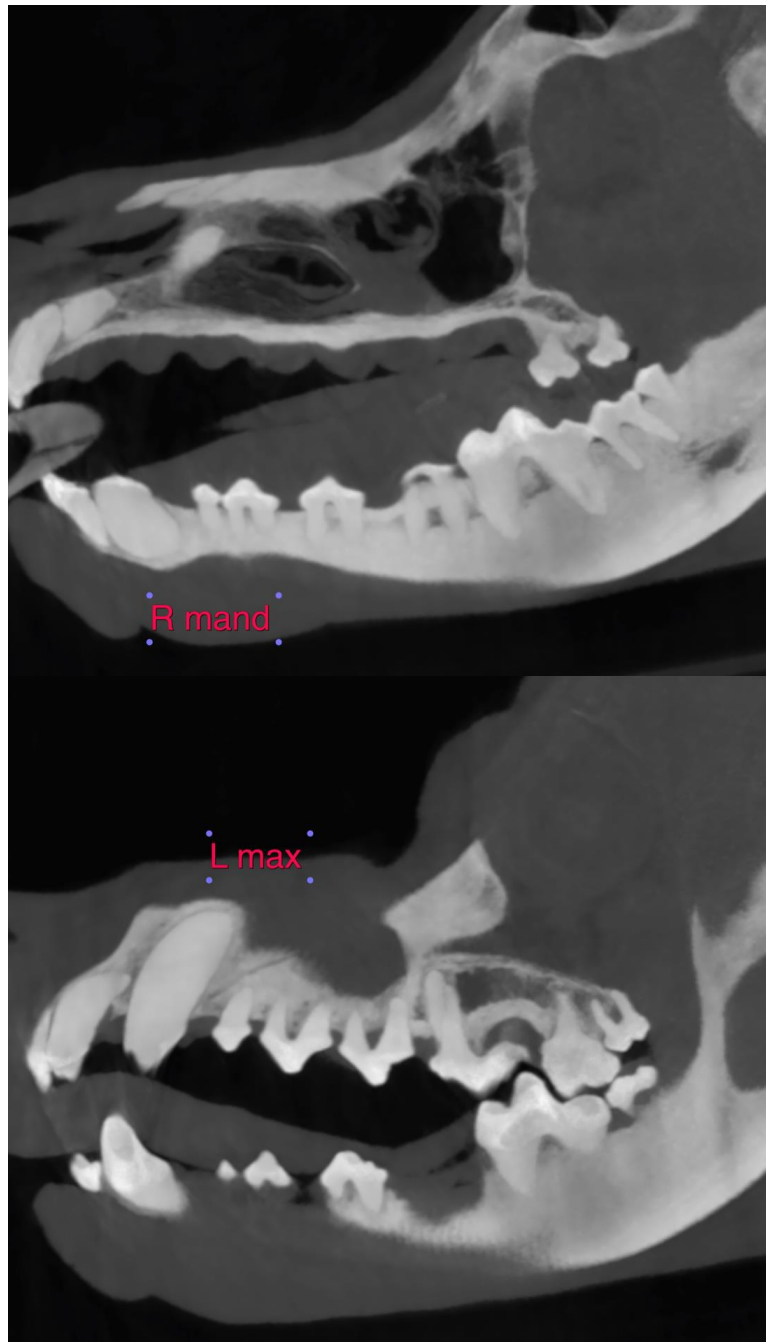Cynthia Maro

**INVOICE**

50275

**DATE**

2-14-22





**PATIENT**

Ralphie Keller

**SPECIES**

Canine

**BREED**

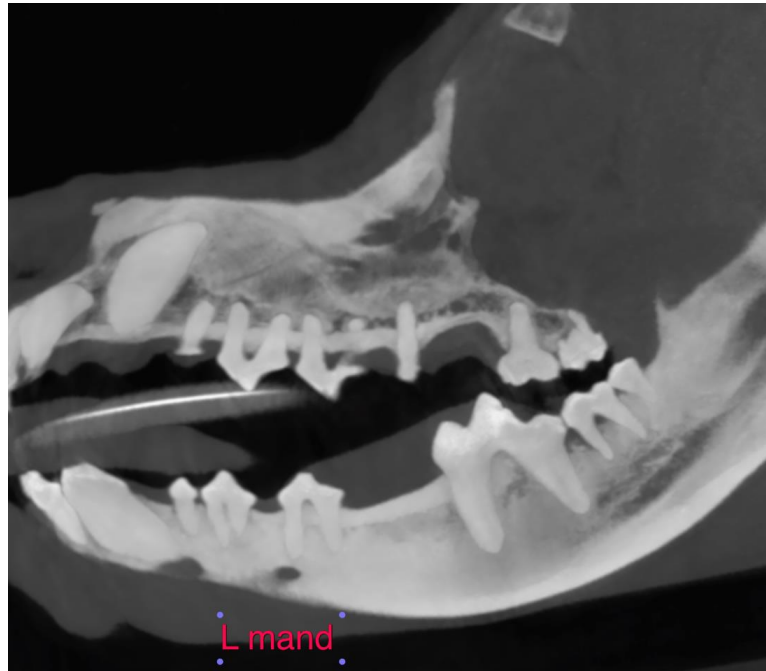Vizsla

**SEX**

MC

**AGE**

11 Years



**INTERPRETED BY**

Sebastian Jawinski,  
German Board  
Certified Vet  
Specialist in  
Diagnostic Imaging

The information and recommendations provided are based on the images presented by the referring veterinarian/sonographer. No evaluation can be communicated regarding pathology that was not visible in the image/video clips provided.

Thank you for this referral. If the clinical or image interpretation does not parallel your findings or if I can be of any further assistance, please contact me.

**HOSPITAL NAME**

Cranberry Holistic  
Pet Care

**Sebastian Jawinski, German Board Certified Vet Specialist in Diagnostic Imaging**  
Sebastian.Jawinski@sonopath.com

**REFERRING VET**

Cynthia Maro

**INVOICE**

50275

**DATE**

2-14-22