

**PATIENT**

Marvin Sheperd

PRESENTING CLINICAL SIGNS

Oral mass of rostral mandible. Has been present for about 2 years. Significant growth since originally noted.

SPECIES

Canine

COMPUTED TOMOGRAPHY OF THE HEAD

Pre/post contrast studies provided for review.

BREED

Blue Heeler

COMPUTED TOMOGRAPHIC FINDINGS

The rostral aspect of the mandible presents a lytic and expansile lesion with deviation of the incisor teeth and crossing of the midline including the right and left mandible. The tooth roots partially show a halo-like periapical lysis. The osteolysis appears irregular with spicula-like periosteal reactions.

SEX

Male Neutered

Frontal sinuses and the orbital contents are laterally symmetrical without evidence of a retrobulbar lesion. Nasal cavities are ventilated regularly. Conches look normal as well as the maxillary/mandibular teeth.

AGE

10 Years

Post contrast images show no pathological enhancement. Soft tissues of the head and neck are symmetrical and of homogeneous density, especially the medial retropharyngeal lymph nodes.

INTERPRETED BY

Sebastian Jawinski,
German Board
Certified Vet
Specialist in
Diagnostic Imaging

COMPUTED TOMOGRAPHIC DIAGNOSIS

- Aggressive, expansile bone lesion rostral mandible with deviation of the incisor teeth

INTERPRETATION OF THE FINDINGS & FURTHER RECOMMENDATIONS

CT findings show an aggressive bone lesion of the rostral mandible which is commonly seen with malignant neoplasia. Possible differential diagnoses include but are not limited to squamous cell carcinoma and malignant melanoma. Biopsy is needed for further evaluation. Severe and chronic inflammatory issues such as osteomyelitis due to bacterial infection are possible secondary findings. I would rule out inflammatory causes as a primary finding. Biopsy and/or resection could be performed next.

HOSPITAL NAME

State Avenue Vet
Clinic

REFERRING VET

Dr. Jessica Evoniuk

INVOICE

50281

DATE

2-14-22



PATIENT

Marvin Sheperd

SPECIES

Canine

BREED

Blue Heeler

SEX

Male Neutered

AGE

10 Years

INTERPRETED BY

Sebastian Jawinski,
German Board
Certified Vet
Specialist in
Diagnostic Imaging

HOSPITAL NAME

State Avenue Vet
Clinic

REFERRING VET

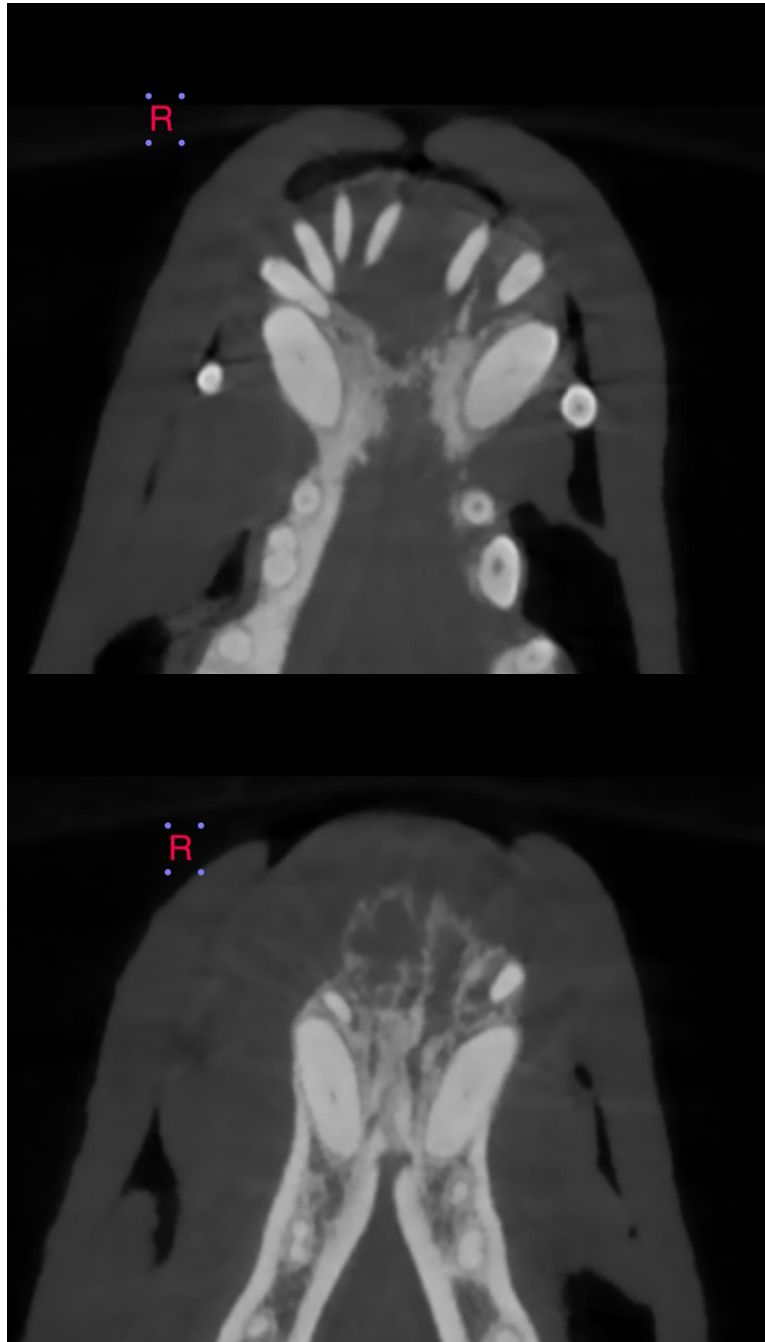
Dr. Jessica Evoniuk

INVOICE

50281

DATE

2-14-22





PATIENT

Marvin Sheperd

SPECIES

Canine

BREED

Blue Heeler

SEX

Male Neutered

AGE

10 Years

INTERPRETED BY

Sebastian Jawinski,
German Board
Certified Vet
Specialist in
Diagnostic Imaging

HOSPITAL NAME

State Avenue Vet
Clinic

REFERRING VET

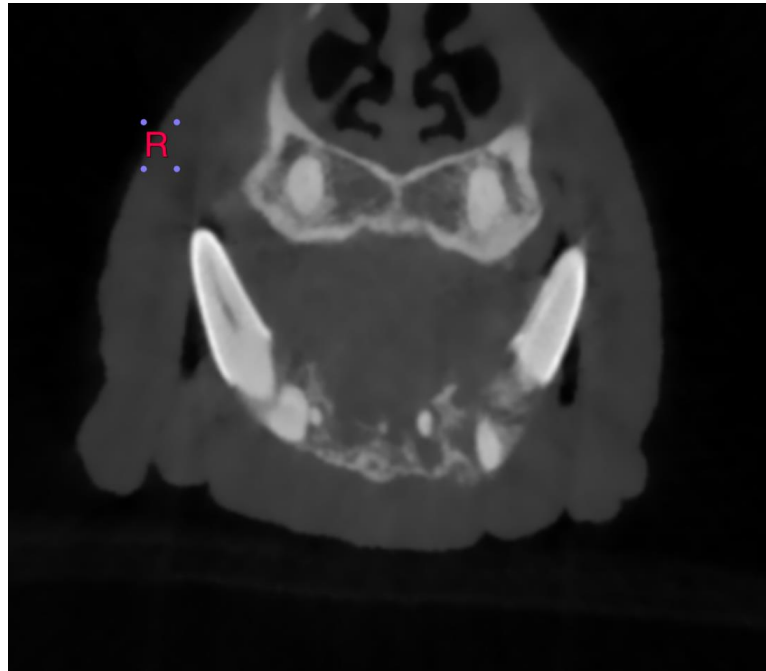
Dr. Jessica Evoniuk

INVOICE

50281

DATE

2-14-22



The information and recommendations provided are based on the images presented by the referring veterinarian/sonographer. No evaluation can be communicated regarding pathology that was not visible in the image/video clips provided.

Thank you for this referral. If the clinical or image interpretation does not parallel your findings or if I can be of any further assistance, please contact me.

Sebastian Jawinski, German Board Certified Vet Specialist in Diagnostic Imaging
Sebastian.Jawinski@sonopath.com