



## PATIENT

Max Beckett

## SPECIES

Canine

## BREED

Greyhound

## SEX

Neutered Male

## AGE

9 Years 8 Months

## WEIGHT

30 kg

## INTERPRETED BY

Sebastian Jawinski,  
German Board  
Certified Vet Specialist  
in Diagnostic Imaging

## IMAGING PERFORMED BY

Ana

## HOSPITAL NAME

Animal Trust- Bolton

## REFERRING VET

Dr. Ana Valega

## INVOICE

13792

## DATE

02/13/26

## PRESENTING CLINICAL SIGNS

- lame on back L leg has this issue since Xmas used metacam on sior got better but 2w after symptoms came back again
- prev vet suspected spinal issue as well
- reaction licking his lips on lumbar spinal palpation (or was yelping a few weeks ago when other vet palpated spine)
- lameness on L back leg 6/10 sensitive to touch toe yelping shaking cannot see any wound bleeding discharge not able to examine properly as yelping

## COMPUTED TOMOGRAPHIC STUDY OF THE THORACIC, LUMBAR SPINE & HINDLIMBS

pre/post contrast

## COMPUTED TOMOGRAPHIC FINDINGS

The presented spine shows a harmonic course with inconspicuous vertebral bodies and subtle degenerations (s. for example Th11/12). The bone density is within normal limits. There are no signs of a lytic or sclerotic process noted. The thoracolumbar and lumbosacral transition are unremarkable. There is no evidence of a fracture or subluxation. The intervertebral discs spaces are of even diameter and inconspicuous. As far as can be assessed a compressive lesion is not recognized. The paravertebral soft tissues are bilaterally symmetrical, especially the course of the femoral and sciatic nerves is inconspicuous. Unilateral atrophy of the paraspinal and/or pelvic musculature is not noted.

The bony structures of the pelvis and the sacroiliac joints are unremarkable. There is no evidence of a lytic process noted. The coxofemoral joints are inconspicuous. There is no relevant formation of osteophytes recognized. The intra- and extra-pelvic soft tissues are in normal limits. The musculature of the thighs is unremarkable.

The right stifle is inconspicuous. The right tarsus presents metallic implants after surgery, which appear without any reactions. The tarsal joint on the right side presents moderate osteoarthritis with osteophytic reactions and new bone formations at all joint levels.

The left stifle shows an irregular and coarse inner texture of the distal femur with indicated cystic and sclerotic lesions. The cortical lines are intact. Relevant joint effusion is not noted. The joint margins are unremarkable. There are subtle osteophytic reactions noted at the insertion of the lateral gastrocnemius muscle bilaterally.

A pathologic enhancement is not recognized. The left tarsal joint is unremarkable.

## COMPUTED TOMOGRAPHIC DIAGNOSIS

- Coarse medullary texture distal left femur
- Subtle and bilateral degenerative findings lateral gastrocnemius muscle insertion
- Moderate osteoarthritis/status after surgery right tarsus
- Subtle degenerations thoracic spine



## PATIENT

Max Beckett

## SPECIES

Canine

## BREED

Greyhound

## SEX

Neutered Male

## AGE

9 Years 8 Months

## WEIGHT

30 kg

## INTERPRETED BY

Sebastian Jawinski,  
German Board  
Certified Vet Specialist  
in Diagnostic Imaging

## IMAGING PERFORMED BY

Ana

## HOSPITAL NAME

Animal Trust- Bolton

## REFERRING VET

Dr. Ana Valega

## INVOICE

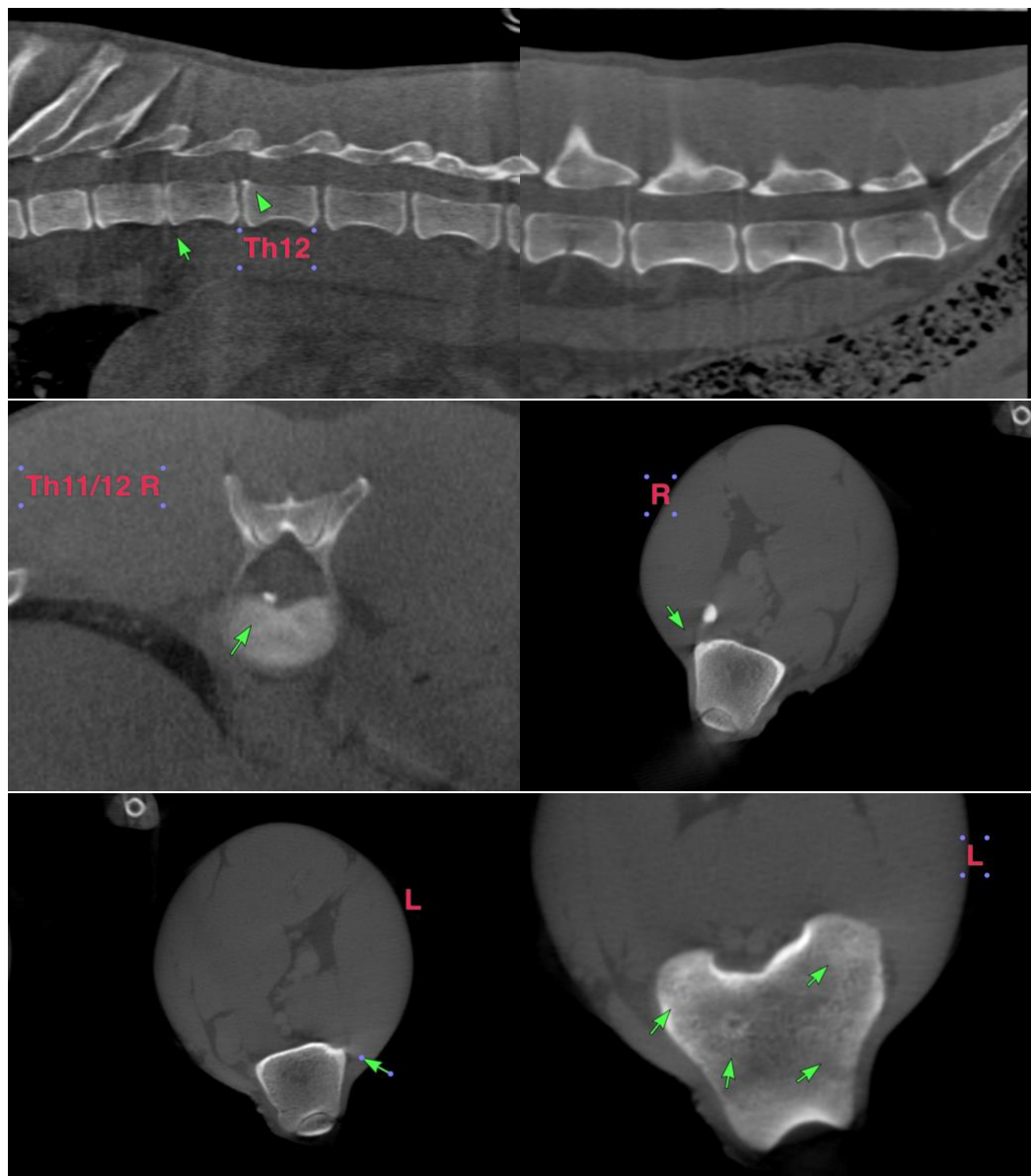
13792

## DATE

02/13/26

## INTERPRETATION OF THE FINDINGS & FURTHER RECOMMENDATIONS

The changes of the medullary texture in the left distal femur are an asymmetric finding and would match with the reported patient's history. Differentials include post-traumatic changes after bone bruise and microfractures, as well as inflammatory changes as seen with osteomyelitis and osseous infection. Initial neoplasia cannot be fully excluded. For further differentiation, a follow-up radiograph or CT could be performed after treatment. Bone biopsy and histopathology would be an alternative. The subtle degenerations of the thoracic spine likely do not have clinical relevance, as well as the bilateral degenerations of the gastrocnemius insertion and the moderate osteoarthritis of the right tarsus.





## PATIENT

Max Beckett

## SPECIES

Canine

## BREED

Greyhound

## SEX

Neutered Male

## AGE

9 Years 8 Months

## WEIGHT

30 kg

## INTERPRETED BY

Sebastian Jawinski,  
German Board  
Certified Vet Specialist  
in Diagnostic Imaging

## IMAGING PERFORMED BY

Ana

## HOSPITAL NAME

Animal Trust- Bolton

## REFERRING VET

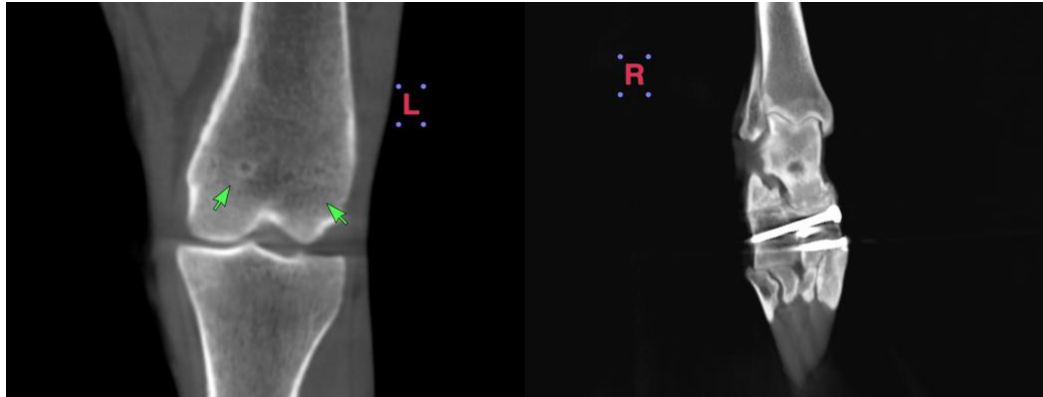
Dr. Ana Valega

## INVOICE

13792

## DATE

02/13/26



The information and recommendations provided are based on the images presented by the referring veterinarian/sonographer. No evaluation can be communicated regarding pathology that was not visible in the image/video clips provided.

Thank you for this referral. If the clinical or image interpretation does not parallel your findings or if I can be of any further assistance, please contact me.

Sebastian Jawinski, German Board Certified Vet Specialist in Diagnostic Imaging  
[info@sonopath.com](mailto:info@sonopath.com)